This is a digital copy of a book that was preserved for generations on library shelves before it was carefully scanned by Google as part of a project to make the world's books discoverable online.

It has survived long enough for the copyright to expire and the book to enter the public domain. A public domain book is one that was never subject to copyright or whose legal copyright term has expired. Whether a book is in the public domain may vary country to country. Public domain books are our gateways to the past, representing a wealth of history, culture and knowledge that's often difficult to discover.

Marks, notations and other marginalia present in the original volume will appear in this file - a reminder of this book's long journey from the publisher to a library and finally to you.

Usage guidelines

Google is proud to partner with libraries to digitize public domain materials and make them widely accessible. Public domain books belong to the public and we are merely their custodians. Nevertheless, this work is expensive, so in order to keep providing this resource, we have taken steps to prevent abuse by commercial parties, including placing technical restrictions on automated querying.

We also ask that you:

+ *Make non-commercial use of the files* We designed Google Book Search for use by individuals, and we request that you use these files for personal, non-commercial purposes.
+ *Refrain from automated querying* Do not send automated queries of any sort to Google's system: If you are conducting research on machine translation, optical character recognition or other areas where access to a large amount of text is helpful, please contact us. We encourage the use of public domain materials for these purposes and may be able to help.
+ *Maintain attribution* The Google "watermark" you see on each file is essential for informing people about this project and helping them find additional materials through Google Book Search. Please do not remove it.
+ *Keep it legal* Whatever your use, remember that you are responsible for ensuring that what you are doing is legal. Do not assume that just because we believe a book is in the public domain for users in the United States, that the work is also in the public domain for users in other countries. Whether a book is still in copyright varies from country to country, and we can't offer guidance on whether any specific use of any specific book is allowed. Please do not assume that a book's appearance in Google Book Search means it can be used in any manner anywhere in the world. Copyright infringement liability can be quite severe.

About Google Book Search

Google's mission is to organize the world's information and to make it universally accessible and useful. Google Book Search helps readers discover the world's books while helping authors and publishers reach new audiences. You can search through the full text of this book on the web at `http://books.google.com/`

OMPENDS

ES OF THE SKIN

SCHAMBERG

MORRIS' ANATOMY.

THIRD EDITION.

848 Illustrations, of which 269 are Colored.

Human Anatomy. A Complete Systematic Treatise by Various Authors, Including Special Sections on Surgical and Topographical Anatomy, the Skin, and Vestigial and Abnormal Structures. Edited by HENRY MORRIS, M.A. and M.B. (Lond.), F.R.C.S., Senior Surgeon to Middlesex Hospital; Examiner in Surgery, University of London; Member of the Council, and Chairman of the Court of Examiners, Royal College of Surgeons, etc. Third Edition, Rewritten in Parts and thoroughly revised throughout. With 848 Illustrations, the greater part of which are Original, 269 being printed in Colors. Royal Octavo. 1300 pages. Cloth, *net*, $6.00; Leather, *net*, $7.00

☞ In making this new edition the editors and publishers have used every endeavor to enhance its value. The text has been thoroughly revised and in many parts rewritten; the editor has devoted himself to the task of making it a harmonious whole; many new illustrations have replaced those used in the first

THUMB INDEX IN EACH COPY.

LANE MEDICAL LIBRARY

SEAL OF THE LELAND STANFORD JUNIOR UNIVERSITY
SEMPER VIRENS
1885

Library of
Dr. U. C. Billingsley.

and Colored Illustrations, will be sent free to any address.

8-24-03

Tyson's Practice of Medicine

THIRD EDITION.

124 Illustrations, Several of which are in Colors.

The Practice of Medicine. A Text-Book for Physicians and Students, with Special Reference to Diagnosis and Treatment. By JAMES TYSON, M.D., Professor of Medicine in the University of Pennsylvania; Physician to the University and to the Philadelphia Hospitals; Fellow of the College of Physicians of Philadelphia; Member of the Association of American Physicians, etc. Third Edition. Octavo. 1240 pages. 124 Illustrations.

Cloth, *net*, $5.50; Sheep, *net*, $6.50

☞ This edition has been entirely reset from new type. The author has revised it carefully and thoroughly, and added much new material.

From The Therapeutic Gazette.

"From the first to the last of this large volume of nearly 1200 pages we find much to commend, almost nothing to criticise, and certainly nothing to contradict.

"It is in the writing and preparation of a work of this character that Dr. Tyson stands pre-eminent. Those of the profession—and there are many at this time—who have been fortunate enough to have been his pupils during their medical student days, will remember that he brought to his lectures and to his writings an amount of industry and care which many other teachers failed to bring; and those who know him best as an author and teacher have expected that his book on the Practice of Medicine, when it appeared, would be a credit to himself and would increase his reputation as a medical author. This belief has proved correct. . . . We look forward to using this volume upon the 'Practice of Medicine' more than any of the others which grace our library shelves, and they are many and all of them good."

From The North American Practitioner, Chicago.

"The individuality of the writer is clearly manifest in the clear and practical manner in which diseases are described and their treatment expressed. . . . The succeeding sections upon Diseases of the Digestive, Respiratory, Circulatory, and Nervous Systems, together with those of the Blood, Urinary Organs, Constitutional Diseases, etc., are so full as to well serve, in each instance, the needs of the specialist, while their grouping in one complete volume renders it a valuable text-book for students, and the one above any other now at command most suited to the present needs of the active practitioner. **It is the best representative of the practical application of modern research and discovery to the treatment of diseases now at the command of the medical profession.**"

☞ BASED ON RECENT MEDICAL LITERATURE.

Gould's Medical Dictionaries.

The Standard Medical Reference Books.

150,000 HAVE BEEN SOLD.

BY GEORGE M. GOULD, A.M., M.D.,
Editor of *American Medicine.*

THE ILLUSTRATED DICTIONARY OF MEDICINE, BIOLOGY, AND ALLIED SCIENCES. INCLUDING THE PRONUNCIATION, ACCENTUATION, DERIVATION, AND DEFINITION OF THE TERMS USED IN MEDICINE AND THOSE SCIENCES COLLATERAL TO IT: BIOLOGY (ZOOLOGY AND BOTANY), CHEMISTRY, DENTISTRY, PHARMACOLOGY, MICROSCOPY, ETC. With many Useful Tables and numerous Fine Illustrations. Large Square Octavo. 1633 pages. Fifth Edition now ready. Full Sheep, or Half Dark-Green Leather, *net*, $10.00; With Thumb Index, *net*, $11.00; Half Russia, Thumb Index, *net*, $12.00

THE STUDENT'S MEDICAL DICTIONARY. INCLUDING ALL THE WORDS AND PHRASES GENERALLY USED IN MEDICINE, WITH THEIR PROPER PRONUNCIATION AND DEFINITIONS, BASED ON RECENT MEDICAL LITERATURE. With Tables of the Bacilli, Micrococci, Leukomains, Ptomains, etc., of the Arteries, Muscles, Nerves, Ganglia, and Plexuses; Mineral Springs of the U. S., etc. **Eleventh Edition, Illustrated.** Revised, Enlarged by over 150 pages. Small Square Octavo. Half Dark Leather, *net*, $2.50; with Thumb Index, *net*, $3.00

The illustrations in this book, of which there are about 300, are extremely practical. Those of the Bones, Muscles, Nerves, etc., when taken together with the Anatomical Tables which they illustrate, will be found particularly useful for reference and memorizing. There are 41 cuts of Bones, 34 of Muscles, 21 of Nerves, 18 of Joints, 3 of the Heart, 10 of Ligaments, 12 of Pelves, a plate of the Skeleton, a plate of Veins, a plate of Arteries, 31 cuts of Bandages, 20 of Urinary Sediments, 10 of Postures, 6 of Motor Points, 6 of Surgical Knots, 8 of Hernia, 21 of Sutures, 2 of the Tongue, 4 of the Brain, and many others. Altogether the student will find "Gould's Student's Dictionary" a most valuable book, not only as a dictionary but also as an atlas illustrative of many subjects which need pictures to thoroughly explain their details.

THE POCKET PRONOUNCING MEDICAL LEXICON. 30,000 words pronounced and defined. Containing all the Words, their Definition and Pronunciation that the Student generally comes in contact with; also elaborate Tables of the Arteries, Muscles, Nerves, Bacilli, etc., etc.; a Dose List in both English and Metric Systems, etc., arranged in a most convenient form for reference and memorizing. Fourth Edition, 837 pages. 64mo.

Full Limp Leather, Gilt Edges, *net*, $1.00; Thumb Index, *net*, $1.25

DISEASES OF THE SKIN

SCHAMBERG

From The Southern Clinic.

"We know of no series of books issued by any house that so fully meets our approval as these ?Quiz-Compends?. They are well arranged, full, and concise, and are really the best line of text-books that could be found for either student or practitioner."

BLAKISTON'S ? QUIZ-COMPENDS ?

The Best Series of Manuals for the Use of Students

Price of each, Cloth, $0.80 net. Interleaved, for taking Notes, $1.00 net.

☞ These Compends are based on the most popular text-books and the lectures of prominent professors, and are kept constantly revised, so that they may thoroughly represent the present state of the subjects upon which they treat.

☞ The authors have had large experience as Quiz-Masters and attaches of colleges, and are well acquainted with the wants of students.

☞ They are arranged in the most approved form, thorough and concise, containing over 600 fine illustrations, inserted wherever they could be used to advantage.

☞ Can be used by students of any college.

☞ They contain information nowhere else collected in such a condensed, practical shape.

Illustrated Circular Free.

No. 1. POTTER'S ANATOMY. Seventh Revised and Enlarged Edition. Including Visceral Anatomy. Can be used with either Morris' or Gray's Anatomy. 117 Illustrations and 16 Lithographic Plates of Nerves and Arteries, with Explanatory Tables, etc.

No. 2. HUGHES. PRACTICE OF MEDICINE. Part I. Sixth Edition, Revised, Enlarged, and Improved.

No. 3. HUGHES. PRACTICE OF MEDICINE. Part II. Sixth Edition. Revised, Enlarged, and Improved. These two books furnish a complete set of notes on the Practice of Medicine, including Nervous and Mental Diseases.

No. 4. BRUBAKER. PHYSIOLOGY. Eleventh Edition, with new Illustrations and a Table of Physiological Constants. Enlarged and Revised.

No. 5. LANDIS. OBSTETRICS. Sixth Edition. Revised and Edited by Wm. H. Wells, M.D., Instructor Jefferson Medical College, Philadelphia. 47 Illustrations.

No. 6. POTTER. MATERIA MEDICA, THERAPEUTICS, AND PRESCRIPTION WRITING. Sixth Revised Edition.

No. 7. WELLS. GYNÆCOLOGY. Third Edition. With many Illustrations.

No. 8. GOULD and PYLE. DISEASES OF THE EYE AND REFRACTION. Including Treatment and Operations and a Section on Local Therapeutics. With Formulæ and 109 Illustrations, several of which are in colors. Second Edition.

No. 9. HORWITZ'S SURGERY, Minor Surgery, and Bandaging. Fifth Edition. Enlarged and Improved. With 98 Formulæ and 167 Illustrations.

No. 10. LEFFMANN. CHEMISTRY. Inorganic and Organic. Fourth Edition. Including Urinalysis, Animal Chemistry, Chemistry of Milk, Blood, Tissues, the Secretions, etc.

No. 11. STEWART. PHARMACY. Fifth Edition. Based upon Prof. Remington's Text-Book of Pharmacy.

No. 12. BALLOU. VETERINARY ANATOMY AND PHYSIOLOGY. With 29 graphic Illustrations.

No. 13. WARREN. DENTAL PATHOLOGY AND DENTAL MEDICINE. Third Edition. Illustrated. Containing all the most noteworthy points of interest to the Dental Student, and a Section on Emergencies.

No. 14. HATFIELD. DISEASES OF CHILDREN. Colored Plate. Third Edition. Revised and Enlarged.

No. 15. THAYER. GENERAL PATHOLOGY. With 78 Illustrations.

No. 16. SCHAMBERG. DISEASES OF THE SKIN. Third Edition. Illustrated.

No. 17. CUSHING. HISTOLOGY. With many Illustrations.

No. 18. THAYER. SPECIAL PATHOLOGY. With 34 Illustrations.

No. 19. KYLE. NOSE, THROAT AND EAR. Illustrated.

Price, each, $0.80 net. Interleaved, for taking Notes, $1.00 net.

P. BLAKISTON'S SON & COMPANY, Publishers

PHILADELPHIA

? QUIZ-COMPENDS ? No. 16

A COMPEND

OF

DISEASES OF THE SKIN

BY

JAY F. SCHAMBERG, A.B., M.D.

PROFESSOR OF DISEASES OF THE SKIN, PHILADELPHIA POLYCLINIC AND COLLEGE FOR GRADUATES IN MEDICINE; FELLOW OF THE COLLEGE OF PHYSICIANS OF PHILADELPHIA

THIRD EDITION, REVISED AND ENLARGED

With 106 Illustrations

LANE LIBRARY

PHILADELPHIA

P. BLAKISTON'S SON & CO.

1012 WALNUT STREET

1903

14

Histology of skin.
Gen. points in diagnosis.
Hysterical Eruptions.
Primary Efflorescences 20
Secondary " 21
Drugs used in int. treat. + use of each.
Method of application of drugs.
Eczema 44
Impetigo Contagiosa 60
Psoriasis 102
Lichen Ruber Planus 81
" Scrofulosum 94
Pemphigus Neonatorum 70
~~Dyshidrosis~~ (Cheiropompholyx. 73
Seborrhea (Capitis + ~~Face.~~ 275

COPYRIGHT 1903, BY P. BLAKISTON'S SON & CO.

Acne vulgaris 86
" varioliformis 97
" Rosacea 93
Ringworm Head 135
" Body 130
" Beard 139
Herpes Tonsurans et squamosus
Pityriasis Rosea 114
Sycosis Non-parasitica 98
Burns 118
Furunculosis 124
Erysipelas 115
Erythema exsudativum multiforme 29
Erythema nodosum 33

PRESS OF
REPORT PUBLISHING CO.,
LEBANON, PA.

Urticaria 36
Purpura 165
Scabies 153

Pediculi 158
Favus 145
Pityriasis Vesicolor 142
Erythrasma 151
Lupus Vulgaris 230
Scrofuloderma 237
Leprosy 256
Mycosis fungoides 266
Rhinoscleroma 225
Herpes 75
Prurigo 84
Pruritus 280
Alopecia Areata 209
Pemphigus 70
Dermatitis Herpetiformis 67
Ichthyosis 175
Tylosis 171
Verruca 178
Hypertrichosis 188
Clavus 172
Pigment Hypertrophy 170
Chloasma 168
Elephantiasis 192 – 256
Fibroma Molluscum 218

TO

Professor Louis A. Duhring

THIS LITTLE WORK IS DEDICATED, IN GRATEFUL ACKNOWLEDGMENT
OF HIS VALUABLE CONTRIBUTIONS TO DERMATOLOGY
BY ONE WHO AMONG MANY OTHERS HAS
PROFITED BY HIS TEACHINGS.

THE AUTHOR

Scleroderma 203

Keloid 216

Milium 185

Molluscum Contagiosum 180

Angioma { Lymph / Blood { Simple / Cavernous 223

Sarcoma 266

Carcinoma { Rodent Ulcer 261

Alopecia Pityroides 207

Trichorrhexis 215

Albino 196

Vitilego 197

Lupus Erythematosis 226

Poliosis = Vitilego in the hair

Glycogelatin
℞ Gum Acacia 40
Gel. alba 30
Dist Water 100
Heat.

T74
S29
1103

PREFACE TO THIRD EDITION.

The text has been carefully reread and sundry additions and revisions made. The author trusts that the little book will be accorded the continued patronage of students and practitioners.

JAY F. SCHAMBERG.

1636 WALNUT ST., PHILADELPHIA.
May 1st, 1903.

101124

LANE LIBRARY

PREFACE TO THE FIRST EDITION.

The little book herewith presented is designed for the use of practitioners and students, as a rapid reference work and key to the study of dermatology.

The effort has been made to present the subject of skin diseases in a succinct and at the same time lucid and readable form. Especial attention has been paid to the differential diagnosis and treatment of the more important affections.

The author has followed Duhring's classification in the presentation of the subject, although deviations in connection with one or two diseases occur.

The works of Crocker, Duhring, Hyde, Robinson, Brocq, Van Harlingen and others have been freely consulted in the preparation of this little volume.

JAY F. SCHAMBERG.

LAKE LIBRARY

CONTENTS.

PAGE

EMBRYONIC DEVELOPMENT OF THE SKIN 9
Anatomy of the Skin 9
Epidermis 9
Corium 12
Blood-vessels 14
Lymph-vessels 14
Nerves 14
Nerve Corpuscles 14
Muscle 14
Sebaceous Glands 15
Sweat-glands 15
Hair 17
Nail 19
Symptomatology 20
Primary Lesions 20
Secondary Lesions 20
Classification 21, 22, 23, 24, 25
CLASS I. ANEMIAS 26
CLASS II. HYPEREMIAS 26, 27, 28
Erythema Hyperæmicum 27
Erythema Intertrigo 28
CLASS III. INFLAMMATIONS 29
Erythema Exsudativum 29
Erythema Multiforme 29
Erythema Scarlatinoides 32
Erythema Nodosum 33
Erythema Induratum 34
Pellagra 35
Acrodynia 36
Urticaria 36
Urticaria Pigmentosa 40
Angioneurotic Edema 41
Eczema 41
Dermatitis Seborrhœica (Eczema Seborrhœicum) 58
Impetigo Contagiosa 61
Impetigo Herpetiformis 65
Ecthyma 66

PAGE

Dermatitis Herpetiformis 67
Pemphigus 70
Pompholyx 73
Herpes Simplex 75
Herpes Zoster 77
Lichen Ruber 81
Lichen Scrofulosus 84
Prurigo 84
Acne 86
Acne Rosacea 93
Acne Varioliformis 97
Dermatitis Papillaris Capillitii 98
Sycosis 98
Lupoid Sycosis 102
Psoriasis 102
Pityriasis Rubra Follicularis 110
Pityriasis Rubra 110
Dermatitis Exfoliativa 112
Pityriasis Rosea 114
Erysipelas 115
Erysipeloid 117
Dermatitis 117
Dermatitis Traumatica 118
Dermatitis Calorica 118
Dermatitis Venenata 118
Dermatitis Medicamentosa 120
Dermatitis Gangrænosa 122
Feigned Eruptions 124
Furunculus 124
Carbunculus 126
Equinia 127
Anthrax 128
Postmortem Pustule 129
Ainhum 130
Tinea Trichophytina 130
Tinea Circinata 130
Tinea Tonsurans 135
Tinea Sycosis 139
Tinea Versicolor 142
Tinea Favosa 145
Erythrasma 151
Actinomycosis 151
Mycetoma 153
Scabies 153
Pediculosis 158
  Pediculosis Capitis 158
  Pediculosis Corporis 160
  Pediculosis Pubis 161
Cysticercus Cellulosæ Cutis 162
Dracunculosis 162

PAGE
Ixodes 163
Leptus 163
Œstrus 163
Pulex Penetrans 164
Pulex Irritans 164
Cimex Lectularius 164
Culex 164
CLASS IV. HEMORRHAGES 165
Purpura 165
CLASS V. HYPERTROPHIES 167
Lentigo 167
Chloasma 169
Nævus Pigmentosus 170
Callositas 171
Clavus 172
Cornu Cutaneum 173
Ichthyosis 175
Verruca 178
Molluscum Epitheliale 180
Comedo 182
Milium 185
Cystis Sebacea 185
Keratosis Pilaris 186
Keratosis Follicularis 187
Hypertrichosis 188
Elephantiasis 192
Dermatolysis 194
Onychauxis 195
CLASS VI. ATROPHIES 196
Albinismus 196
Vitiligo 197
Atrophia Cutis 199
Xeroderma Pigmentosum 201
Sclerema Neonatorum 202
Scleroderma 203
Morphea 205
Canities 206
Alopecia 207
Alopecia Areata 209
Atrophia Pilorum Propria 215
Atrophia Unguis 216
CLASS VII. NEW GROWTHS 216
Keloid 216
Fibroma 218
Neuroma 220
Xanthoma 220
Myoma 222
Nævus Vasculosus 223
Telangiectasis 224
Lymphangioma 224

PAGE
Rhinoscleroma 225
Lupus Erythematosus 226
Lupus Vulgaris 230
Blastomycetic Dermatitis 237
Scrofuloderma 237
Verruca Necrogenica 239
Syphiloderma 240
Lepra 256
Frambesia 260
Epithelioma 261
Paget's Disease of the Nipple 264
Sarcoma 266
Granuloma Fungoides 266
CLASS VIII. ANOMALIES OF SECRETION OF GLANDS 268
Hyperidrosis 268
Bromidrosis 270
Anidrosis 271
Chromidrosis 271
Uridrosis 272
Hematidrosis 272
Phosphoridrosis 272
Sudamen 272
Miliaria 273
Hidrocystoma 274
Hidradenitis Suppurativa 275
Seborrhea 275
Asteatosis 279
CLASS IX. NEUROSES 279
Hyperesthesia 279
Dermatalgia 279
Anesthesia 280
Pruritus 280
INDEX 283

LIST OF ILLUSTRATIONS.

FIG.		PAGE
1.	Anatomy of the Skin	10
2.	Epidermis	11
3.	Prickle Cells	12
4.	Blood-supply of Skin	13
5.	Tactile Corpuscle	15
6.	Pacinian Corpuscle	16
7.	Normal Hair of the Beard	18
8.	Transverse Section of the Nail	19
9.	Exudative Erythema	30
10.	Dermographism	37
11.	Eczema Pustulosum	42
12.	Vesiculo-squamous Eczema	44
13.	Section of Skin from Chronic Eczema	47
14.	Seborrheic Dermatitis	59
15.	Impetigo Contagiosa	62
16.	Annular and Serpiginous Form of Contagious Impetigo	63
17.	Bullous Type of Impetigo Contagiosa	64
18.	Section of Pompholyx	74
19.	Herpes Zoster Supra-orbitalis	78
20.	Herpes Zoster Cervico-brachialis	79
21.	Herpes Zoster Lumbo-femoralis	79
22.	Section of Papule of Lichen Planus	82
23.	Acne, Comedo, and Sebaceous Abscess	88
24.	Kaposi Acne Lance	93
25.	Acne Rosacea	94
26.	Acne Hypertrophica	95
27.	Sycosis	99
28.	Psoriasis	103
29.	Psoriasis	104
30.	Section of Psoriasis Papule	105
31.	Section of Pityriasis Rubra	111
32.	Epidermal Casts of the Palms and Soles	113
33.	Ivy Poisoning	119
34.	Tinea Cruris	131
35.	Tinea Circinata	132
36.	Tinea Circinata	133
37.	Ringworm of the Scalp	135
.	Hair and Root Sheath in Tinea Tonsurans	136

FIG. PAGE
39. Tinea Sycosis 140
40. Fungus in Tinea Sycosis 141
41. Tinea Versicolor 143
42. Microsporon Furfur 144
43. Tinea Favus of the Body 147
44. Hair Shaft in Favus 148
45. Fungus from Favus-cup 149
46. Actinomyces Showing Ray Arrangement 152
47. Burrow of Scabies 154
48. Female Acarus of Scabies 155
49. Ova of Pediculi 159
50. Male Pediculus Capitis 159
51. Female Pediculus Corporis 160
52. Pediculus Pubis 161
53. Leptus 163
54. Cutaneous Horn 174
55. Ichthyosis 176
56. Molluscum Epitheliale 181
57. Section of Molluscum Epitheliale 182
58. Demodex Folliculorum 183
59. Demodex Folliculorum 183
60. Clover's Acne Presser 184
61. Hypertrichosis—"Dog-faced Man" 188
62. Nævus Pilosus et Lipomatodes 189
63. Galvanic Battery 190
64. Electrolysis Needle-holder 191
65. Elephantiasis 193
66. Hypertrophy of Nail 195
67. Vitiligo in a Colored Woman 198
68. Atrophy of the Skin 200
69. Scleroderma 203
70. Alopecia Areata in Mother and Child 210
71. Alopecia Areata 211
72. Alopecia Areata 212
73. Trichorrhexis Nodosa 215
74. Section of Keloid 217
75. Section of Fibroma 218
76. Fibroma Molluscum 219
77. Section of Xanthoma 221
78. Section of Myoma 223
79. Rhinoscleroma 226
80. Lupus Erythematosus 227
81. Section of Lupus Erythematosus 228
82. Lupus Vulgaris 231
83. Section of Lupus Vulgaris 232
84. Dermal Curets 235
85. Multiple Scarifier 236
86. Verruca Necrogenica 239
87. Papulo-tubercular Syphilide 243
Moist Papules 244

FIG. PAGE
89. Papulo-squamous Syphiloderm 246
90. Ulcerating Gummatous Syphilide 250
91. Section of Syphilitic Papule 252
92. Section of Circinate Squamous Syphilide..... 253
93. Tubercular Leprosy 257
94. Mutilation of Hands in Anesthetic Leprosy..... 258
95. Mixed Tubercular and Anesthetic Leprosy..... 259
96. Section of Squamous Epithelioma 261
97. Section of Cylindric-celled Epithelioma 261
98. Superficial Flat Epithelioma 262
99. Section of Round-celled Sarcoma 265
100. Section of Spindle-celled Sarcoma 265
101. Section of Melanotic Sarcoma 265
102. Section of Giant-celled Sarcoma 265
103. Mycosis Fungoides 267
104. Section of Mycosis Fungoides 268
105. Normal Sweat-gland 269
106. Normal Sebaceous Gland 277

DISEASES OF THE SKIN.

EMBRYONIC DEVELOPMENT OF THE SKIN.

The **corium** is derived from the superficial layer of the *mesoderm*, called the "skin plate." At the end of the fourth week the cutis is made up of embryonic corpuscles, which develop into spindle-shaped protoplasmic bodies between the second and third month. They are of a fibromyxomatous nature. Blood-vessels are first formed at this time.

The **epidermis** is derived from the ectoderm. It is represented at the end of the first month by a single layer of epithelial cells upon the surface of the body.

ANATOMY OF THE SKIN.

The skin may be said to be composed of three distinct layers: the epidermis, the corium, and the subcutaneous tissue.

The **epidermis** or cuticle consists of four layers:

(*a*) Stratum corneum.

(*b*) Stratum lucidum.

(*c*) Stratum granulosum.

(*d*) Stratum mucosum.

(*a*) The **stratum corneum** (horny layer) is made up of superimposed rows of elongated horny cells. This layer forms a protective surface for the softer strata beneath.

(*b*) The **stratum lucidum** (clear layer) consists of from two to four rows of bright, transparent, homogeneous, elon-

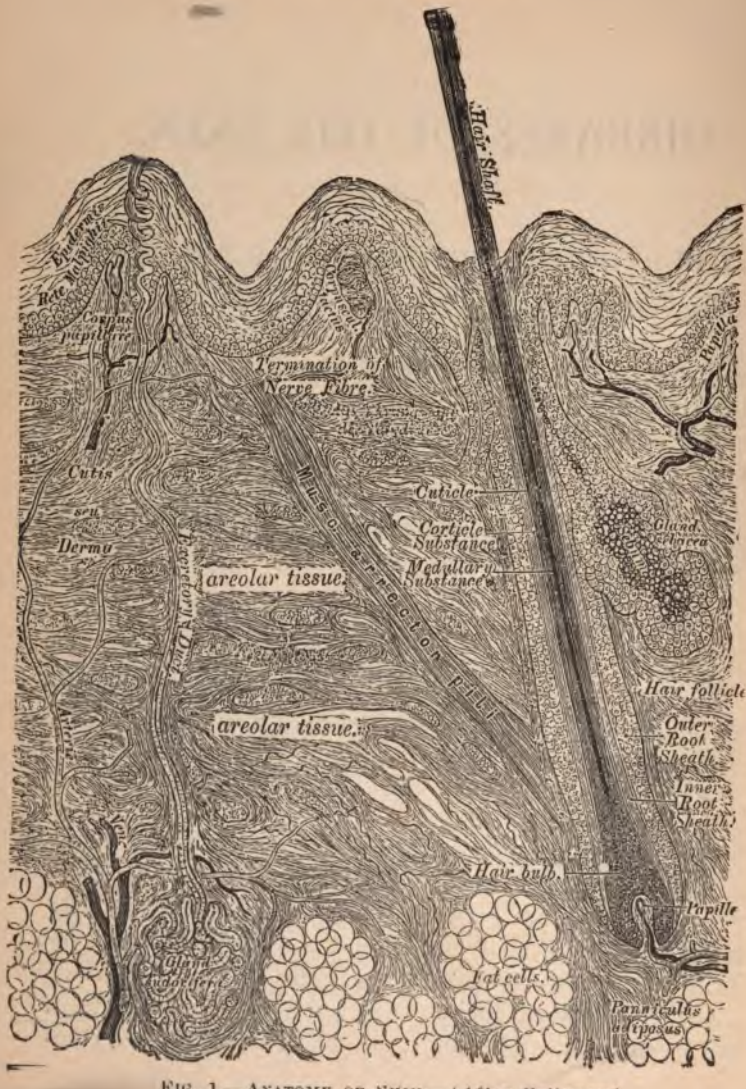

FIG. 1.—ANATOMY OF SKIN.—(*After Heitzman.*)

gated cells. This layer is of minor importance, and is considered by many a part of the stratum corneum.

(*c*) The **stratum granulosum** (granular layer) is made up of several rows of flattened granular cells. These gran-

FIG. 2.—*c*. Horny layer. *g*. Granular layer. *m*. Mucous layer. *n*. Afferent nerve. *b*. Terminal nerve bulbs. *l*. Cell of Langerhans.—(*After Ranvier.*)

ules contain a substance called keratohyalin. An allied substance, eleidin, is also present.

(*d*) The **stratum mucosum** (mucous layer, rete Malpighii) is the deepest and the most important layer of the

epidermis. The basal layer consists of columnar epithelial cells, which contain the skin-pigment. These cells lie in contact with the papillæ of the corium. Above the columnar layer are irregular layers of polygonal nucleated cells with serrated borders (prickle cells). As the granular layer is approached, the cells become more fusiform in shape. There are no blood-vessels in the epidermis, but there exist intercellular spaces which contain a nutrient fluid.

The **corium** (derma, cutis vera) is a thick layer made up of white fibrous tissue interspersed here and there with yel-

FIG. 3.—PRICKLE CELLS.—(*After Ranvier.*)

low elastic tissue. It contains blood-vessels, nerves, lymphatics, nerve-corpuscles, hair, sweat- and sebaceous-glands, muscle, and fat-cells. It consists of two layers:

(*a*) PARS PAPILLARIS (papillary layer).
(*b*) PARS RETICULARIS (reticular layer).

(*a*) The **papillary layer** is made up of finger-like prominences which dovetail into the rete prolongations. The papillæ are supplied with blood-vessels, nerves, lymphatics, and nerve-corpuscles.

(*b*) The **reticular layer** is made up of loosely arranged

bundles of connective tissue. This layer merges into the papillary layer without a line of demarcation.

FIG. 4.—BLOOD-SUPPLY OF SKIN.—(*After Ranvier.*)
C. Epidermis. *S.* Sweat-duct. *P.* Papillæ. *v.* Papillary capillaries. *vs.* Deep plexus supplying sweat-coils. *D.* Corium.

The **subcutaneous tissue** (stratum subcutaneum) is made up of a loosely arranged network of connective tissue be-

tween the meshes of which are contained fat-globules (*panniculus adiposus*). The deeper hair-follicles and sweat-glands also find lodgment in this layer.

Blood-vessels.—Two horizontal plexuses exist in the skin—a superficial and a deep one. The former occupies the papillary layer; the latter, the subcutaneous tissue. The deep plexus sends branches to the sweat- and sebaceous-glands and to the hair-follicles. The superficial plexus sends vessels to the papillæ, where capillary loops are formed.

Lymph-vessels.—There appear to be also superficial and deep lymph-plexuses in the skin, following in a general way the blood-vessels. Juice-spaces filled with lymph occur at all levels in the corium.

Nerves.—The skin contains both medullated and non-medullated nerve-fibers. When the former end in the subcutaneous connective tissue, they terminate in Pacinian corpuscles; when they end in the papillæ of the skin, they form tactile corpuscles. The nonmedullated fibers penetrate the corium, and are lost in the mucous layer of the epidermis. The skin also contains motor and vasomotor nerves.

Nerve-corpuscles.—(*a*) The *corpuscles of Krause* (bulb corpuscles) are found chiefly in the sensory mucous membranes, most abundantly in the conjunctiva. They are round or elongated bodies, and resemble the Pacinian corpuscles.

(*b*) The *tactile corpuscles* (touch corpuscle, corpuscle of Meissner) are found in the skin-papillæ, most abundantly in the fingers. They are round or oval fibrous masses with a striated covering.

(*c*) The *Pacinian corpuscles* are most numerous in the skin of the fingers and toes. They lie, for the greater part, in the subcutaneous tissue. They are oval bodies made up of a "central nerve-fiber," a "core," or surrounding substance, and a "capsular covering," which has many concentric layers.

Muscle.—Both voluntary and involuntary muscle-fibers

occur in the skin. Striated muscle is found in the skin of the face. Smooth muscle exists in the scrotum and in connection with hair-follicles. The contraction of the hair-muscle causes the hair to rise, and also expresses sebum from the sebaceous glands.

Sebaceous glands are racemose glands situated in the corium, chiefly in contiguity with hair-follicles. They may,

FIG. 5.—TACTILE CORPUSCLE.—(*After Biesiadecki.*)
a. Vascular papilla. *b.* Nervous papilla. *c.* Blood-vessel. *d.* Medullated nerve-fiber. *e.* Tactile corpuscle. *f, f.* Transversely divided medullated nerve-fibers.

however, occur independently of them, as upon the border of the lip, penis, etc. They consist of one or more pouches, which empty into a common duct. Sebum consists of fatty degenerated cells mixed with epithelial débris.

Sweat-glands are simple tubular glands which lie in coils in the deeper layers of the corium and in the subcutaneous tissue. They empty into excretory ducts, which traverse the

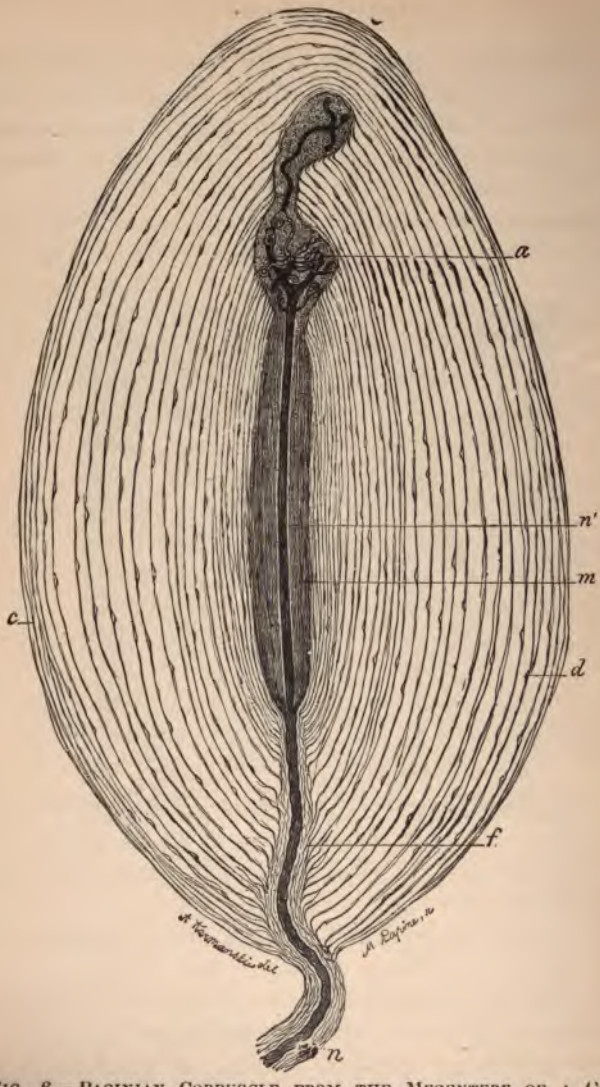

FIG. 6.—PACINIAN CORPUSCLE FROM THE MESENTERY OF A CAT.—(*After Ranvier.*)

c. Capsules. *d.* Endothelial lines which separate them. *n.* Afferent nerve. *f.* Funiculus. *m.* Central club formation. *n'.* Terminal fiber. *a.* Point of branching of terminal nerve-fiber.

corium, penetrate the epidermis between the papillæ, and then pursue a spiral course to the surface of the skin. They are most abundant in the palms and soles.

Hair.—Hair is nothing more than a specialized epidermal tissue. The corium and epidermis are somewhat modified in structural arrangement to accommodate the hair. This modification gives rise to the hair-follicle. Hair-follicles are slender, cylindric pockets, which dip down into the corium and the subcutaneous tissue.

The *outer or dermic* coat of the follicle consists of three layers: an external longitudinal fibrous layer, a middle transverse layer, and an internal homogeneous or vitreous layer.

The *internal or epidermic* coat (outer root-sheath of some authors; prickle-cell layer) is a continuation of the mucous layer of the epidermis.

The *root-sheath proper* (inner root-sheath of some authors) is composed of two layers, an external layer (layer of Henle) and an internal layer (layer of Huxley).

The *cuticle* of the root-sheath is a thin layer of cells lying internal to the root-sheath.

From without inward, then, the coats of the follicle are:

(*a*) Dermic coat, three layers.

(*b*) Epidermic coat (outer root-sheath; prickle-cell layer).

(*c*) Root-sheath proper (inner root-sheath) { layer of Henle.

(*d*) Cuticle of the root-sheath, { layer of Huxley.

The skin outlet of the follicle is called the *mouth.* The *neck* corresponds to the constriction near the entrance of the sebaceous duct. The *bulb* is the dilated lower end of the follicle.

The hair itself consists of a *cortex* or cortical substance which constitutes the bulk of the hair, the *medulla,* which lies in the medullary canal, and the *cuticle,* a thin membrane covering the hair. The portion of the hair outside the skin is called the *shaft,* that in the skin, the *root,* the nether ter-

FIG. 7.—NORMAL HAIR OF THE BEARD.—(*After Biesiadecki.*)

a. Excretory duct. *b.* Neck of the follicle. *c.* Dilatation of the hair-follicle. *d.* External sheath of the hair-follicle. *e.* Internal sheath of the hair-follicle. *ep.* Epidermis. *f.* External root-sheath. *g.* Internal root-sheath. *h.* Cortical substance. *k.* Medullary substance of hair-shaft. *l.* Root of hair. *m.* Fat-cells. *n.* Arrector pili. *o.* Papillæ of skin. *p.* Papilla. *s.* Rete mucosum. *t.* Sebaceous gland.

mination of which constitutes the *bulb;* the concavity of the bulb fits over the papilla, through which the nourishment of the hair is supplied.

Nail.—The nail, like the hair, is a specialized epidermal structure. It is composed of two layers, the mucous or soft layer, and the horny which constitutes the nail proper.

The *nail bed* is the tissue covered by the nail. The posterior end of this is the *matrix* from which the nail grows. The exposed portion of the nail is termed the *body*. The

FIG. 8.—TRANSVERSE SECTION OF A NAIL, MADE THROUGH THE PROPER BED OF THE NAIL.—(*After Biesiadecki.*)

a. Nail. *b.* Loose horny layer beneath it. *c.* Mucous layer. *d.* Transversely divided nail ridges with injected blood-vessels. *e.* Nail fold destitute of papillæ. *f.* Horny layer of nail-fold. *g.* Papillæ of skin.

posterior portion embedded in the groove is the *root.* The *nail groove* is the groove extending around the proximal portion of the nail. From this springs the *nail fold.* The thin skin that often becomes adherent to the nail is called the *nail skin* or eponychium. The whitish crescent on the nail is the *lunula,* and is due to a lessened translucency of that portion. Accidental white spots on the nail are due to the presence of air between the lamellæ.

SYMPTOMATOLOGY.

A. OBJECTIVE SYMPTOMS.

Lesions upon the skin may be *primary* or *secondary*. The primary lesions constitute the initial manifestations upon the skin. The secondary lesions result from either natural or accidental modification of the primary lesions.

The primary lesions consist of macules, papules, vesicles, blebs, pustules, tubercles, wheals, and tumors.

Maculæ (macules) are circumscribed discolored patches of skin of variable shape and size, without elevation or depression.

Papulæ (papules) are circumscribed solid elevations of the skin, varying in size from a pin-head to a pea.

Vesiculæ (vesicles) are pin-head- to pea-sized circumscribed elevations of the epidermis, containing clear or opaque fluid.

Bullæ (blebs) are round or irregularly shaped pea- to egg-sized elevations of the epidermis containing clear or opaque fluid.

Pustulæ (pustules) are circumscribed flat or acuminate elevations of the epidermis containing pus.

Pomphi (wheals) are edematous circumscribed irregular pinkish elevations of the skin, transitory in character.

Tubercula (tubercles) are circumscribed, solid, deep-seated elevations of the skin attaining or surpassing the size of a pea.

Tumores (tumors) are variously sized and shaped prominences, having their seats in the corium or subcutaneous tissue.

The secondary lesions comprise scales, crusts, excoriations, fissures, ulcers, scars, and stains.

Squamæ (scales) are dry epidermal exfoliations shed he surface of the skin.

e (crusts) are brownish or yellowish masses of ation.

Excoriationes (excoriations) are epidermal denudations, usually the result of local traumatism.

Rhagades (fissures) are linear cracks or wounds in the epidermis or corium due to disease or injury.

Ulcera (ulcers) are round or irregular losses of tissue involving the skin and subcutaneous tissue.

Cicatrices (scars) are connective-tissue new formations occupying the region of former losses of tissue.

Pigmentationes (stains) are discolorations of the skin left after the disappearance of cutaneous lesions.

B. SUBJECTIVE SYMPTOMS.

Among the subjective phenomena occurring in skin diseases may be mentioned sense of heat, burning, itching, smarting, tingling, and pain. These are present in the different dermatoses in varying degrees of intensity.

CLASSIFICATION.

The classification of Duhring has been adopted in the presentation of the subject. It is as follows:

CLASS I.—ANÆMIÆ—ANEMIAS.

[*Transient or Persistent, General or Local.*]

CLASS II.—HYPERÆMIÆ—CONGESTIONS.

[*Process Congestive, Diffuse or Circumscribed, chiefly Superficial.*]

		Predominant Lesions.
ERYTHEMA HYPERÆMICUM.	Active.	Erythematous.
LIVEDO, CYANOSIS.	Passive.	

CLASS III.—EXSUDATIONES—INFLAMMATIONS.

[*Process Inflammatory, Diffuse or Circumscribed, Superficial or Deep-seated.*]

	Predominant Lesions.
ERYTHEMA EXSUDATIVUM.	Erythematous.
ERYTHEMA PERNIO.	
ERYTHEMA EXSUDATIVUM MULTIFORME.	
ERYTHEMA NODOSUM.	
PELLAGRA, ACRODYNIA.	

		Predominant Lesions.
URTICARIA. URTICARIA PIGMENTOSA. ŒDEMA.		Erythematous, Edematous.
ECZEMA.		Erythematous, Papular, Vesicular, Pustular, Squamous or Multiform.
IMPETIGO. IMPETIGO HERPETIFORMIS. ECTHYMA.		Pustular.
DERMATITIS HERPETIFORMIS. PEMPHIGUS. POMPHOLYX. HERPES SIMPLEX. HERPES ZOSTER.		Vesicular, Bullous, or Pustular.
LICHEN. PRURIGO.		Papular.
ACNE. SYCOSIS.		Papular, Tubercular, or Pustular, involving Sebaceous Glands or Follicles.
PSORIASIS. PITYRIASIS RUBRA FOLLICULARIS. PITYRIASIS RUBRA. DERMATITIS EXFOLIATIVA. PITYRIASIS ROSEA.		Erythemato-squamous.
ERYSIPELAS.		Erythematous, Edematous.
MORBILLI. RUBELLA. SCARLATINA.	Eruptive Fevers.	Erythematous, Maculo-papular.
VARIOLA. VACCINIA. VARICELLA.	Eruptive Fevers.	Vesicular, Pustular.
DERMATITIS MEDICAMENTOSA. DERMATITIS VENENATA. DERMATITIS CALORICA. DERMATITIS TRAUMATICA. DERMATITIS NEUROTICA.	Due to Drugs, Poisons, Caloric, Traumatism, etc.	Varied, Multiform, Superficial or Deep-seated.
		Varied, Multiform, Suppurative, Necrotic, Deep-seated.

NA).

		Predominant Lesions.
TINEA TRICHOPHYTINA (TINEA CIRCINATA, TINEA TONSURANS, TINEA SYCOSIS).	Due to Phyto-parasites.	Erythematous, Squamous, Multiform, involving Epidermis, Follicles, Hair, or Nail.
TINEA FAVOSA.		
TINEA VERSICOLOR, TINEA ERYTHRASMA, TINEA IMBRICATA.		
ACTINOMYCOSIS, MYCETOMA.		Nodose, Ulcerative, Deep-seated.
PEDICULOSIS.	Due to Zoo-parasites.	Varied, Multiform, Superficial, or Deep-seated.
SCABIES.		
DRACUNCULOSIS.		
ONYCHIA.		Involving nail.

CLASS IV.—HÆMORRHAGIÆ—HEMORRHAGES.

[*Process Hemorrhagic, Diffuse or Circumscribed, Superficial or Deep-seated.*]

	Structure chiefly involved.
PURPURA.	Corium, Connective Tissue.

CLASS V.—HYPERTROPHIÆ—HYPERTROPHIES.

[*Process Hypertrophic, Formative, Diffuse or Circumscribed, Superficial or Deep-seated.*]

	Structure chiefly involved.
LENTIGO.	Pigment.
CHLOASMA.	
NÆVUS PIGMENTOSUS.	
CALLOSITAS.	Epidermis.
CLAVUS.	
ICHTHYOSIS.	
VERRUCA.	
MOLLUSCUM EPITHELIALE.	
CORNU.	
COMEDO.	Follicles, Sebaceous Glands.
MILIUM.	
CYSTIS SEBACEA.	
KERATOSIS PILARIS.	
KERATOSIS FOLLICULARIS.	
HYPERTRICHOSIS.	Hair.
NÆVUS PILOSUS.	

	Structure chiefly involved.	
SIS. SCROF- LUPUS VUL- YTHEMATO- ROMA. A (YAWS). PERUANA. DERMATI- LLARIS MA- (PAGET'S). A FUN-	Corium, Connective Tissue.	Malignant.

III.—ANNOMALIÆ SECRETIONIS GLANDULARUM—NOMALIES OF SECRETION OF THE GLANDS.

[*Glands Involved Functionally.*]

GLANDULARUM SUDORIPARARUM—SWEAT-GLANDS.

	Predominant Process.
SIS. IS. SIS. OSIS.	Disordered Secretion without Structural Change.
OMA.	Disordered Secretion with Structural Change.

GLANDULARUM SEBACEARUM—SEBACEOUS GLANDS.

.	Increased or Altered Secretion.

CLASS IX.—NEUROSES—NEUROSES.

ory Diseases, Functional, without Primary Lesions.]

	Chief Symptoms.
HESIA. IA.	Increased or Painful Sensation.
	Itching.
IA.	Decreased Sensation.

	Structure chiefly involved.
ONYCHAUXIS.	Nail.
ELEPHANTIASIS.	Corium, Connective Tissue.

CLASS VI.—ATROPHIÆ—ATROPHIES.

[*Process Atrophic, Retrogressive, Diffuse or Circumscribed, S ficial or Deep-seated.*]

	Structure chiefly involved.
ALBINISMUS. VITILIGO.	Pigment.
ATROPHIA CUTIS PROPRIA. XERODERMA PIGMENTOSUM. STRIÆ ET MACULÆ ATROPHICÆ. MORPHŒA. SCLERODERMA.	Corium.
ATROPHIA PILORUM PROPRIA, TRICHORRHEXIS. ALOPECIA. CANITIES.	Hair.
ONYCHATROPHIA, LEUCONYCHIA.	Nail.

CLASS VII.—NEOPLASMATA—NEW FORMATIONS.

[*Process Neoplastic, Benign or Malignant, Diffuse or Circumscr chiefly Deep-seated.*]

	Structure chiefly involved.	
FIBROMA. NEUROMA. CICATRIX. KELOID. XANTHOMA.	Corium, Connective Tissue.	Benign.
MYOMA.	Muscle.	
ANGIOMA, NÆVUS VASCULOSUS, TELANGIECTASIS.	Blood-vessels.	
LYMPHANGIOMA.	Lymph-vessels.	
	Glands.	

	Structure chiefly involved.	
TUBERCULOSIS, SCROFULOSIS, LUPUS VULGARIS. LUPUS ERYTHEMATOSUS. RHINOSCLEROMA. SYPHILIS. FRAMBŒSIA (YAWS), VERRUGA PERUANA. LEPRA. CARCINOMA DERMATITIS PAPILLARIS MALIGNA (PAGET'S DISEASE). SARCOMA. GRANULOMA FUNGOIDES.	Corium, Connective Tissue.	Malignant.

CLASS VIII.—ANNOMALIÆ SECRETIONIS GLANDULARUM—ANOMALIES OF SECRETION OF THE GLANDS.

[*Glands Involved Functionally.*]

A. GLANDULARUM SUDORIPARARUM—SWEAT-GLANDS.

	Predominent Process.
HYPERIDROSIS. BROMIDROSIS. CHROMIDROSIS. HÆMATIDROSIS. URIDROSIS. ANIDROSIS.	Disordered Secretion without Structural Change.
SUDAMEN. HIDROCYSTOMA. MILIARIA.	Disordered Secretion with Structural Change.

B. GLANDULARUM SEBACEARUM—SEBACEOUS GLANDS.

SEBORRHŒA.	Increased or Altered Secretion.

CLASS IX.—NEUROSES—NEUROSES.

[*Sensory Diseases, Functional, without Primary Lesions.*]

	Chief Symptoms.
HYPERÆSTHESIA. DERMATALGIA.	Increased or Painful Sensation.
PRURITUS.	Itching.
ANÆSTHESIA.	Decreased Sensation.

CLASS I.—ANAEMIAE—ANEMIAS.

Anemia of the skin is characterized by a reduction in the quantity or a change in the quality of the blood in the integument. It may be transient or persistent.

Transient anemia occurs after hemorrhages, during certain nervous states, such as fear, anger, and in shock, fainting, etc.

Persistent anemia occurs in connection with the various essential anemias and cachexias. It occurs, moreover, in morphœa, scleroderma, and alopecia areata as a result of trophic disturbances.

Local anemias from faulty innervation and the chronic anemias may lead to the development of seborrhea, comedo, acne, and acne rosacea.

CLASS II.—HYPERAEMIAE—HYPEREMIAS

Hyperemia, or congestion, is characterized by an overfilled state of the blood-vessels of the integument, unattended by inflammation. Hyperemia may be *acute* or *passive*. Each form may be further subdivided into idiopathic and symptomatic hyperemia.

Idiopathic active hyperemia is a local congestion due to the action of an irritant, such as a mustard plaster.

Symptomatic active hyperemia is due to visceral or nervous disturbances. Flushing and blushing are familiar examples of this form.

Idiopathic passive hyperemia is characterized by blueness of the skin, or *livedo*. It may be caused by exposure to cold or heat, chemic substances, continued pressure, contusions,

and circulatory obstruction resulting from bandages, ligatures, articles of dress, etc.

Symptomatic passive hyperemia results from some general disturbance affecting the cardiac, circulatory, or respiratory system. It is characterized by blueness of the skin, to which the term *cyanosis* has been applied.

ERYTHEMA HYPERÆMICUM.

Derivation.—*Ἐρύθημα*, a blush.

Synonym.—Erythema simplex.

Definition.—Erythema hyperæmicum is a congestive disorder of the skin, characterized by nonelevated, variously sized and shaped patches of redness.

Symptoms.—Redness is the essential characteristic of the disease. It may be a bright or a dull red, but always disappears upon pressure. Infiltration and elevation are absent. Mild burning and itching are usually present.

Etiology.—Erythema may be due to external or local causes and internal causes. When not arising from local causes, it is due to a toxemia of one character or another. Local causes are heat, cold, traumatism, poisons, etc.

Erythema caloricum is due to exposure to extremely high or low temperatures.

Erythema solare (sunburn) is due to exposure to the actinic rays of the sun.

Erythema traumaticum is due to cutaneous injury.

Erythema venenatum is due to exposure to poisonous plants.

The internal, or *toxemic* erythemata are exemplified in the stomach rashes of children, in intestinal auto-intoxication, after the use of various antitoxins, drugs, etc.

Treatment.—If the erythema is due to a toxemia, it is evident that treatment must be directed toward this condition.

A saline purge will promptly relieve an erythema due to the absorption of ptomains from the intestinal tract.

Stomach rashes in children will nearly always succumb to fractional doses of calomel.

The local treatment consists of the use of dusting powders and cooling lotions. The following may be employed:

℞. Acidi carbolici, ... ♏xxx
Acidi borici, ... ʒj
Glycerini . . . . . f ʒij
Aquæ, ... q. s. ad . . f ℥vj

ERYTHEMA INTERTRIGO.

Erythema intertrigo (*chafing*) is a form of traumatic erythema occurring chiefly in those regions where skin surfaces are in apposition, such as the genitals, flexures of joints, neck, etc. It is common in children and fat individuals. Moist diapers and the contact of intestinal discharges are often causative. The condition may remain as an erythema or may develop into dermatitis or an eczema. It is then characterized by redness, excoriation, and a mucoid discharge. There is usually a feeling of heat and soreness.

Treatment.—When the condition remains as a true erythema, dusting powders suffice. The following is a useful combination:

℞. Magnes. Carbonat.,
Talci Venet.,
Zinci oxidi, ... āā ʒij. M.
SIG.—Dusting powder.

Or a lotion may be employed, such as:

℞. Resorcini,
Acidi borici,
Glycerini . . . . . āā ʒi
Zinci oxidi, ... ʒij
Aquæ, ... q. s. ad . . f ℥j.

If an eczema or a dermatitis supervene, the condition should be treated according to the principles laid down in the treatment of those affections.

CLASS III.—EXSUDATIONES—INFLAMMATIONS.

ERYTHEMA EXSUDATIVUM.

This group comprises a number of diseases characterized by erythematous inflammation. They are, in addition, polymorphous. Erythema hyperæmicum is a congestive disease; erythema exsudativum is inflammatory. Under the latter head are included: Erythema multiforme, erythema nodosum, erythema scarlatinoides, the acute exanthematous eruptions, the erythema occurring in Bright's disease, septicemia, etc.

ERYTHEMA MULTIFORME.

Synonym.—Erythema exsudativum multiforme.

Definition.—Erythema multiforme is an inflammatory disease, characterized by variously sized and shaped patches of erythema, papules, vesicles, and blebs, running an acute course, and accompanied, as a rule, by constitutional disturbances.

Symptoms.—The disease is often preceded or accompanied by febrile disturbances, malaise, rheumatoid pains, etc. The eruption, which comes out more or less suddenly, may consist of macules, maculo-papules, vesicles and blebs, one type of lesion as a rule predominating. After remaining stationary for some days, the eruption gradually disappears. Any part of the body may be involved, although the disease exhibits a marked predilection for the backs of the hands and feet, and not infrequently the face and neck. Itching and burning, when present, are usually mild. The lesions are at first bright red, but later become purplish or bluish in color.

When the patches are circular with peripheral spreading and central clearing up, the affection is called *erythema circinatum,* or *erythema annulare.* Concentric rings of variegated colors are termed *erythema iris,* and when the rings

are made up of vesicles, *herpes iris.* The fusion of circular patches may produce gyrate or festooned configurations—

FIG. 9.—EXUDATIVE ERYTHEMA—FOLLOWING THE USE OF DIPHTHERIA ANTITOXIN. Eruption consists of macules, papules and vesicles, and is an unusual form.

erythema gyratum et figuratum. Erythema papulosum, characterized by discrete or aggregated pea- to bean-sized

reddish or violaceous maculo-papules or papules, is the commonest expression of the disease. *Erythema vesiculosum* and *erythema bullosum* are characterized respectively by vesicles and blebs.

The eruption comes out in crops and lasts from one to four weeks. In some cases there is a distinct tendency to recurrence.

Etiology.—The disease occurs most frequently in youth and early adult life. Most cases are observed in spring and autumn. Duhring looks upon erythema multiforme as a general disease of infectious or nervous origin, and considers the skin manifestations merely conspicuous symptoms. Upon this point there is considerable divergence of opinion. Intestinal ptomain absorption is regarded as a frequent cause.

Pathology.—There is dilatation of the papillary and subpapillary blood-vessels, with serous and sometimes moderate cellular exudation into the tissues. The affection is an angioneurosis.

Diagnosis.—The distinguishing features of this disease are the distribution, peculiar coloration and multiformity of the lesions, the acute course, the spontaneous involution of the eruption, and the associated general symptoms.

Prognosis.—Good. The tendency of some cases to recur should be remembered.

Treatment.—Quinin and sodium salicylate have been particularly recommended. Symptomatic eruptions must be treated according to the individual indications. The salines are to be employed when constipation exists, or intestinal auto-intoxication is suspected.

Locally, soothing lotions, such as the following, may be used:

℞. Acidi carbolici, ... ♏xxx
Acidi borici, ... f ʒj
Glycerini, ... f ʒij
Aquæ, ... q. s. ad . . f ℥vj.

Alco + Hz

ERYTHEMA SCARLATINOIDES.

Definition.—Scarlatiniform erythema is a non-contagious eruption resembling true scarlatina in its cutaneous manifestations, but running a quite different course.

Symptoms.—The condition comes on suddenly, and is usually attended with malaise, chill, and a temperature varying from 100° to 103° F. The eruption is either punctiform or diffuse, and may begin on any portion of the body. It may be quite sharply defined. The face is usually exempt. Desquamation occurs about the third or fourth day, and may be either furfuraceous or lamellar. At times a glove-like cast of the hand is exfoliated. The hair and nails are occasionally shed. After a duration of from one to six days the eruption disappears. There is a marked tendency to recurrence.

Etiology.—Obscure. Idiosyncrasy plays a most important rôle. The affection is apt to supervene during the course of other diseases, chief among which may be mentioned rheumatism, pyemia, septicemia, malaria, peritonitis, uremia, ptomain poisoning, smallpox, typhoid fever, diphtheria, etc. The affection is less common since the introduction of antisepsis. Eruptions indistinguishable from scarlatiniform erythema follow at times the ingestion of drugs, particularly mercury, quinin, salicylates, opium, copaiba, belladonna, etc.

Diagnosis.—It is extremely important to differentiate this disease from scarlatina.

Scarlatiniform Erythema.	Scarlet Fever.
1. Onset with mild constitutional symptoms.	1. Onset with more severe constitutional disturbances, and commonly with vomiting.
2. Eruption frequently not generalized; erythema at times marginated.	2. Eruption diffusely generalized, and not marginated save at times on arms.
3. Face often exempted.	3. Face frequently exhibits eruption. Cheeks deeply flushed, with circum-oral pallor.

4. Tongue may be quite normal.	4. Tongue coated—edges red—papillæ enlarged.
5. Fauces may be reddened.	5. Fauces swollen, tonsils enlarged, and often coated with thin yellowish exudate.
6. Desquamation may be intense, but terminates comparatively early.	6. Desquamation may continue from four to ten weeks. Cleavage of cuticle at free border of nail quite characteristic.
7. History perhaps of previous attacks.	7. Second attacks of genuine scarlet fever are rare.
8. Not contagious.	8. Frequently history of contagion.

Prognosis.—Favorable. Recurrences not infrequent.

Treatment.—For the eruption, simple dusting powders or starch or bran baths may be used. The underlying condition must be ascertained and treated. A saline purge is usually indicated at the outset.

ERYTHEMA NODOSUM.

Synonym.—Dermatitis contusiformis.

Definition.—Erythema nodosum is an acute inflammatory disease of the skin, characterized by the formation of roundish or oval node-like swellings.

Symptoms.—The disease is usually ushered in with fever, articular pains, malaise, and coated tongue. Soon roundish or oval node-like swellings, varying in size from a hazel-nut to an egg, develop over the region of the tibiæ. In some cases the forearms, trunk, and face are involved. The nodes are rosy red in color, tense and shining like erysipelas, and exquisitely tender to the touch. At first hard, they later soften, but never suppurate. Their duration is from a week to ten days, during which time they undergo all the color gradations observed in common contusions. In number they vary from about five to twenty. Erythema nodosum is frequently associated with other forms of erythema multiforme.

Etiology.—The affection is one of childhood and adolescence. It is uncommon after the age of thirty. It is met with twice as frequently in girls as in boys. Rheumatism, gastro-intestinal disorders, and general nutritive disturbances are not infrequently associated. The disease is probably closely allied to, and perhaps a form of, erythema multiforme.

Pathology.—The nodes show serous exudation throughout the entire cutis and even the subcutaneous tissue. There is dilatation of the lymph-spaces and some cell infiltration. Blood pigment from hemorrhages is present.

Diagnosis.—The distribution, tenderness, symmetry, course, and color changes of the lesions enable one to differentiate the affection from bruise, abscess, gumma, and erythema induratum.

Prognosis.—Favorable, recovery ensuing in from two to six weeks.

Treatment.—Regulation of the bowels by salines. Internally, quinin or salicylate of soda. Locally, hot lead-water and laudanum, rest, and elevation of the limbs.

ERYTHEMA INDURATUM.

Synonym.—Erythème induré des scrofuleux (Bazin).

Definition.—Erythema induratum is an inflammatory affection occurring in scrofulous individuals, and characterized by circumscribed infiltrations of the skin ending either in absorption or necrosis.

Symptoms.—Strumous girls and young women are most liable to it. It may, however, occur in boys, and occasionally in elderly subjects. It is most frequent in winter, and attacks individuals who suffer from cold hands and feet. Overwork and prolonged standing seem to be etiologic factors. The lesions consist of ill-defined, finger-nail-sized or larger, bluish-red, infiltrated patches, involving with predilection the calves of the legs. As a rule, but one or two plaques are

present. Pain and tenderness are generally absent, but may be marked. The infiltration may gradually be absorbed or may slough, leaving an indolent ulcer. The affection is rare.

Diagnosis.—The absence of systemic disturbance and tenderness, the long duration, the relapses, and the paucity of lesions distinguish this affection from erythema nodosum. The subjects usually present other signs of the tuberculous diathesis.

Prognosis.—The affection may persist for a long time. Even after apparent cure, relapses are prone to occur.

Treatment.—The treatment leaves much to be desired. Tonics, good food, and prolonged rest, with elevation of the legs, are the chief therapeutic measures.

PELLAGRA.

Derivation.—*Pellis* (L.) skin; *aeger* (L.) diseased.

Definition.—An endemic tropho-neurotic disease of toxic origin, produced by diseased maize and affecting the cerebro-spinal, digestive, and cutaneous systems (Crocker).

Symptomatology.—The constitutional symptoms are those of progressive physical and mental debility. The eruption consists of a bright, dark, or livid erythema, which affects chiefly the exposed parts, such as the face, neck, and hands. The skin is swollen and the seat of burning and itching. The skin manifestations present three stages: (1) Congestion; (2) thickening and pigmentation; (3) atrophic thinning.

The disease tends to disappear in the winter and return in the spring.

Etiology.—The affection is due to toxins developed in fermented maize. It is a disease of the poor peasantry of certain districts, particularly of Italy.

Prognosis.—In very mild cases patients may recover. Most cases grow progressively worse and die.

Treatment.—Nutritious food and good hygiene. Arsenic.

ACRODYNIA.

Synonym.—Epidemic erythema.

Definition.—Acrodynia is an acute epidemic disease, characterized by an erythematous eruption, thickening, desquamation, and pigmentation of the skin, and disorders of the nervous system.

Symptoms.—The salient features of the affection are: Gastro-intestinal irritation, conjunctival injection, edema of the face, erythematous eruption upon the hands and feet, thickening desquamation, and pigmentation of the skin, and sensory disturbances (pain, hyperesthesia, anesthesia, etc.)

Etiology.—The disease is probably caused by the action of some toxic substance upon the central nervous system. It is somewhat related to pellagra.

Prognosis.—Favorable, most cases recovering in a few weeks to a few months.

Treatment.—To be based upon general principles. Brocq advises counterirritation to the spine.

URTICARIA.

Derivation.—*Urtica* (L.), a nettle.

Synonyms.—Hives. Nettle-rash.

Definition.—Urticaria is an inflammatory affection of the skin, characterized by the formation of evanescent whitish and pinkish elevations attended by intense itching.

Symptoms.—The eruption appears suddenly, manifesting itself as firm, circumscribed, whitish or pinkish elevations (wheals, pomphi), with reddish areolæ. The wheals last from a few minutes to several hours, disappear, and are succeeded by others. They are asymmetric, though usually bilateral, of pea- or bean-size, and irregular in shape, often, however, being linear. They may involve any portion of the cutaneous surface, or even the mucous membranes. When the pharynx or larynx is involved, alarming suffocative attacks may occur.

FIG. 10.—DERMOGRAPHISM. LETTERS PRODUCED IN AN URTICARIAL SUBJECT BY WRITING UPON THE SKIN WITH A POINTED INSTRUMENT.

The itching in urticaria is intense, the relief produced by scratching being purchased at the cost of the excitation of new lesions. The skin is markedly sensitive to all sorts of irritation, and responds by the production of wheals. The artificial production of wheals gives rise to the form termed *urticaria factitia.* In some urticarial subjects one can inscribe a name upon the skin with a pointed instrument, and in a few minutes observe the letters stand out in wheals as if embossed. To this phenomenon the term dermographism is given. Such a reaction may also be provoked in those who may not be the subjects of spontaneous urticarial outbreaks.

In children urticaria is apt to take the papular form, *urticaria papulosa* (*lichen urticatus*). In such cases there are inflammatory papules present with or without the presence of wheals. The summits of the papules are apt to be excoriated on account of the scratching prompted by the intolerable itching.

In some individuals wheals attain the size of an egg or even larger. This form is called *urticaria tuberosa* or *urticaria gigans* (giant urticaria).

Hemorrhage into the wheal occurs occasionally, giving rise to the form known as *urticaria hæmorrhagica.*

At times the upper layers of the wheal are raised into a bleb by the subjacent serum: this type is designated *urticaria bullosa.*

Urticaria, as a rule, runs an acute course, subsiding in a few days. In exceptional instances, however, it may become chronic, wheals appearing, disappearing, and reappearing, the process extending over a period of months or even years.

Etiology.—The great majority of cases of acute urticaria are produced through some disorder of the alimentary tract. Substances taken into the stomach may cause urticaria, either by a mechanical irritation of the stomach or bowel, or by producing a toxemia. Intestinal parasites and undigested ali-

ment act by mechanical irritation. The substances capable of producing toxemia are almost numberless. They may be primarily toxic, or may only develop their toxicity through putrefactive changes while in the bowel. Again, a large number of substances, both foods and drugs, perfectly innocuous to the ordinary individual, act, on account of idiosyncrasy, as poisons to others. The following articles of food are particularly apt to produce hives: Lobsters, crabs, mussels, cheese, sausage, pork, nuts, strawberries, oatmeal, mushrooms, etc.

The following drugs are prone to produce urticarial eruptions: Quinin, copaiba, cubebs, salicylic acid, morphin, turpentine, chloral, and many of the coal tar products. Urticaria may be produced reflexly also by irritation of the viscera other than the alimentary tract. Thus, irritation of the uterus and adnexa may act as an etiologic factor. Rupture or puncture of hydatid cysts or puncture of pleural effusions may be followed by hives. Again, the disease may be produced by direct local irritation, such as the sting of the nettle, the bite of jelly-fish, mosquito, wasp, etc.

Pathology.—The wheal is produced as a result of direct or reflex disturbance of the vasomotor apparatus. The lesion consists of a circumscribed edema of the cutis. A momentary spasm of the cutaneous vessels is followed by a dilatation, with exudation of serum and some leukocytes. At the summit of the lesion the effusion is so great as to produce a pressure anemia, hence the whitish coloration. The peripheral vessels are engorged, hence the reddish areola.

Diagnosis.—The characteristic features of urticaria are the presence of wheals, their rapid evolution and great evanescence, and the intense itching.

Prognosis.—Acute cases get well in a few days. Chronic cases may persist for a long time and exhaust the entire therapeutic armamentarium of the physician.

Treatment.—In severe acute cases seen early, an emetic should be administered to get rid of the offending substance. Later, magnesium sulphate is to be employed until free catharsis is produced. In subacute cases, salol or phenacetin, in five- to ten-grain doses, after meals, may be used with good results. In chronic cases most earnest efforts should be directed toward the discovery of the cause. The patient's dietary must be the subject of the most careful study. Every detail of occupation, mode of living and of habits must be scrutinized. The most careful examination, however, will, in some cases, fail to disclose any discoverable cause. Most cases will be found to be due to gastro-intestinal disturbances. In such cases the most simple diet should be prescribed. In obstinate cases one will do well to restrict the patient for a few weeks to a milk diet. In neurasthenic patients a rest cure sometimes brings about recovery.

In obscure cases some of the following remedies may be tried: Atropin by mouth or hypodermatically, antipyrin or phenacetin, quinin in full doses, sulphurous acid in dram doses, long-continued course of arsenic in small doses, bromid of potassium, pilocarpin, etc.

Local treatment is necessary to give relief from the harassing itching. The best antipruritic lotions are: Carbolic acid, ʒj-iij to the pint; menthol, gr. v-xv to the ounce; liq. carbonis detergens, ʒij-iij to water ℥viij; saturated solution of benzoic acid; alkaline baths (one-quarter pound of washing soda to twenty gallons of water), etc.

URTICARIA PIGMENTOSA.

Synonym.—Xanthelasmoidea.

Definition.—Urticaria pigmentosa is an inflammatory affection of the skin, beginning usually in the first six months of infancy, and characterized by buff-colored, wheal-like nodules, with or without itching.

Symptoms.—The eruption is most abundant upon the neck and trunk. It consists of yellowish-red, split-pea-sized nodules or wheals with pinkish areolæ. The nodules later become yellow, and may remain stationary for months. Some undergo involution, leaving brownish stains after them. Itching is often severe, but may be moderate or entirely absent. The disease is very rare.

Prognosis.—The affection usually gets well at or before puberty.

Treatment.—Locally, antipruritic applications. Internal treatment to be based upon general indications.

ANGIONEUROTIC EDEMA.

Synonyms.—Acute circumscribed edema, Quincke's disease, giant swelling.

Definition.—A neurosis, characterized by the acute appearance of circumscribed cutaneous swellings, especially of the face and extremities, which tend, after a variable period of existence, to disappear rapidly, without leaving any secondary changes in the skin (Elliot). It may also affect the mucous membranes, possibly even of the stomach and bowels.

The disease is probably a vasomotor neurosis, closely allied to urticaria.

Symptoms.—Sudden onset, with or without malaise and depression. Nose, lips, eyelids or extremities may become tremendously swollen. Burning and itching usually not present.

Prognosis.—Guarded. Recurrences frequent.

Treatment.—Based upon general principles.

ECZEMA.

Derivation.—*Ἐκζέειν*, to boil over.

Synonyms.—Tetter, salt rheum, etc.

Definition.—An acute, subacute or chronic, non-conta-

gious inflammatory disease of the skin, characterized primarily by erythema, vesicles, papules or pustules, and secondarily by scales and crusts, and accompanied by itching and burning.

FIG. 11.—ECZEMA PUSTULOSUM.

Eczema constitutes about thirty per cent. of all skin diseases. It is met with at all ages and in all conditions of life. It may therefore be said to be the most important of all dermatoses.

ymptoms.—There are four elementary types of eczema: *ma erythematosum, eczema papulosum, eczema vesiculo-*, and *eczema pustulosum.* These may remain as such oughout their entire course, or may merely represent ges in the development of an *eczema rubrum* or *eczema amosum.*

1 Eczema Erythematosum.

This variety of eczema is encountered most frequently pon the face, the arms and the genitalia, but may occur upon ny portion of the cutaneous surface. It begins as vaguely lefined bright- or dull-red spots, which soon coalesce and form diffuse areas. The skin is roughened and slightly infiltrated. When the region about the eyes is involved there is marked edema, which results in an entire closing of the lids. The eruption is accompanied by considerable heat and itching. Convalescence is indicated by a fading of the color, by a branny desquamation, and the occurrence of islets of sound skin. This form of eczema usually runs a chronic course with a marked tendency to recurrence. It may remain erythematous or develop into a squamous eczema, or into eczema rubrum.

Dig. Alumni Bestat. 108
Thus letter by Isaac Dole.

2 Eczema Papulosum.

Papular eczema involves with predilection the arms and legs. It is characterized by pin-head-sized, round or acuminate, reddish elevations, either discrete or closely aggregated. They are often surmounted by minute vesicles. The papules are intensely itchy—a fact which is evidenced by their abraded summits and by the scratch-marks. The eruption tends to relapse, and is obstinately refractory to treatment.

3 Eczema Vesiculosum.

The onset of a vesicular eczema is heralded by tingling and a feeling of heat. Soon there develop upon an erythematous

and swollen base numerous pin-head-sized vesicles, which rapidly become confluent and rupture, permitting the escape of a viscid and sticky serum. The drying of this exudation produces yellow, gummy crusts. The rupture of the vesicles

FIG. 12.—VESICULO-SQUAMOUS ECZEMA OF TOES AND FOOT.

is followed by an abatement of the subjective phenomena. Beneath the crusts the serous exudation continues. The body-linen is stained and stiffened by this constant oozing or weeping.

The course is chronic, with tendency to recurrence. Convalescence begins with a cessation of the serous discharge.

The eruption is common upon the faces of infants, in which locality it has been designated *milk crust* by the older writers.

Vesicular eczema is very apt to terminate in an eczema rubrum.

4 ECZEMA PUSTULOSUM (*Eczema Impetiginosum*).

Pustular eczema may begin as such or may develop from the vesicular variety. It occurs most commonly upon the face and scalp of strumous and poorly nourished children. Rupture of the pustules is followed by the formation of profuse yellowish, brownish or greenish crusts. The itching is less than in the other forms of eczema.

5 ECZEMA RUBRUM.

Eczema rubrum represents a later stage of one of the elementary varieties of eczema. It is characterized by redness, swelling, infiltration, and moisture, and is usually attended with much burning. The epithelial covering of the cuticle is lost. Profuse crusting results from the drying of the exudation. When it presents a raw, weeping surface it is designated *eczema madidans*. It is most frequently situated upon the legs of adults and the faces of infants.

6 ECZEMA SQUAMOSUM.

This is the terminal stage of the above-mentioned types of eczema. In it a regeneration of the corneous layer of the epidermis takes place. It is characterized by redness, infiltration, and desquamation. It is often associated with the erythematous variety. In the neighborhood of joints the thickened skin is apt to become fissured. Some writers include

under the name of squamous eczema the horny variety commonly seen on the hands and feet.

Other secondary varieties of eczema are:

Eczema Fissum.

Characterized by the occurrence of fissures or cracks during the course of an erythematous or squamous eczema: Usually seated upon the face and hands. Aggravated in cold weather. *Chapping* is a familiar example of a mild form of this affection.

Eczema Sclerosum.

Characterized by a leathery infiltration, sometimes board-like in character. This is the most chronic and least inflammatory variety of eczema.

Eczema Verrucosum.

Characterized by watery excrescences upon an eczematous surface, due to hypertrophy of the papillæ. Often there is a foul-smelling discharge.

Eczema Papillomatosum.

Characterized by a papillary hypertrophy greater in degree than the verrucose variety.

Eczema is also designated as *acute* and *chronic*. These terms refer not only to duration, but also to the intensity of the inflammatory process. An eczema may last a long time and yet be acute in character. Infiltration is the chief characteristic of a chronic eczema.

Etiology.—The causes of eczema are both *internal* and *external*. *Internal* causes include in their category: Disorders of the alimentary canal (dyspepsia, constipation, intestinal auto-infection, etc.), functional and organic nerve affections, general debility, rheu[illegible]id diathesis,

Bright's disease, diabetes, affections of the uterus and appendages, dentition, and scrofula. These may at times act as predisposing causes, at other times as exciting causes.

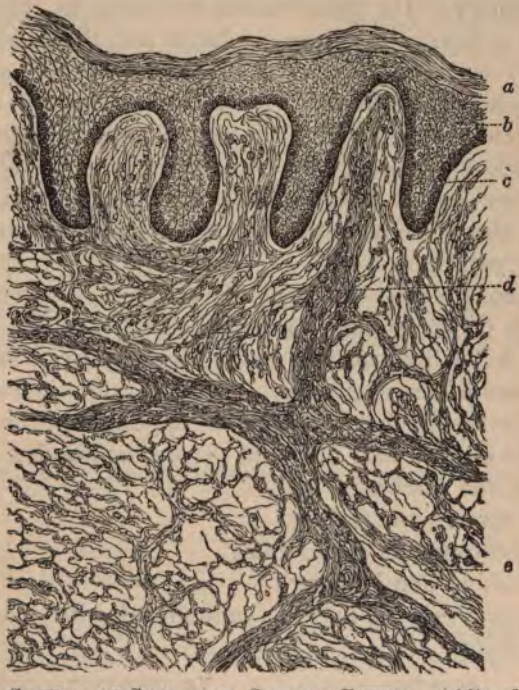

FIG. 13.—SECTION OF SKIN FROM CHRONIC ECZEMA.—(*After Neumann.*) *a.* Epidermis. *b.* Rete Malpighii. *c.* Pigmented cells and enlarged papillæ. *d.* Cellular hyperplasia around blood-vessels. *e.* Diffuse cell infiltration.

The number of *external* causes is legion. They may be classified as follows:

1. Chemical irritants—acids, strong soaps (containing excess of alkali), dye-stuffs, etc.

2. Thermal irritants—solar or artificial heat, cold (particularly when associated with wet), etc.

under the name of squamous eczema the horny variety commonly seen on the hands and feet.

Other secondary varieties of eczema are:

Eczema Fissum.

Characterized by the occurrence of fissures or cracks during the course of an erythematous or squamous eczema: Usually seated upon the face and hands. Aggravated in cold weather. *Chapping* is a familiar example of a mild form of this affection.

Eczema Sclerosum.

Characterized by a leathery infiltration, sometimes board-like in character. This is the most chronic and least inflammatory variety of eczema.

Eczema Verrucosum.

Characterized by watery excrescences upon an eczematous surface, due to hypertrophy of the papillæ. Often there is a foul smelling discharge.

Eczema Papillomatosum.

Characterized by a papillary hypertrophy greater in degree than the verrucose variety.

Eczema is also designated as *acute* and *chronic*. These terms refer not only to duration, but also to the intensity of the inflammatory process. An eczema may last a long time and yet be acute in character. Infiltration is the chief characteristic of a chronic eczema.

Etiology.—The causes of eczema are both *internal* and *external*. *Internal* causes include in their category: Disorders of the alimentary canal (dyspepsia, constipation, intestinal auto-infection, etc.), functional and organic nerve affections, general debility, rheumatism, uric-acid diathesis,

Bright's disease, diabetes, affections of the uterus and appendages, dentition, and scrofula. These may at times act as predisposing causes, at other times as exciting causes.



FIG. 12.—[illegible] (After [illegible].) a. Epidermis. b. Rete Malpighii. c. Pigmented cells and enlarged papillæ. d. Cellular hypertrophy around blood-vessels. e. Diffuse cell infiltration.

The number of *external* causes is legion. They may be classified as follows:

1. Chemical irritants—*acids, strong soaps* (containing excess of alkali), *dye-stuffs, etc.*

2. Thermal irritants—*solar* or artificial heat, cold (particularly when associated with wet), etc.

3. Mechanical irritants—friction of skin surfaces or of clothes, pressure, animal parasites, scratching, etc. In a predisposed individual, the application of any of the above irritants may be sufficient to call forth an eczema.

Pathology.—The blood-vessels are markedly dilated, and there is a fluid and cellular exudation into the tissues. The papillary layer of the corium is swollen and the seat of a round-cell infiltration. When vesicles are formed, the cells of the rete are flattened as a result of pressure; the roof of the vesicle is formed by the corneous layer of the epidermis. In chronic eczema the cell infiltration extends deep into the corium, almost to the subcutaneous tissue, and the papillæ become hypertrophied.

Diagnosis.—The diagnosis of eczema is, as a rule, easy, although it may at times present difficulties.

The following cardinal characteristics are common to most cases of eczema:

1. Erythema, due to exudative congestion of the skin.
2. Exudation into the skin, producing papules, vesicles, pustules and discharge.
3. Crusting and scaling.
4. Infiltration and thickening.
5. Itching and burning.

Vesicular eczema may be confounded with *scabies* and *herpes zoster*.

SCABIES.	VESICULO-PUSTULAR ECZEMA.
1. Characteristic distribution: webs of fingers, flexor surface of arms, axillary folds, nipples, umbilicus, penis, buttocks, and inside of thighs and legs.	1. No characteristic distribution.
2. Presence of burrows.	2. Absence of burrows.
3. Presence of itch-mite.	3. Absence of itch-mite.
4. Itching much worse at night.	4. Itching variable.
5. Communicable.	5. Not communicable.

6. Except in children, face is exempt.	6. Face frequently involved.
7. Treatment rapidly effective.	7. More refractory to treatment.
8. Other members of family often affected.	8. Not the case.

HERPES ZOSTER.	VESICULAR ECZEMA.
1. Special distribution—follows lines of nerves.	1. No special distribution.
2. Eruption often preceded by intense neuralgic pain.	2. Itching and burning attend outbreak of eruption.
3. Vesicles arranged in separate groups.	3. No definite arrangement.
4. Vesicles discrete and distinct.	4. Generally confluent.
5. Vesicles large and tense.	5. Vesicles small and flaccid.
6. Vesicles do not rupture spontaneously.	6. Vesicles tend to rupture.
7. Eruption unilateral.	7. Usually symmetric.
8. Severe shooting pains during course of affection.	8. Variable amount of itching and burning.
9. Tends toward spontaneous recovery.	9. Remains stationary or progresses.

Pustular eczema may be mistaken for impetigo contagiosa and sycosis.

IMPETIGO CONTAGIOSA.	PUSTULAR ECZEMA.
1. Contagious; may occur in epidemics.	1. Not contagious.
2. Begins as blebs or vesicles.	2. Begins as pustules or vesicles.
3. Lesions are discrete.	3. Tend to form patches.
4. Lesions very superficial.	4. Lesions deeper.
5. Surrounding skin not inflammatory.	5. Inflammatory areola.
6. Crusts flat and loosely attached—look as if "stuck on."	6. Crusts profuse and firmly attached.
7. Itching slight or absent.	7. Itching more severe.
8. Curable in one or two weeks.	8. More refractory to treatment.

SYCOSIS.	PUSTULAR ECZEMA.
1. Confined to bearded region.	1. Involves other portions of face.

2. Begins in the hair-follicles.	2. Begins superficially. Involves hair-follicles secondarily.
3. Interfollicular skin free.	3. Skin uniformly involved.
4. Slight itching or burning.	4. Itching more marked.
5. Tendency to recur after cured.	5. Usually remains well after cured.

Eczema erythematosum may be mistaken for erysipelas.

ERYSIPELAS.	ECZEMA ERYTHEMATOSUM.
1. Sudden onset with chill and marked constitutional symptoms.	1. No constitutional symptoms.
2. Eruption sharply marginated.	2. Fades into surrounding skin.
3. Glazed, shining surface; great edema.	3. Dull, scaly surface; slight infiltration.
4. Color violaceous.	4. Color bright or dull red.
5. Burning pain.	5. Itching more marked.
6. Occurrence of discrete vesicles or blebs.	6. Vesicles occur in patches if at all.
7. Progressive peripheral spreading.	7. Spreading irregular.
8. Runs an acute course.	8. Runs a chronic course.
9. Contagious.	9. Not contagious.

Eczema squamosum may be confounded with psoriasis and ringworm.

PSORIASIS.	ECZEMA SQUAMOSUM.
1. Predilection for elbows, knees and scalp.	1. No seat of predilection.
2. Patches small, round, and sharply marginated.	2. Patches large, irregular, and ill-defined.
3. Scales abundant, firmly attached, and mother-of-pearl in color.	3. Scales scanty, loosely attached and grayish or yellowish in color.
4. Moisture never present.	4. Often history of antecedent moisture.
5. Itching slight, often absent.	5. Itching marked.
6. Disease often lasts with recurrent attacks, throughout a lifetime.	6. More amenable to treatment.

Tinea Circinata (Ringworm).	Eczema Squamosum.
1. Contagious.	1. Noncontagious.
2. Patches circular.	2. Patches usually irregular.
3. Patches marginated.	3. Patches usually ill defined.
4. Patches ring-shaped; clear in center.	4. Patches not clear in center.
5. Eruption proceeds with uniform peripheral extension and central healing.	5. Irregular extension and healing.
6. Tricophyton fungus in scales.	6. Scales free from fungus.

Prognosis.—Eczema very often runs a chronic course. If untreated it may continue indefinitely. Nearly all cases will yield, however, to judicious and persevering treatment. Factors influencing the prognosis are:

(*a*) Type of the disease.
(*b*) Duration and extent of the eruption.
(*c*) History of previous attacks.
(*d*) Removability of the cause or causes.
(*e*) Ability of the patient to properly care for himself.

Treatment.—The treatment of eczema is both internal and external. Unfortunately there are no specifics. Internal treatment must be based upon broad general principles. The first therapeutic endeavor should be directed toward the removal of the cause; this, however, is not always easy to ascertain.

Diet.—The diet in all cases of extensive eczema should be carefully regulated. Such articles as salted meats, pork, shellfish, sugar, pastries, confections, pickles, sauces, condiments, cheese, and excess of starchy foods should be assiduously avoided. Tea and coffee should be reduced to a minimum and alcoholic beverages entirely prohibited.

Laxatives.—Laxatives are frequently necessary to keep the bowels in proper order. This is a matter of great importance.

In acute eczema it is desirable to inaugurate the treatment

with free catharsis. This is best done by means of the salines, either alone or preceded by calomel.

A very useful preparation in the treatment of eczema complicated by constipation and anemia is the "acid mixture of iron." It combines the advantages of a tonic and laxative:

℞. Ferri sulphatis, ... gr. xxxvj
Magnesii sulphatis, ... ℥iss
Acidi sulphurici dil., ... f ʒij
Tr. cardamoni comp., ... f ℥iij
Aquæ, ... q. s. ad . . f ℥vj. M.
SIG.—Tablespoonful in a tumbler of water before breakfast.

A more palatable mixture having much the same effect save that its laxative properties are less marked, consists of the following:

℞. Strychniæ phosphatis, ... gr. j
Ferri phosphatis, ... gr. xlviij—lxxij
Sodii phosphatis, ... ℥j
Syrupi aurantii,
Aquæ, . . . āā q. s. ad . . f ℥vj M.
SIG.—Two fluidrams in water before meals.

The saline waters, of which "Hunyadi Janos" is the best, are both efficient and convenient of administration.

In infantile eczema Van Harlingen recommends the following:

℞. Pulv. rhei,
Sodii bicarb., ... āā ʒj-iij
Aq. menth. pip., ... f ℥iv. M.
SIG.—Teaspoonful in water after meals.

Or Elliot's formula may be employed:

℞. Hydrargyri chloridi mitis, . . . gr. $^1/_{100}$
Ol. ricini,
Mist. cretæ,
Aquæ, ... āā ♏xv.

Stomachic Tonics and Digestives.—Stomachic tonics and digestives are required in many cases of eczema. The following formula is useful in cases suffering from atonic dyspepsia and constipation:

℞. Tr. nucis. vomicæ,
Acidi hydrochlorici dil., . . āā f℥ss
Ext. cascaræ sagradæ fld.,
Tr. cardamoni comp., . āā q. s. ad f℥iij. M.
Sig.—One fluidram in water after meals.

Diuretics.—Diuretics are often of value both in acute and subacute eczema. The acetate, citrate, and bicarbonate of potassium, in ten- to twenty-grain doses, may be given one-half hour before meals, or the alkaline mineral waters may be employed.

Alteratives.—Arsenic has but a limited field of usefulness in the treatment of eczema. It is of most value in the chronic papular and squamous varieties and in the recurrent vesicular eczemas involving the fingers. It is contraindicated in acute eczema and whenever the degree of inflammation is high.

Small doses of corrosive sublimate are sometimes of value in certain chronic thickened eczemas (Duhring).

The wine of antimony is often given with good results in the treatment of acute eczema in plethoric individuals.

Tonics.—In strumous individuals with glandular enlargement *cod-liver oil* is a remedy of the greatest efficacy. In anemic and chlorotic patients, iron in the form of the tincture of the chlorid is extremely useful.

Strychnin and quinin are at times employed with great benefit in eczema.

Local Treatment.—The local treatment of eczema is perhaps the more important in the majority of cases. The selection of remedies and their strengths must be governed by the grade of inflammatory reaction present. In an acute eczema the remedies cannot be too soothing. Too strong an application works immediate injury; too weak an application can do no worse than fail to do good.

Water is an irritant in all acute and subacute eczemas, and

is to be used as infrequently as is compatible with cleanliness. It may be made less irritant by the addition of bran, starch or borax. In indolent chronic eczemas soap and water are of therapeutic value. They are useful at times also to remove crusts in the acute varieties. It is, however, a better plan to remove crusts by the process of softening. Pieces of flannel soaked in linseed or olive oil kept in contact with crusts for some hours will soften and loosen them; if they are very adherent, a lukewarm starch or flaxseed poultice may be applied. Pastes and salves should likewise be removed from the skin by oily and unguentous substances. Petrolatum (vaselin) or olive oil, and not soap and water, should be employed for this purpose.

Acute Eczema.—At the onset of a vesicular eczema *dusting powders* may be used with advantage. Many substances have been employed for this purpose: wheat starch, cornstarch, rice flour, bismuth subnitrate, talcum, magnesium carbonate (most absorbent), zinc oxide, boric acid, kaolin, etc. The following is a useful combination:

℞. Talci venet.,
Zinci oxidi, ... āā ℥ss
Amyli, ... ℥j.

Or, if a more astringent one is desired:

℞. Bismuth. subnitrat.,
Acidi borici, ... āā ʒij
Amyli, ... ℥ss.

Lotions are of paramount value in moist eczemas. They are, as a rule, borne much better than ointments. The simplest is a saturated solution of boric acid. This has been found to be just as soothing to the skin as it is to mucous membranes. Sopped on every hour in acute eczema, it acts admirably in reducing inflammation. The following formula combines the advantages of a lotion and dusting-powder:

℞. Zinci oxidi, ... ʒiij
Glycerini, ... f ʒj
Aquæ calcis, ... q. s. ad. f ℥vj.
SIG.—Use locally.

The calamin lotion is also a most efficacious application:

℞. Pulv. calaminæ,
Pulv. zinci oxidi, ... āā ʒj-iij
Glycerini, ... f ʒij
Aquæ calcis, ... q. s. ad. f ℥vj.
This leaves a powdery precipitate upon the skin.

A two per cent. aqueous solution of resorcin is a valuable antipruritic and antiphlogistic lotion.

When there is much itching carbolic acid may be added to any of the above washes.

℞. Acidi carbolici. . . . . ♏xxx-fʒj
Acidi borici, ... ʒj
Glycerini, ... f ʒj
Aquæ, ... f ℥vj.

A favorite treatment with many dermatologists is the use of the "lotio nigra" (black wash), either pure or diluted one-half with lime water: This is to be followed by the plain oxid of zinc ointment. The "liquor carbonis detergens" (or tincture of mineral tar),* in the strength of a dram to four ounces, is a most useful application in papular eczema.

The following wash, recommended by Duhring, will often be found grateful:

℞. Ext. grindeliæ robustæ fld, . f ℥ss-ij
Aquæ, ... Oj.

Soothing ointments are frequently employed in acute eczema. Care must be exercised to make them weak and unirritating. Either of the below-appended formulæ may be used with good results:

---

*Tincture soap-bark, ... 9 ozs.
Coal-tar, ... 4 "
Allow to digest for eight days and filter.

℞. Acidi borici, ... gr. xxx
Ung. aquæ rosæ, ... f ℥j.

Or—

℞. Acidi salicylici, ... gr. x
Lassar's paste. { Pulv. amyli, Zinci oxidi, ... āā ʒij Petrolati, ... ℥ss.

A very old and efficient remedy in acute eczema is the diachylon ointment of Hebra. It must be freshly prepared and should be applied upon strips of soft linen:

℞. Olei olivæ, ... f ℥xv
Lithargyri, ... ℥iij-v
Aquæ, q. s.
SIG.—Coq. Ft. ung.

Subacute Eczema.—When the stage of acute inflammation has subsided, more stimulating applications may be used.

Carbolic acid, menthol, and the tar preparations are the most valuable antipruritics. The following formulæ containing carbolic acid are useful in the subacute forms of eczema:

℞. Acidi carbolici, ... gr. x
Pulv. amyli,
Zinci oxidi, ... āā ʒij
Petrolati, ... ℥ss.

Or—

℞. Acidi carbolici, ... gr. x
Hydrargyri chloridi mitis, . . . gr. xv-xxx
Ung. zinci oxidi, ... ℥ij.

Or the following may be employed:

℞. Resorcini, ... gr. xv
Menthol, ... gr. v-x
Ung. zinci oxidi, ... ℥j.

The annexed formula is particularly useful in squamous eczema:

℞. Acidi calicylici, ... gr. xx
Lanolini,
Petrolati, ... āā ℥ss.

Chronic Eczema.—In this form of eczema strong applications are required to promote absorption of the infiltrate. Here the tar preparations find their greatest field of usefulness. They are never to be used in acute eczema, and only with caution in the subacute form. Tar is of great value in relieving the itching of obstinate papular eczemas. It may be incorporated in ointments, lotions or paints:

℞. Ol. cadini or ung. picis liq., . . ℥j-ij
Ung. zinci oxidi, ... ℥j.

The "liquor picis alkalinus" is an excellent remedy in sluggish and thickened eczemas:

℞. Picis liquidæ, ... ℥ij
Potassæ causticæ, ... ℥j
Aquæ, ... ℥v.

Dissolve the potash in water and add slowly to the tar in a mortar with friction. To be diluted twenty times or more.

In recurrent papular eczemas the following is to be highly recommended:

℞. Ol. cadini, ... f ʒj
Collodii (flexible), ... f ℥j.

In leathery patches the pure oil of cade may be rubbed in with excellent results.

In pustular eczema the preparations of mercury are particularly valuable:

℞. Hydrargyri ammoniat., . . . gr. x-xxx
Ung. zinci oxidi, ... ℥j.

For squamous and sclerous eczemas of the hands, nothing equals a ten to twenty-five per cent. plaster of salicylic acid.

An application much employed in Europe is the glycogelatin fixed dressing of Unna. It is made up of

Gelatin, ...	15 parts	
Glycerin, ...	15 " — aa	30
Oxid of zinc, ...	30 "	40
Water, ...	40 "	100

e

To the above may be added five per cent. of ichthyol or two per cent. of salicylic or carbolic acid. At the temperature of the air this combination has the consistence of a firm jelly, which is heated upon a water-bath (a double boiler is a handy receptacle for it) until it can be easily poured. It is then painted upon the skin and the part covered with a thin layer of absorbent cotton. This becomes quite dry in about ten minutes, when the excess of cotton may be stripped off. A firm impermeable covering is thus formed. It relieves itching admirably, probably by excluding the air. It is of particular value in subacute eczema.

In chronic circumscribed sluggish eczemas of the leg, when other remedies fail, the soft-soap and diachylon treatment may be tried. This consists in briskly rubbing the leg with soft-soap and subduing the reactive congestion by diachylon ointment applied upon strips of linen.

In addition to the above-mentioned local measures used in the treatment of eczema, *baths* are sometimes resorted to. The most frequently employed medicated baths are those containing starch, soda, borax, or bran.

DERMATITIS SEBORRHOICA—ECZEMA SEBORRHOICUM.

Synonyms.—Seborrheic eczema; seborrhœa corporis.

Definition.—Dermatitis seborrhoica is an inflammatory disease of the skin, beginning usually upon the scalp, and characterized by scaliness, redness and fatty hypersecretion, with a tendency to downward extension.

Symptoms.—The disease almost invariably begins upon the scalp, to which it may remain limited or spread to adjacent parts. It is characterized by the formation of branny, grayish-yellow, dry or greasy scales situated upon a diffusely reddened base. In other cases there are circumscribed patches of yellowish-red color, covered with greasy scales or

FIG. 14.—SEBORRHEIC DERMATITIS (SEBORRHŒA CORPORIS OF DUHRING).

crusts. These are most apt to appear upon the hairy border of the forehead, the eyebrows, mustache, beard, and in the nasolabial fold.

The sternal and interscapular regions are the favorite seats of the papular variety. This occurs as circinate or crescentic yellowish-red, elevated, slightly scaly patches (seborrhea corporis of Duhring).

The subjective symptoms in seborrheic dermatitis are slight or absent.

The course is at times acute, but is more apt to run over a considerable period of time.

Etiology.—The disease is perhaps transmitted by contagion. Factors which produce systemic depression favor the development of the disease.

Pathology.—A perivascular round-cell infiltration is observed even in mild cases. In the more severe ones the entire cutis is the seat of such infiltration. The sebaceous and sudoriparous glands do not seem to be involved, at least primarily so.

A specific micrococcus is held by some accountable for the disease.

Diagnosis.—The disease is to be differentiated from pityriasis rosea, eczema and psoriasis. The primary involvement of the scalp and extension therefrom, the superficial seat of the lesions, the yellowish-red color, the tendency to the formation of circinate and crescentic patches, the greasy scales and crusts and the slight amount of itching will serve to distinguish this affection.

Prognosis.—The prognosis is favorable, although relapses are not uncommon.

Treatment.—Any discoverable deviation from health should receive appropriate treatment. Sulphur, salicylic acid and resorcin are the most useful local remedies. Upon the scalp lotions and ointments may be employed either alone or

upon alternate nights. The following lotion frequently brings about a satisfactory improvement:

℞. Resorcini, ... ʒij
Olei Ricini, ... f ʒj
Spts. Vini Recti, ... f ℥vj.
Sig.—Apply each night.

Where an ointment and lotion are both used upon the scalp, it will be well to omit the oil from the lotion. I have often seen excellent results from the alternate use of the resorcin alcohol and an ointment containing

℞. Sulph. Praecip., ... ʒj
Adipis, ... ℥j
Olei Bergomott, ... ♏xxx
Sig.—Apply every second night, rubbing well into the scalp.

IMPETIGO CONTAGIOSA.

Derivation.—*Impetere*, to attack.

Definition.—Impetigo contagiosa is an acute, contagious, inflammatory disease of the skin, characterized by discrete, flat, superficial vesicles or blebs, which rapidly become pustular and dry upon the skin as thin crusts.

Symptoms.—The eruption is most common upon the face and hands. The lesions begin as flat vesicles or blebs, which in the course of twenty-four hours, become vesico-pustular or pustular. Rupture soon occurs, the exudate drying upon the skin as thin, wafer-like crusts, which appear to be "stuck on." The edges of the crusts become detached, curl up, and the crusts drop off, exposing to view reddish spots, which soon fade. The lesions at times show a tendency to umbilication. A coalescence of neighboring pustules may occur, leading to the formation of patches of considerable size. In severe cases there may be slight febrile disturbance. Itching is slight or absent.

Occasionally the eruption takes on a circinate form. A striking and unique example is pictured in the accompany-

FIG. 15.—IMPETIGO CONTAGIOSA.

ing photograph (Fig. 16). There are several typical lesions upon the face.

FIG. 16.—ANNULAR AND SERPIGINOUS TYPE OF IMPETIGO CONTAGIOSA.—A rare form.

Impetigo simplex is a name given by Duhring to a form of impetigo that differs from the usual type in that the lesions are primarily pustules, have thick walls, are globular and do

FIG. 17.—BULLOUS TYPE OF IMPETIGO CONTAGIOSA.

not tend to rupture, coalescence or umbilication. This form is said to be noncontagious.

Etiology.—The affection is commonly seen in poor children. It is apt to accompany pediculosis capitis, as the result of scratching. Epidemics of contagious impetigo are not uncommon in institutions for children. Barber shop transmission is a fertile source of the disease in men.

Pathology.—The affection is caused by inoculation with micro-organisms closely resembling the staphylococcus pyogenes aureus.

Diagnosis.—The chief characteristics are the discreteness, superficiality and auto-inoculability of the lesions.

Prognosis.—The affection may be cured in a week or ten days, or, indeed, may get well spontaneously.

Treatment.—The crusts are removed with soap and warm water, after which the following ointment may be used:

℞. Hydrarg. ammoniat., ... gr. x
Petrolati, ... ℥j.

In order to prevent auto-inoculation a lotion of the bichlorid of mercury such as the following may be frequently sopped upon the affected skin and the adjacent areas:

℞. Hydrargyri chloridi corrosivi, . . gr. j
Glycerini, ... f ʒj
Aquæ, ... q. s. ad . . f ℥vi.

IMPETIGO HERPETIFORMIS.

Definition.—An inflammatory disease of the skin characterized by the appearance of miliary pustules arranged annularly or in clusters, attended by constitutional disturbances, occurring usually in puerperal women, and generally fatal.

Symptoms.—The lesions are small, superficial pustules, which come out in successive crops and are arranged in groups which heal in the center and spread by peripheral ex-

disease of the skin, characterized by grouped erythematous, papular, vesicular, pustular, and bullous lesions occurring in varied combinations, accompanied by burning and itching, and running a chronic course with remissions.

Symptoms.—In severe cases there are elevation of temperature, malaise, chilliness, etc. The eruption may appear gradually or suddenly.

The erythematous, vesicular, bullous, pustular, and multiform eruptions are the common varieties of the disease. There is a distinct tendency for one variety to pass into another variety—for instance, for the vesicular to become pustular or bullous, or the reverse. Burning and itching are practically always present, and in some cases are intense.

Erythematous Variety.—This form occurs in marginate patches or diffuse efflorescenses resembling erythema multiforme. Urticaria-like edematous infiltrations may also occur. The color may be raspberry-red, mottled and tinged with yellowish, brownish, or variegated, with later a variable degree of pigmentation. Erythemato-papular and vesicular lesions often coexist. Itching and burning are marked.

Vesicular Variety.—This is the most common form. It is marked by pinhead- to pea-sized flat or raised, irregularly shaped or stellate, distended vesicles, frequently without an inflammatory areola. They are usually aggregated in clusters of three or four lesions. They tend often to coalescence, but not to rupture. Itching is severe, often intense, but abates considerably upon rupture or laceration of the vesicles. The eruption comes out in crops, which often succeed each other with great rapidity.

Bullous Variety.—The lesions consist of distended, irregular-shaped, angular bullæ, occurring in groups of three or more, often without areolæ. Small pustules frequently appear in the neighborhood, and erythematous and vesicular lesions may likewise be present. Itching and burning are severe.

Pustular Variety.—Two kinds of pustules appear: the one small (miliary), pinpoint- to pinhead-sized and perfectly flat; the other large, elevated, rounded or acuminated, and situated upon an inflammatory base. There is a tendency to arrangement in clusters of three or four. Vesicles and blebs may complicate the eruption, although the pustular type often remains as such, even throughout successive outbreaks.

Papular Variety.—Rare. It is the mildest expression of the disease. More commonly, papulovesicles resembling an abortive herpes zoster develop.

Multiform Variety.—This is a polymorphous form in which erythematous patches, papules, vesicles, blebs, pustules, and pigmentation in various combinations are commingled.

The course of dermatitis herpetiformis is variable, but in nearly all cases is eminently chronic, lasting for years in the form of relapses, or, indeed, at times continuously.

Etiology.—The disease occurs most often between the ages of thirty and sixty. It is due to various causes, among which may be mentioned physical and psychical shock, pregnancy, disordered menstruation, puerperal septicemia, and renal insufficiency; the nervous system, however, is directly responsible for the cutaneous manifestations. There is in most cases a lowering of the general nerve-tone.

Pathology.—There is an acute inflammation of the papillary layer of the corium, with the formation of vesicles between the corium and epidermis and the exudation of large numbers of polymorphonuclear leukocytes and eosinophiles. The epidermis is but secondarily involved.

Diagnosis.—The polymorphism and herpetiformity of the eruption, the intense itching, and the history, course, and chronicity of the disease will enable one to distinguish it from pemphigus, erythema multiforme, and impetigo herpetiformis—diseases which it at times closely resembles.

The vesicles and blebs of dermatitis herpetiformis are peculiar in that they are often of marked irregular outline—sometimes stellate, quadrate, or oblong, etc. In drying they are apt to present a puckered appearance.

They are *herpetiform* in that they occur in groups, have inflammatory bases, and do not tend to spontaneous rupture, resembling in these respects the lesions of herpes zoster.

Prognosis.—Guarded. The disease is persistent and refractory to treatment. In addition, there is a strong tendency to recurrence. In rare cases the pustular or bullous type may prove fatal.

Treatment.—The first effort should be directed toward the removal or modification of the underlying cause, if ascertainable. The nervous system is in most cases at fault, and remedies should be administered with a view of restoring the normal nerve-tone. There are no specifics, but arsenic often acts in a gratifying manner. It should be given in ascending doses by mouth if well borne; if not, hypodermically until an impression is made upon the disease or upon the patient. In other cases, however, it is of no value. Phenacetin, cannabis indica, and belladonna may be tried, and such tonics as quinin, strychnin, and iron are sometimes of value.

Local Treatment.—Blebs should be incised or punctured and the contents evacuated. Lotions containing tar, carbolic acid, ichthyol, and resorcin are useful. These may be followed by an ointment of salicylic acid. Duhring advises in the vesicular and pustular forms (particularly the chronic) the use of a strong sulphur ointment, well rubbed in.

PEMPHIGUS.

Derivation.—*Πέμφιξ*, a blister.

Definition.—Pemphigus is an acute or chronic inflammatory disease of the skin, characterized by the formation of successive crops of variously sized, rounded or oval bullæ,

affecting seriously the general health and often terminating fatally.

Symptoms.—There are two principal types—pemphigus vulgaris and pemphigus foliaceus.

Pemphigus Vulgaris.—With or without febrile disturbance, there appear upon the limbs, face or trunk, pea- to egg-sized, rounded or oval tense blebs. They rise abruptly from the normal skin, and, while having at times a slightly reddened base, have no areola. The contained fluid is at first serous, later becoming turbid and purulent. The eruption occurs in crops, a half-dozen or more blebs appearing at a time. These persist for a few days (the fluid disappearing by absorption or rupture), and are then followed by another crop.

The parts most often affected are, in their order of frequency, the limbs, the face, and the trunk. The mouth, vagina, conjunctiva, and other mucous membranes may become involved.

The disease in some cases runs a more or less *acute* course, getting well in a few months. Far more frequently, however, it persists for years, greatly impairing the general health.

Pemphigus Foliaceus.—In this form the blebs, which are *flaccid* and purulent, rupture before distention and dry to crusts, which are thrown off with the surrounding epidermis, exposing to view the reddened corium. A new crop of blebs succeeds the old, often developing upon the same site, and giving to the skin the appearance of a severe scald. The entire cutaneous surface may thus become involved, and the general health seriously compromised. The process lasts for months or years, and almost always leads to a fatal termination.

Neumann has described a rare form of pemphigus characterized by the development of wart-like or papillary vege-

tations upon the sites of ruptured bullæ. This form he has called *pemphigus vegetans.* The mouth, vagina or other mucous membranes are often first affected. The favorite situations upon the skin are the genital and annal regions, the neck, axillæ, and flexures of the extremities. The affection lasts months or years, and tends to a fatal termination. The *subjective* phenomena in pemphigus are itching and burning (usually moderate in degree), and often tenderness, pain, and a feeling of tension. The disease is distinctly rare, particularly in this country.

Etiology.—Obscure. The disease has been observed in many cases in which marked changes in the central and peripheral nervous systems were noted. In addition, mental strain, nervous exhaustion, and a lowered or vitiated state of the general health are considered to be causative.

Pathology.—The blebs are usually situated between the horny layer and the rete mucosum, but may occur at any depth in the epidermis. The contents of the bullæ consist of a slightly alkaline serum containing a few leukocytes. There is dilatation of the papillary vessels and a leukocytic infiltration of the papillæ, corium, and subcutaneous tissue.

The affection is looked upon as a trophoneurosis.

Diagnosis.—It should be remembered that all bullous eruptions are not pemphigus. Care should be exercised to differentiate the bullous forms of erythema multiforme, dermatitis herpetiformis, impetigo contagiosa, and syphilis (pemphigus syphiliticus of the older writers). The bleb of pemphigus is large, tense, abruptly elevated, noninflammatory, and comes out in crops. These characteristics, with the history and course of the disease, should enable one to make the diagnosis.

Prognosis.—The course of the disease is uncertain. Mild cases may recover after a duration of months. Severe cases (particularly pemphigus foliaceus) are apt to end fatally.

The occurrence of flaccid or hemorrhagic blebs, extensive cutaneous involvement, frequent outbreaks or constitutional depression are all unfavorable signs.

Treatment.—Both internal and local treatment are to be employed, the former alone, however, being curative. Arsenic is by far the most valuable remedy. It is to be perseveringly tried, beginning with small doses and increasing until the physiologic limit is reached. Quinin in full doses is also of value, as are at times iron, strychnin, and cod-liver oil. Nutritious food, good hygiene, and bodily and mental rest are important therapeutic factors.

Local treatment is designed to heal the abraded surfaces and to relieve the subjective symptoms. The blebs should be evacuated, and simple dusting powders, ointments or lotions applied. The calamin lotion is a most grateful application. Bran and starch baths are useful in extensive cases. In pemphigus foliaceus the *continuous* bath is perhaps the best treatment, the patient living day and night, for weeks and months, immersed in water.

POMPHOLYX.

Derivation.—*Πομφόλυξ*, a bubble.

Synonyms.—Cheiropompholyx; dysidrosis.

Definition.—Pompholyx is an acute inflammatory disease of the skin characterized by the development of numerous hard, deep-seated vesicles upon the hands and feet.

Symptoms.—The affection attacks symmetrically the hands and feet, although the latter may escape involvement. When the hands are involved numerous deep-seated, tense vesicles are seen upon the lateral aspects of the fingers and upon the palms. They have been aptly likened to boiled sago grains embedded in the skin. A feeling of heat, burning, tingling or itching is nearly always present. The vesicles

may remain discrete or may coalesce and form bullæ; often the fluid becomes absorbed and the eruption disappears in the course of a few days to a week. In these cases new

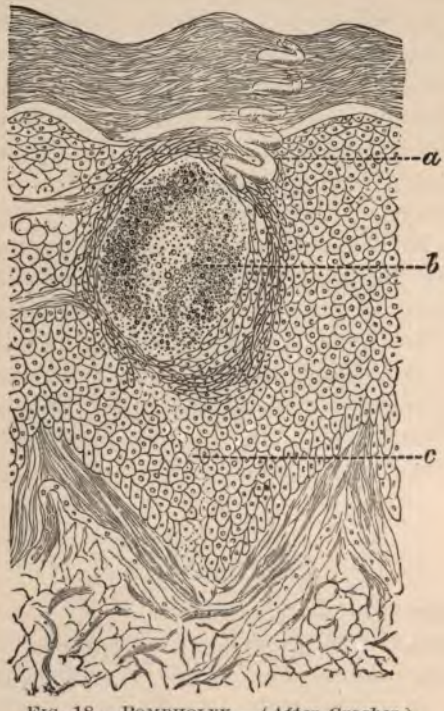

FIG. 18.—POMPHOLYX.—(*After Crocker.*)
b. Vesicle formed in the interpapillary portion of the rete directly in the course of the sweat channel *a* and *c*.

lesions may continue to form, the surrounding skin becoming sodden and painful, and later exfoliating. There is sometimes an accompanying hyperidrosis. Recurrences are quite common, the various attacks differing greatly in intensity. Constitutional manifestations are absent.

Etiology.—The affection occurs in nervous individuals

and those whose nerve-tone is below normal. It is more frequent in women than in men, and is observed chiefly in adult life.

Pathology.—The disease is conceded to be a vasomotor neurosis, but while some authors hold to the view that the affection is primarily one involving the sweat apparatus, others declare its independence of the sweat structures. The vesicles lie in the lower layers of the rete mucosum. Their contents are of neutral or alkaline reaction.

Diagnosis.—From vesicular eczema of the hands pompholyx may be distinguished by the localization of the lesions upon the lateral and palmar surfaces, the hardness of the vesicles, their tendency to persist unruptured, the mild inflammatory signs, the presence of burning rather than itching, and the course of the disease.

Prognosis.—Acute attacks usually subside in a fortnight. Recurrences are extremely common.

Treatment.—Good hygiene and tonics such as quinin, strychnin, iron, and arsenic are of distinct value. Locally, the following may be employed:

℞.	Acidi salicylici, ...	gr. xx
	Acidi borici, ...	gr. xxx
	Pulv. amyli,	
	Zinci oxidi, ...	āā ʒij
	Petrolati, ...	ʒiv.

Instead of this one may use oleate of zinc, saturated solution of boric acid, diachylon ointment, etc.

HERPES SIMPLEX.

Derivation.—*Ἕρπειν*, to creep.

Synonyms.—Fever blisters; "cold sore."

Definition.—Herpes simplex is an acute inflammatory disease of the skin, characterized by the formation of small groups of closely aggregated vesicles upon reddened bases.

Symptoms.—There are two chief varieties, according to

localization—(1) *herpes facialis,* (2) *herpes progenitalis.*

Herpes facialis (herpes febrilis, herpes labialis) has its favorite seat near the oral commissures, where it makes its appearance as closely aggregated pinhead- to pea-sized vesicles, which, through coalescence, often form bullæ. The lesions soon become pustular, rupture, and dry as yellowish or brownish crusts upon the skin. Vesicles sometimes develop upon the mucous membrane of the mouth, where they are called by the laity "canker sores." Herpes runs its course in from five to ten days. Burning and itching are usually present.

Etiology and Pathology.—Herpes facialis is extremely prone to accompany acute diseases, such as pneumonia, cerebro-spinal meningitis, malaria, coryza, and gastric and nervous disturbances. It is due either to a mild toxic neuritis of the cutaneous nerve filaments, or to nerve irritation.

Prognosis.—Favorable. Eruption disappears spontaneously in a week or ten days.

Treatment.—Mild, sedative applications, such as oxid of zinc ointment, cold cream, saturated solution of boric acid, etc., weak solution of sulphate of copper, are all that is necessary. In children, painting with collodion or compound tincture of benzoin protects the part from finger infection.

Herpes progenitalis (herpes preputialis) occurs both in the male and in the female. The groups of vesicles in the former are located upon the inner surface of the prepuce, glans penis, shaft of the penis, etc.; in the female upon the labia minora, labia majora, vestibulum, perineum, etc. In these locations they may, through subsequent infection, become the sites of chancres or chancroids.

Etiology.—A long, narrow prepuce seems to act as a predisposing cause. Unna found herpes progenitalis much more frequent in prostitutes than in the chaste.

Diagnosis.—It is important to differentiate herpes from

the more serious genital sores. It must not be forgotten that the abrasion at the site of a herpetic patch offers an easy ingress for the chancroidal or syphilitic virus.

Prognosis.—Favorable as to immediate attack. Recurrences are extremely common.

Treatment.—Cleanliness must be strictly enjoined. Astringent lotions, such as equal parts of lotio nigra and lime-water, and saturated solution of boric acid, or dusting-powders, such as aristol, calomel, or acetanilid, may be employed. Patients with long prepuces who are subject to frequent attacks had better be circumcised. The long-continued administration of small doses of arsenic has been advised.

HERPES ZOSTER.

Derivation.—*Ἕρπειν*, to creep; *ζωστήρ*, a girdle.

Synonyms.—Shingles; zoster; zona; cingulum.

Definition.—Herpes zoster is an acute inflammatory disease of the skin characterized by the formation of grouped vesicles along the line of a cutaneous nerve, and accompanied by neuralgic pains.

Symptoms.—After prodromal neuralgic pains, more or less severe in character, there appear in crops irregular groups of pinhead- to pea-sized vesicles, which follow in an interrupted manner the distribution of the nerve or nerves affected. When seen early, macules, papules, or vesico-papules may sometimes be distinguished. The vesicles rest upon a highly inflammatory base. The eruption is distinctly *unilateral*, bilateral cases being of great rarity.

In the course of one to two weeks the vesicles, which do not tend to spontaneous rupture, dry upon the skin as yellowish-brown crusts and fall off. As a rule, no permanent trace is left, although in some cases there may be considerable scarring. The vesicles may become pustular, hemorrhagic, or even gangrenous.

The most frequent regions affected are those supplied by the intercostal, lumbar, and trifacial nerves, although any portion of the cutaneous surface may be involved. In *herpes*

FIG. 19.—HERPES ZOSTER SUPRA-ORBITALIS.

zoster ophthalmicus severe destructive inflammation of the cornea, iris, and, indeed, of the entire eye, may occur.

Pain is nearly always present. It may be slight or so severe as to prevent sleep. It is variously described as of a darting, burning, drawing, or tearing character. It may persist

indefinitely after the disappearance of the eruption, and may prove most refractory to treatment.

In severe cases febrile disturbance may be present. Herpes zoster seldom occurs twice in the same individual.

FIG. 20.—HERPES ZOSTER CERVICO-BRACHIALIS.—(*After Van Harlingen.*)

FIG. 21.—HERPES ZOSTER LUMBO-FEMORALIS.—(*After Van Harlingen.*)

Etiology.—Atmospheric changes, exposure to cold and wet, and mechanical violence to nerves (injury, surgical operations, etc.) are all considered causative. The long-continued use of arsenic is said to produce zoster at times. Some authors look upon the disease as a specific infection.

Pathology.—Zoster is due to an irritative or inflammatory

lesion of the central spinal or peripheral nerve apparatus. The process is usually an interstitial descending neuritis of one of the spinal ganglia. There may, however, be merely a simple inflammation of a peripheral nerve.

Diagnosis.—A *unilateral* eruption, consisting of groups of large vesicles upon an erythematous base, following the course of a cutaneous nerve and accompanied by neuritic pains, is characteristic of herpes zoster. The vesicles of zoster differ from those of eczema in being larger and in showing no tendency to rupture spontaneously.

Prognosis.—Favorable. Most cases get well spontaneously in one to three weeks. It should not be forgotten that some cases are followed by persistent neuralgia, and that others may lead to scarring or, in the case of the ophthalmic form, to serious impairment or loss of vision.

Treatment.—*Local treatment* is concerned merely in protecting the parts from injury and infection and, to a certain extent, in the relief of pain. Ordinary dusting-powders, such as oxid of zinc, starch, talcum, etc., may be employed, or if there is much pain, morphin and camphor may be added:

℞. Morph. sulph., ... gr. v
Pulv. camphor., ... gr. xx
Pulv. zinci oxidi, ... ℥j.

Sig.—Dust on the affected area, cover with cotton, and bandage.

The calamine lotion is often a grateful application.

An excellent method is to paint the affected areas with collodion containing ichthyol.

℞. Ichthyol, ... f ʒj
Collodii, ... f ℥j.

The galvanic current applied along the nerve often gives marked relief from the pain.

Internal Treatment.—The pain is often so severe as to require the use of an anodyne. The following prescription will be found of service:

℞. Morph. sulph., ... gr. ⅛
Phenacetin, ... gr. ij
Quiniæ sulph., ... gr. j.
SIG.—One capsule every four hours or oftener.

Phosphid of zinc in one-third of a grain doses every three hours is warmly advocated by some. In the neuralgia persisting after the disappearance of the eruption antipyrin, quinin, iron, strychnin, arsenic, and the galvanic current are of value.

LICHEN RUBER.

Derivation.—Λειχνή, a lichen or moss.

Definition.—Lichen ruber is an inflammatory disease characterized by the appearance of small, flat, angular and shining, or discrete, acuminated and scaly, reddish papules, running a chronic course and attended by more or less itching.

Symptoms.—There are two varieties—lichen ruber acuminatus and lichen ruber planus. Some authors regard these forms as distinct diseases.

LICHEN RUBER ACUMINATUS (*Lichen Ruber*).

This is a very rare disease, particularly in America. It is characterized by discrete, millet-seed-sized, acuminated, scaly, reddish papules, which are disseminated over the trunk with no disposition to grouping. After a duration of years the skin may become diffusely infiltrated, reddened, and scaly. There is mild or severe itching present. The disease is extremely chronic, usually compromising the general health and tending ultimately to a fatal termination.

LICHEN RUBER PLANUS (*Lichen Planus*).

Lichen planus is a not uncommon disease. It may develop gradually or rapidly, appearing as pinhead-to pea-sized, flat, quadrangular or polygonal, shining, slightly umbilicated

FIG. 22.—A PAPULE OF LICHEN PLANUS FORMED AROUND A SWEAT-DUCT.—(*After Crocker.*)

papules of a violaceous or reddish color. The lesions may be disseminated, but are more commonly closely aggregated in patches, which assume frequently a linear form. The surface of the papule is at first glazed or shining, later covered with fine whitish scales. The favorite regions are the flexor surfaces of the forearm and wrist and the dorsal surfaces of the feet. When occurring upon the legs, the papules are apt to become confluent, with the formation of elevated plaques of a purplish color. A brownish pigmentation often persists after the disappearance of the lesions.

Itching is, in the majority of cases, a prominent symptom. The general health remains, as a rule, unaffected.

Etiology.—The disease is of neurotic origin. The most common cause is nervous exhaustion resulting from worry, overwork, etc. Digestive disturbances may also be etiologic factors. It is most frequently observed in middle-aged individuals.

Pathology.—The pathologic process in the plane variety consists of a circumscribed lymphoid cell infiltration in the papillary layer of the corium. The papule is usually situated about a sweat-duct although a hair follicle may occupy the center. There is a hypertrophy of the cells of the rete mucosum (acanthosis), followed by epithelial atrophy and colloid degeneration. Hyper keratosis or overgrowth of the horny layer is commonly associated.

Diagnosis.—The characteristic features of the papules of lichen planus are their angularity, flatness, shining surface, violaceous color, and umbilication. These points will differentiate the disease from papular eczema, psoriasis, and the papular syphilide. The papules of eczema are rounded, somewhat acuminate, brighter red in color, and have a different history.

Prognosis.—The prognosis of the acuminate variety is extremely guarded; of the plane variety, favorable.

Treatment.—The treatment is both general and local. Attention to diet and hygiene should not be neglected. Cod-liver oil, iron, strychnin, etc., are often indicated. Arsenic is by far the most valuable remedy, exerting almost a specific influence upon the disease. In some cases, particularly when arsenic fails, mercury acts most favorably.

Locally, applications containing tar, carbolic acid, menthol, salicylic acid, mercury, etc., are to be employed. The following formula, suggested by Unna, may be heartily indorsed:

℞.	Acidi carbolici, ...	gr. x-xx	
	Hydrarg. bichlor., ...	gr. ij-iv	
	Ung. zinci oxidi, ...	℥j.	M.

Sig.—Apply twice a day.

LICHEN SCROFULOSUS.

Definition.—Lichen scrofulosus is a chronic inflammatory disease, characterized by millet-seed-sized, flat, reddish or yellowish, more or less grouped, scaly papules, occurring in scrofulous subjects.

Symptoms.—The disease occurs in young individuals exhibiting other evidences of the scrofulous diathesis. The papules, which are scattered over the chest and abdomen, have their origin in the hair-follicles. They are pinhead-sized, pale-red or yellowish, somewhat scaly, and tend to become aggregated in groups. Itching is absent.

The course of the disease is chronic, lasting for years. The disease is rare.

Treatment.—Cod-liver oil, used both internally and externally, will usually effect a cure.

PRURIGO.

Derivation.—*Prurire,* to itch.

Definition.—Prurigo is an inflammatory disease of the

skin, characterized by the occurrence of pinhead- to lentil-seed-sized pale-red papules, occurring chiefly upon the extensor surfaces of the extremities, beginning in infancy or early childhood, lasting for years or throughout a lifetime, and accompanied by intense itching.

Symptomatology.—According to the severity of the disease, two types are distinguished—*prurigo ferox* (severe prurigo) and *prurigo mitis* (mild prurigo).

The disease usually begins in the first year of life, not infrequently taking the form of an ordinary urticaria. Later, there appear upon the extensor surfaces of the legs and arms, the trunk, and sometimes the forehead, pinhead-sized or larger, discrete, firm papules. These may be pale red or may have the natural color of the skin. The itching is intense, as a result of which the affected areas are covered with excoriations and blood crusts. After a time the skin becomes harsh, dry, greatly thickened, and sometimes pigmented. The neighboring lymphatic glands, particularly those in the inguinal regions, are often so greatly enlarged as to be apparent to the eye.

The disease is extremely rebellious, and may persist for years, or even throughout the entire lifetime of the individual. It is apt to undergo spontaneous improvement in the summer season. Prurigo is distinctly rare, particularly in this country.

Etiology and Pathology.—The disease is engendered by the environment of "misery," poor food, bad hygiene, etc. The pathology does not differ markedly from that of the chronic papular eczema.

Diagnosis.—The localization and character of the papules, the thickened skin, the marked adenopathy, the chronic course, and the history of the disease render the diagnosis easy.

Prognosis.—Severe cases often persist for a lifetime.

Milder cases may, under judicious treatment, be cured. Some cases get spaneously well around the age of puberty.

Treatment.—The therapeutic indications are to relieve the intense itching, to get rid of the eruption, and to improve the general health. Nutritious food and proper hygiene are essentials. Tonics, such as iron, cod-liver oil, and the hypophosphites, are often indicated. Crocker recommends for the relief of the itching the tincture of cannabis indica, beginning with five-minim doses—in a child of eight, for instance—and increasing to the physiologic limit.

Locally, ointments of betanaphthol, sulphur (ʒj to the ounce), and tar are of value.

Kaposi strongly advocates the following:

℞. Betanaphthol, ... gr. x-xxx
Petrolati, ... ℥j.
Sig.—Rub in each night.

Baths are extremely useful, particularly the (1) alkaline bath (sodii bicarb., ℥iv to 30 gallons of water) and (2) the sulphur bath (sulph. præcip. or potass. sulphid, ℥iv to 30 gallons of water).

ACNE.

Derivation.—Ἀκνή, a point.

Synonym.—Acne vulgaris.

Definition.—Acne is an inflammatory disease occurring in and around the sebaceous glands, characterized by papules, tubercles, or pustules, affecting chiefly the face, and running a more or less chronic course.

Acne is an extremely common disease, comprising over seven per cent. of all dermatoses.

Symptoms.—The forehead, cheeks, and chin are the regions usually affected, although the chest, shoulders, and back are not infrequently involved. The lesions are papular, pustular, or nodular, or a combination of these may be pres-

ent. Comedones or blackheads and oily seborrhea often coexist, the former frequently giving rise to acne lesions. The primary manifestations are pinhead- to pea-sized, bright- or dark-red, discrete papules appearing at the orifices of the sebaceous glands and hair-follicles. These vary in number from two or three to several dozen. After a period of a few days or weeks the lesions either become pustular and discharge or undergo absorption, being followed by reddish stains or, in some cases, by scars. A new crop succeeds the old, the affection thus continuing for months or years.

According to the predominating lesions various forms of acne are distinguished.

Acne Punctata

is represented by small conical elevations with central sebaceous openings filled with dark-colored points.

Acne Papulosa

consists of small reddish acuminate papules.

Acne Pustulosa

is characterized by pinhead- to pea-sized pustules resulting from suppuration of the papular lesions.

Acne Indurata

is a pustular acne in which the lesions are large and have markedly infiltrated bases. They are nodular, deep-seated, and often painful. When the inflammatory process involves several adjacent glands, the suppurating lesions may coalesce, forming cherry- to hazel-nut-sized sebaceous abscesses. This condition is shown in the accompanying cut.

Acne Artificialis

is a papular or pustular eruption produced by the internal administration of the iodids and bromids or the external use of tar (*tar acne*).

Acne Cachecticorum

is an acne occurring usually upon the trunk and extremities of strumous and cachectic individuals. The lesions are large, indolent, violaceous, scar-leaving pustules.

The subjective symptoms in acne are extremely mild. Itching and burning are usually absent, but in some cases exist

Fig. 23.—Acne, Comedo, and Sebaceous Abscess.

in a mild degree. The large indurated lesions are often painful, or rather tender to the touch.

The course of acne is chronic, the disease, untreated, tending to last for months and years. In girls periodic aggravation occurs with great constancy either before, during, or

after each menstruation. Spontaneous improvement takes place between the ages of twenty-five and thirty.

Etiology.—Puberty is the most potent predisposing cause, the vast majority of cases of acne occurring between the ages of fifteen and twenty-five; after thirty acne is uncommon. The great glandular activity occurring at puberty is easily subject to pathologic perversion.

Dyspepsia and constipation play an important rôle in the causation of this disease; uterine disease, menstrual irregularity, anemia, and general debility are also provocative in many cases. The bromids, iodids, and tar may call forth an acne.

Pathology.—An acne lesion consists of a perifolliculitis and a folliculitis due to the irritation of retained and decomposed sebum. There is engorgement of the surrounding vessels and an intense cell-infiltration. The process ends in resorption or suppuration, with or without destruction of the follicle.

Diagnosis.—The diagnosis of acne is, as a rule, unattended with difficulty. It may in some cases be confounded with the papular or pustular syphiloderm. Below is appended the differential diagnosis.

ACNE.	PAPULO-PUSTULAR SYPHILODERM.
1. Often associated comedones and oily seborrhea.	1. Concomitant signs of syphilis present.
2. Occurs at age of puberty.	2. Occurs usually later.
3. Usual limitation of lesions to face.	3. Distribution general.
4. Course chronic, with exacerbations.	4. Course acute.
5. Lesions acutely inflammatory.	5. Lesions are new growths.
6. Lesions light- or dark-red.	6. Lesions are brownish-red or ham-colored.
7. No tendency to ulceration.	7. Tendency to ulceration.

Prognosis.—Some cases respond rapidly to treatment; others are refractory. Very few cases are incurable. Success

Express all comedones. Open all closures. Steam face nightly. scrub flesh brush + soap Policy! Sulph 10%

depends upon the detection and removal of the cause. The average case requires months for a cure. Severe cases may be followed by scarring.

Treatment.—Constitutional and local remedies are both of importance—the former to prevent the formation of new lesions and the latter to cause the disappearance of the old.

Constitutional Treatment.—There are no specifics. Treatment must be directed toward the correction of systemic errors.

Dyspepsia and constipation frequently call for treatment. For the former the bitter tonics, mineral acids, and alkalines may be used, according to the exigencies of the case. Constipation may be overcome by diet, abdominal massage, and the various laxatives. A pill of aloin, strychnin, and belladonna, blue mass or calomel, cascara sagrada, the salines, etc.. are all useful.

The following is an admirable combination for coexisting anemia and constipation (Startin):

℞. Ferri sulphat., ... gr. xvj
Magnes, sulphat., ... ℥j
Acidi sulpur. dil., ... f ʒj
Aquæ menth. pip., . . q. s. ad f ℥iv. M.

SIG.—Tablespoonful in a goblet of water a half-hour before breakfast.

A more palatable combination useful in the same class of patients is the following:

℞. Strychniæ phosphat., ... gr. i
Ferri pyrol. phosphat., ... gr. xlviij-lxxij
Sodii phosphat., ... ℥i
Syrupi auranti,
Aquæ, ... āā q. s. ad f ℥vi. M.

SIG.—fʒij in water before meals.

Paste on face ½ hr. for 4 nights.

℞ Naphthol 10
Sulph ppt. 30
Ext Lupulin Liquid 10
Vaseline 10

The laxative mineral waters, such as Hunyadi Janos, Friedrichshall, and Saratoga, may also be employed.

In cases attended with much pustulation, the sulphid of calcium, in one-tenth to one-half-grain doses four times daily

is said to be serviceable, but in my experience has never been productive of results. Ferruginous preparations are of value in cases complicated by chloro-anemia. Cod-liver oil and the hypo-phosphites are indicated in strumous and rachitic patients. Small doses of arsenic, strychnin, and bichlorid of mercury are of value in individuals with lowered nerve-tone.

Hygienic measures such as cold baths, outdoor exercise, and regular life are, of course, not to be neglected.

In many cases dietary restriction is necessary. Highly seasoned foods, pastries, salt meats, and alcoholic beverages are to be avoided.

Local Treatment.—The object of local treatment is to hasten the disappearance of existing lesions and to stimulate the sebaceous glands to healthy action.

The nature of the remedies to be employed depends upon the amount of inflammatory reaction present. In the vast majority of cases stimulating applications are indicated. Occasionally, however, the face is hyperemic and tender and requires the use of sedative lotions and salves.

Before the local remedies are applied the face should be thoroughly washed with soap and hot water, with a view to opening up the follicles. For this purpose ordinary soap may be employed, or in sluggish cases soft soap or the tincture of green soap. This is advantageously followed by mopping the face for five minutes with very hot water. Comedones are to be removed either by pressure of the fingers or the use of the comedo expressor, preferably the latter.

Salves and pastes are most conveniently applied at night. Lotions, used alone or in conjunction with ointments, may be sopped on frequently during the day.

Sulphur is by far the most generally useful and efficient remedy. It may be used in the form of a powder, ointment, paste or lotion. When the lesions are deep-seated and the face dry, ointments are to be preferred; when superficial and the face is oily, lotions are indicated.

The following dusting-powder is useful:

℞. Sulphur. præcip., ... ʒij-℥iv
Amyli, ... ℥ss
Ol. rosæ, ... gtt.iij. M.
SIG.—Dusting powder.

Incorporated in a paste, sulphur may be used as in the following formula:

℞. Sulphur. præcip., ... ʒj-ʒij
Lassar's Paste { Amyli, Zinci oxidi, ... āā ʒij
Petrolati, ... ʒiv. M.
SIG.—Rub in at night.

One of the most eligible and efficient lotions is known as the "compound zinc sulphid lotion." It may be used four or five times a day, and has the advantage that it may be employed upon the face without disfigurement. Its formula is as follows:

℞. Zinci sulphat., ʒss
Potass. sulphid., ... āā ʒj
Aq. rosæ, ... q. s. ad f℥iv.
(The ingredients are to be dissolved separately, heated, and then mixed. A double decomposition takes place, with the precipitation of a whitish powder. The potassium sulphid should always be fresh.)

Another useful formula is that devised by Kummerfeld:

℞. Sulph. præcip., ... ʒiv
Pulv. camphoræ, ... gr. x
Pulv. tragacanth., ... gr. xx
Aq. calcis, ... f℥ij
Aq. rosæ, ... f℥ij

When oily seborrhea coexists, the following may be employed:

℞. Sulph. præcip., ... ʒj
Ætheris, ... fʒiv
Spts. vini rect., ... f℥iijss. M.

The *mercurials* are often serviceable in the treatment of acne. Care must be taken in changing from the sulphur to

the mercurial treatment, or *vice versa,* that there be an intermission of a few days, and that the face be thoroughly cleansed, to avoid the disagreeable though temporary blackish discoloration resulting from the formation of the sulphid of mercury. The following is a much used formula:

℞. Hydrarg. chloridi corrosiv., . . gr. ss-ij
Emuls. amygdal. amar., ... f℥iv
Tr. benzoin. comp., ... f℥j.

Or the ammoniated mercury in ointment form may be used:

℞. Hydrarg. ammoniat., ... gr. xxx-ʒj
Ung. zinci oxidi, ... ℥j.

In addition to the above remedies, resorcin (gr. xx-xl to ℥j), betanaphthol (gr. x-xxx to ℥j), and ichthyol (ʒj-ʒij to ℥j) may all be found useful.

FIG. 24.—KAPOSI ACNE LANCE.

In indurated acne benefit will often accrue from the use of mercurial or ichthyol plaster worn during the night. In obstinate cases incision of the lesions with expression of their contents may be resorted to.

ACNE ROSACEA.

Definition.—Acne rosacea consists of two processes—an acne and a rosacea. The latter is a chronic hyperemic disorder of the face, particularly the nose and cheeks, characterized by redness, dilatation of blood-vessels, and in some cases connective-tissue hypertrophy. The acne lesions are secondary.

Symptoms.—The disease has three stages. In the first stage there is simply a diffuse hyperemia of the part, coming on after meals, after drinking hot beverages, on exposure to

cold or heat, and at the menstrual period. Oily seborrhea is often present. After some months or years the second stage develops. In this the redness is more permanent, being due to enlarged capillaries and venules, which are visible cours-

FIG. 25.—ACNE ROSACEA.

ing through the skin. At the same time papular and pustular acne lesions appear. This is the usual clinical picture of acne rosacea.

In exceptional cases the disease progresses to a third stage, which is characterized by further capillary enlargement, and

hypertrophy of the sebaceous glands and connective tissue. A lobulated or bulbous enlargement of the nose takes place, sometimes reaching the size of a fist (*rhinophyma; acne hypertrophica*).

FIG. 26.—ACNE HYPERTROPHICA.—(*After Van Harlingen.*)

The course of the disease is chronic, lasting over a period of years.

Etiology.—The disease occurs in both sexes, but is usually worse in men. The most frequent causes are chronic gastro-intestinal disturbances, anemia, menstrual and uterine

disorders, continued exposure to cold winds, and the excessive use of alcoholic beverages, tea, etc. The inordinate use of tea is as fertile a cause in women as is the abuse of alcohol in men.

Pathology.—There is at first a dilatation of vessels, followed by permanent enlargement, and ultimately connective-tissue overgrowth. In hypertrophic cases the corium is greatly thickened and the sebaceous glands somewhat enlarged.

Diagnosis.—The tubercular syphiloderm and lupus vulgaris may in some cases stimulate acne rosacea, but the presence of hyperemia with enlargement of vessels, and of acne papules and pustules occurring upon the nose and cheeks and running a chronic course, will render the diagnosis easy. Both syphilis and lupus tend to ulcerate.

Prognosis.—Cases of moderate severity may be much benefited or even cured by judicious treatment. When connective-tissue hypertrophy has taken place the prognosis is more guarded. The disease exhibits no such tendency to spontaneous improvement as is seen in simple acne.

Treatment.—Internal and external remedies are both of importance. The cause or causes of the disease must be assiduously investigated. When the stomach is at fault the diet should be carefully regulated. Condiments, alcohol, tea, and all sorts of stimulating articles are to be prohibited.

Due attention must be paid to the condition of the bowels. In the various forms of dyspepsia, nux vomica, the stomachic bitters, mineral acids, alkalies, etc., are to be prescribed.

A few cases will require the use of iron, strychnin, cod-liver oil, and like tonics.

Local Treatment.—The *sulphur* preparations used in the treatment of simple acne are valuable also in rosacea. Excellent results often follow the use of the "compound zinc

Ichthyol ointment externally.

Ichthyol capsules internally.

sulphid lotion," Kummerfeld's solution, or Vleminckx's solution,* diluted one to ten parts.

When the capillaries are enlarged they may be destroyed by *scarification*, by *slitting* them up with a fine knife, or by insertion of the *electrolytic needle*. In hypertrophic cases *ablation* of the diseased tissues may be performed with a knife or scissors. I believe cautery

℞ Ichthyol 1-5
Resorcin 1-3
Lanolin 25-
Olive oil 10
Dist. H₂O ad 30

ACNE VARIOLIFORMIS.

Synonyms.—Acne frontalis; acne necrotica.

Definition.—A chronic inflammatory disease characterized by papules and pustules with necrotic depressed centers, occurring for the most part about the forehead and scalp, and leaving pin-like scars.

Symptoms.—The disease is usually located upon the margin of the hair, scalp, eyebrows, etc., although other regions may become involved. The lesions consist of firm, reddish-brown papules, which undergo suppuration and become covered with a firmly adherent yellowish or brownish crust, which conceals a small central ulceration. On the fall of the crust a brownish-red depressed scar is seen. There is sometimes a disposition of the lesions to group. The disease is essentially chronic, and there is a marked tendency to recurrence. The nature of the disease is obscure. It is placed by some writers among the eruptions related to tuberculosis.

Treatment.—Sometimes there is a history of an antecedent syphilis. Such cases should be subjected to a thorough course of the iodids and mercury. Measures directed toward

---

* ℞. Calsis, ... ℥ss
Sulphur. sublimat., ... ℥j
Aquæ, ... f℥x. M.
To be boiled down to six ounces and filtered.

improvement of the general health should be employed whenever indicated. Locally, the best results are obtained with sulphur and mercurial ointments. In rebellious cases the electro- or thermo-cautery may be used.

DERMATITIS PAPILLARIS CAPILLITII.

Synonym.—Acnekeloid.

Definition.—Dermatitis papillaris capillitii is a rare inflammatory disease, commencing upon the hairy border of the nape of the neck, characterized by papules, papillomatous vegetations and keloidal elevations.

Symptoms.—The disease begins as pinhead-sized papules upon the back of the neck, often extending into the occipital region. These may remain discrete or become confluent, forming either papillomatous outgrowths or keloidal elevations. Interspersed acne pustules are also present. Some areas exhibit permanent loss of hair, while on others tufts of hair spring up from the hypertrophied cicatricial tissue. The disease is chronic and progressive.

Treatment.—The affection is markedly refractory to treatment. Epilation, followed by the application of a dram to the ounce sulphur ointment, is sometimes efficacious.

In many cases it will be found necessary to resort to the use of the electrolytic needle or the electro-cautery to destroy the growths present.

SYCOSIS.

Derivation.—Σύκωσις, fig-like, from σῦκον, a fig.

Synonyms.—Sycosis nonparasitica; sycosis vulgaris; folliculitis barbæ; coccogenic sycosis.

Definition.—Sycosis is a chronic inflammatory disease of the hair-follicles, usually of the bearded region, characterized by papules, pustules, and tubercles perforated by hairs.

Symptoms.—The disease commences by the formation of

discrete pinhead- to pea-sized papules or pustules at the sites of hair-follicles. The pustules are flat or acuminated and

FIG. 27.—SYCOSIS.

contain a yellowish fluid; they show no disposition to rupture, but dry into crusts. The surrounding skin is reddened,

sometimes swollen and infiltrated, and the seat of a variable amount of itching, burning, and pain. The pustules are discrete but may be closely aggregated. A hair perforates the center of each lesion. In the beginning the hair is firmly attached, but as suppuration becomes free it is more easily extracted. At times tubercles are present. The eruption comes out in crops, the disease lasting for months or even years.

The affection is confined to hairy regions, particularly the beard and mustache.

Etiology.—The disease obviously occurs only in adult males. The lesions are due to invasion of the follicles by micro-organisms, chiefly the staphylococcus aureus, citreus, and albus. Nasal discharge may determine a sycosis of the upper lip.

Pathology.—The pathologic process consists of a folliculitis and perifolliculitis, due to the invasion of pyogenic cocci. The inflammation is at first perifollicular, the follicle only becoming secondarily invaded by serum and pus.

Diagnosis.—Sycosis vulgaris may be confounded with tinea sycosis and pustular eczema. Below is appended the differential diagnosis.

Sycosis.	Tinea Sycosis.
1. A typical case shows small discrete papules or pustules pierced by hairs.	1. A typical case shows large lumpy or nodular tumefactions.
2. Hairs firmly attached until free suppuration occurs. Roots often swollen with pus.	2. Hairs broken and easily extracted. Roots usually dry.
3. Course slow. Little change from week to week.	3. Course rapid. Marked changes from week to week.
4. Mustache frequently affected.	4. Mustache rarely affected.
5. Absence of fungus in hairs.	5. Tricophyton fungus in hairs.

Sycosis.	Eczema Pustulosum.
1. Lesions strictly follicular, pierced by hairs.	1. Lesions apt to be interfollicular as well.

2. Eruption limited to bearded region.	2. Tends to spread upon nonhairy regions.
3. Absence of oozing.	3. Oozing marked.
4. Itching slight.	4. Itching more severe.

Prognosis.—Very few cases are incurable. The disease, however, is often refractory to treatment and lasts months or years. Recurrences are common.

Treatment.—Internal remedies, such as iron, arsenic, cod-liver oil, etc., are at times indicated by the general condition of the patient.

External treatment is, however, far more important. An essential step in the local treatment is the systematic *shaving* or *clipping* of the hairs. The beard should be closely clipped with scissors, or, better still, shaved every two or three days. When suppuration is free daily *depilation* should be practiced.

When the inflammatory signs are marked, soothing lotions, such as lotio nigra, or saturated solution of boric acid, or ointment of cold cream, oxid of zinc ointment, etc., may be employed. Most cases, however, require more stimulating applications.

Sulphur is here, as in most follicular inflammations, of great value. It is best employed in salve form, although lotions may also be used:

℞. Sulph. præcip., ... gr. xx-xl
Petrolati, ... ℥j.

A mercurial ointment often acts efficiently:

℞. Hydrarg. ammoniat., ... gr. xv-xxv
Petrolati, ... ℥j.

The following formula is highly spoken of:

℞. Ichthyol, ... ʒj-ʒij
Petrolati, ... ℥j.

A lotion of bichlorid of mercury, one-fourth to one grain to the ounce, sopped on frequently, is often followed by good results.

LUPOID SYCOSIS.

Synonym.—Ulerythema sycosiforme (Unna).

Definition.—An inflammatory disease of the skin, beginning as a sycosis, but leading to atrophy of the hair and sebaceous follicles and atrophic scarring. The disease is very rare.

Symptoms.—In the beginning the case can not be distinguished from an ordinary sycosis. In the course of some months or years the affected hair and sebaceous follicles undergo atrophy, producing permanent baldness of the part and a whitish atrophic scarring. The disease spreads by centrifugal extension, the advancing border being infiltrated, often serpiginous in outline and studded here and there with pustules. Flat vesicles and blebs, attended by intense itching and burning may develop over the affected area.

The disease involves with predilection the beard, and is inclined to be symmetric.

Pathology.—Obscure. Some believe that there is engrafted upon an ordinary sycosis a tuberculous infection. In a well-marked case I found nests of dense round-cell infiltration throughout the corium, but no giant cells or tubercle bacilli.

Diagnosis.—It is most apt to be confounded with lupus vulgaris and lupus erythematosus. The chief characters of the disease are an antecedent sycosis, atrophy of follicles, atrophic scarring, centrifugal extension, and vesicle and bleb formation, the disease being limited to the bearded region.

Prognosis.—The disease is refractory to treatment and runs a course of years.

Treatment.—No treatment has been of much avail.

PSORIASIS.

Derivation.—*ψώρα*, the itch.

Synonym.—Lepra (used by early writers).

Definition.—Psoriasis is a chronic inflammatory disease

of the skin, characterized by variously sized reddish, dry, rounded, sharply defined patches, covered with abundant imbricated silvery scales.

FIG. 28.—TYPICAL PATCHES OF PSORIASIS UPON THE FOREARMS.

Symptomatology.—The disease may occur at any age, but usually manifests itself first in adolescence or early adult life. It invariably begins as small reddish, pinpoint- to pin-

head-sized papules, surmounted with minute scales. These increase more or less rapidly by peripheral extension, reaching the size of a dime or dollar and then remaining stationary. The patches are dry, round, sharply defined, more or less elevated and infiltrated, and covered with profuse shining, grayish, whitish, or mother-of-pearl scales, which are

FIG. 29.—AN EXTENSIVE CASE OF PSORIASIS.

superimposed upon one another in an imbricated manner. When removed a reddish base is exposed which exhibits, upon scratching with the nail, punctate hemorrhage (the blood exuding from the abraded hyperemic capillary loops). *Serous exudation* is never present.

The eruption attacks with predilection the extensor surfaces of the elbows and knees, and the scalp. The trunk and other portions of the body are also frequently involved.

The disease is not attended with any constitutional disturbance. Itching is usually slight, although in some cases it is severe.

According to the size and configuration of the patches, various forms of psoriasis are distinguished.

In *psoriasis punctata* the papules are pinhead-sized.

FIG. 30.—PSORIASIS. A PINHEAD-SIZED PAPULE.—(*After Crocker.*)
a. Scaly cap. *b.* Rete mucosum considerably thickened. *c.* Moderate cell effusion in the papillary layer. *d.* Dilated blood-vessels.

In *psoriasis guttata* they attain the size and form of drops.

In *psoriasis nummularis* the patches reach the dimensions of coins of various sizes.

In *psoriasis circinata,* or *annulata,* the centers of the patches clear up, leaving ring-shaped plaques.

In *psoriasis gyrata* annular or semicircular patches coalesce, producing wavy and festooned outlines.

In *psoriasis diffusa* the patches are large and irregular, involving considerable areas of cutaneous surface.

Psoriasis pursues, as a rule, an eminently chronic course. The eruption commonly disappears, either as a result of treatment or spontaneously, but in most instances there is a recurrence sooner or later. The eruption varies greatly in extent in different attacks. The psoriatic eruption frequently disappears during the warm months of the year. The disease is not contagious.

Etiology.—Obscure. The disease occurs as frequently in robust individuals as in the debilitated. Gout and rheumatism are often associated with psoriasis, and are looked upon by some authors as causal. Hereditary predisposition is observed in some cases, and in others the disease appears to be of neurotic origin. Some writers would invoke a microbic cause, but our knowledge of the disease scarcely supports such an assumption.

Pathology.—Microscopic examination of a section of psoriatic skin shows:

1. Marked hyperplasia of the mucous layer of the epidermis.
2. Thickening of the horny layer.
3. Increased size of the papillæ, due to hyperplasia of inter-papillary projections of the rete.
4. Dilatation of the blood- and lymph-vessels and round-cell infiltration in the papillary layer of the corium.

Diagnosis.—Psoriasis is usually an easily recognized disease. The affections most likely to be confounded with it are eczema squamosum, the squamous syphiloderm, and seborrhea of the scalp.

Psoriasis.	Squamous Eczema.
1. Course chronic.	1. Course acute, subacute, or chronic.
2. Involves with predilection extensor surfaces.	2. Involves with predilection flexor surfaces.
3. Itching moderate or absent.	3. Itching present.
4. Patches sharply defined.	4. Patches fade into healthy skin.
5. Patches small and round.	5. Patches large and irregular.

6. Eruption always dry.
7. Patches covered with profuse shining, silvery scales.
8. Lesions remain unchanged from month to month.

PSORIASIS.

1. Negative history.
2. No concomitant signs.
3. Knees and elbows frequently involved.
4. Itching present.
5. Uniformity of lesions, variations in size.
6. Scales abundant, lamellar, and silvery.
7. Beneath scales is an unelevated, reddish patch.

PSORIASIS.

1. Occurs upon scalp and body.
2. Eruption in form of patches.
3. Scales dry and silvery.
4. Base inflammatory.
5. Apt to spread beyond hair border.

6. History of previous moisture.
7. Patches covered with sparse, small yellowish scales.
8. More or less rapid changes in lesions.

SQUAMOUS SYPHILODERM.

1. History of syphilis.
2. Concomitant signs present.
3. Rarely involved.
4. Itching absent.
5. Multiformity of lesions, uniformity in size.
6. Scales scanty and yellowish.
7. Beneath scales is an infiltrated, elevated, dull-red papule.

SEBORRHŒA CAPITIS.

1. Confined to scalp.
2. Eruption diffuse; involves entire scalp.
3. Scales greasy and dirty yellow.
4. Base pale.
5. Limited to hairy scalp.

Prognosis.—Favorable as far as the disappearance of the existing eruption is concerned, extremely guarded as to ultimate cure. Relapses are the rule.

Treatment.—Both internal and external measures are of importance. Of the internal remedies *arsenic* is by far the most valuable. It has distinct curative properties in many cases, but can not be regarded as a specific, inasmuch as in others it is absolutely useless. It is most likely to succeed in extensive, long-standing, indolent cases. In acute or markedly inflammatory eruptions it is likely to aggravate the disease.

Arsenic may be administered in the form of Fowler's solution (♏iij to x) or arsenious acid (gr. $^1/_{40}$ to $^1/_{10}$), and should be well diluted and taken immediately after meals.

The *alkalies* are efficient in certain cases of psoriasis, particularly in robust individuals with a gouty or rheumatic diathesis. The most eligible preparation is the liquor potassæ in ten- to twenty-drop doses, well diluted. The acetate of potash in twenty- to thirty-grain doses may also be used with good results.

Potassium iodid in large doses is at times found to be serviceable. It may be tried when arsenic fails.

Crocker speaks highly of the salicylates, particularly in rheumatic individuals.

Iron is occasionally of value, and may be employed in psoriasis in anemic and debilitated subjects.

Other remedies that have been used at different times with varying degrees of success are thyroid extract, carbolic acid, tar, turpentine, cantharides, copaiba, etc. In obstinate cases these may be tried, and will occasionally be found to do good where arsenic and other remedies have failed.

Local Treatment.—An essential preliminary to the inauguration of topical treatment is the removal of the scales. It is useless to make liquid or unguentous applications to an impenetrable mass of scales; they must be removed so that the medicaments may be applied directly to the skin surface. Scales may be removed by washing with ordinary soap and water, by frictioning with soft soap, or, best of all, by prolonged baths (simple or alkaline) with the use of soap.

The chief local remedies employed in psoriasis are tar, chrysarobin, pyrogallic acid, ammoniated mercury, salicylic acid, etc.

Tar is a valuable application and is usually well borne. Its odor and color are its chief disadvantages. It may be used in the form of an ointment, paint, or bath. The preparations usually employed are the unguentum picis (officinal tar ointment), oleum cadini (the oil of cade), and oleum rusci (the

oil of birch), in the strength of one to four drams to the ounce.

℞. Ung. picis, Ol. cadini, or Ol. rusci ʒij
Adipis or Collodii flex., . q. s. ad ℥j.
Sig.—To be used night and morning.

The tar bath is a convenient and efficient method of using this medicament in extensive cases. The patient anoints himself with tar ointment and then steps into a warm bath, in which he remains for about a half-hour.

Chrysarobin is the most rapidly efficient remedy at our disposal. It has, however, certain grave disadvantages which restrict its use to selected cases. It stains the skin temporarily and the underclothing permanently. Furthermore, it may set up a severe dermatitis or a conjunctivitis, particularly when used about the face. It may be safely employed in cases with a limited number of large chronic patches upon the body or extremities. It may be incorporated in an ointment or a paint:

℞. Chrysarobini, ... gr. x-xl
Pulv. amyli,
Pulv. zinci oxidi, ... āā ʒij
Petrolati, ... ʒiv.

Or—

℞. Chrysarobini, ... gr. x-xxx
Liquor gutta perchæ (traumaticin)
or Collodii flex., ... fʒj.

The application should be at first weak and used only over a limited surface. The ointment is to be applied once or twice daily, the paint every two or three days.

Pyrogallic acid ranks in efficiency after chrysarobin, and may be used in the same manner and strength. It stains the underwear, and if used over too great an area may produce fatal poisoning through absorption.

Ammoniated mercury and *salicylic acid* both have the advantage of being free from odor and excessive irritation,

and may therefore be employed with benefit upon exposed parts, such as the face and scalp.

℞. Hydrarg, ammoniat, or acidi salicylici, ... gr. x-xxx
Petrolat., ... ℥j.
Sig.—Use night and morning.

PITYRIASIS RUBRA FOLLICULARIS.

Synonym.—Pityriasis rubra pilaris.

Definition.—Pityriasis rubra follicularis is a chronic inflammatory disease characterized by a generalized eruption consisting of small, follicular papules with horny centers.

Symptoms.—The affection often begins as a seborrhœa sicca of the scalp or a scaliness of the palms and soles. Later, there develop hard, dry, conical, brownish-red papules varying in size from a pinhead to a millet-seed and situated about the hair and sebaceous follicles. These may remain discrete or run together in patches. In a well-marked case a nutmeg-grater sensation is imparted to the finger passed over the surface.

The favorite seats of the eruption are the extensor surfaces of the extremities, particularly the backs of the hands and fingers. The eruption is often general and not uncommonly universal.

Itching is slight or absent. The duration of the disease is variable.

Treatment.—Internally, tonics are to be administered. The remedies employed locally are practically the same as those used in psoriasis—namely, pyrogallic acid, tar, mercury, etc. Baths are often of great value.

PITYRIASIS RUBRA.

Derivation.—*Πίτυρον*, bran.

Definition.—A chronic inflammatory disease of the skin,

involving usually the entire surface, characterized by deep redness and profuse and continuous flaky desquamation. The disease is exceedingly rare.

Symptoms.—The affection begins as small reddish, scaly patches, which by coalescence may involve the entire body surface. The skin is uniformly reddened and is covered

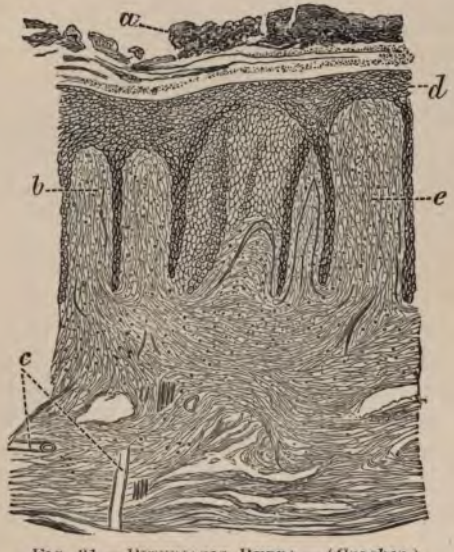

FIG. 31.—PITYRIASIS RUBRA.—(*Crocker.*)

a. Scales. *d.* Rete, thinner above but with enormously elongated interpapillary processes. *e.* Papilla enlarged vertically and transversely. *b.* Papillæ and upper part of corium infiltrated with leukocytes. *c.* Dilated blood-vessels.

with whitish and grayish papery scales. Desquamation persists throughout and is a characteristic symptom. The skin is always dry, vesiculation never taking place.

Itching, burning, thickening, and infiltration are slight or absent. The patient is sensitive to cold and often complains of chills. The disease lasts for months or years and tends to a fatal termination.

Etiology.—Obscure. It is more common in men than in women, and occurs in adult life.

Pathology.—There are all the signs of a chronic inflammation of the skin, followed by atrophy.

Diagnosis.—The disease may be confounded with squamous eczema, psoriasis, lichen ruber, and pemphigus foliaceous.

Prognosis.—Grave.

Treatment.—Unsatisfactory. Locally, inunctions with vaselin and bland oils. Internally, such tonics as cod-liver oil, iron, and quinin.

DERMATITIS EXFOLIATIVA.

Synonym.—General exfoliative dermatitis.

Definition.—Dermatitis exfoliativa is an acute inflammatory disease, characterized by intense generalized redness followed by profuse desquamation, and accompanied by fever and other constitutional symptoms.

Symptoms.—The onset of the disease is sudden and attended by fever, malaise, and prostration. The eruption, which consists of an intense erythematous efflorescence, may be either diffuse or in patches. Rapid spreading over the entire body soon occurs, followed in a few days by profuse scaling of a flaky character. The skin of the palms and soles may be exfoliated *en masse* as well-marked epidermal casts. The hair and nails may also be shed. Itching and burning are present in varying degrees.

The disease runs its course in a few weeks or months, but is extremely prone to recur, at times observing well-marked periodicity.

A somewhat different type of the disease, pursuing a more chronic course, develops at times from a long-standing psoriasis or eczema. The disease is distinctly rare.

Etiology.—Obscure.

FIG. 32.—EPIDERMAL CASTS OF THE PALMS AND SOLES.—(*From a case of Dermatitis Exfoliativa.*)

Treatment.—The treatment is both internal and external. At the beginning of an attack the patient should receive a brisk saline purge. Quinin in full doses should then be administered. The patient is, of course, to be confined to bed.

Locally, emollient ointments such as are employed in eczema should be used.

In chronic cases arsenic, cod-liver oil, and other tonics are of value.

PITYRIASIS ROSEA.

Synonyms.—Pityriasis maculata et circinata; herpes tonsurans maculosus.

Definition.—A self-limited inflammatory disease of the skin characterized by rose-colored erythemato-squamous patches occupying chiefly the trunk, and accompanied by mild constitutional disturbance.

Symptoms.—A primitive patch may precede the eruption by a few days to a week. The eruption comes out more or less rapidly, so that in the course of a week or ten days the trunk and thighs, which are the seats of predilection, may be profusely covered. The lesions consist of pinkish or rose-colored macules and maculopapules, which increase in size by peripheral extension, many reaching the dimensions of a silver half-dollar. The patches are often oval, their long axes corresponding to the lines of cleavage. Central involution occurs in many patches, giving them a circinate configuration. At this stage the typical lesion presents a yellowish or fawn-colored center, with a pinkish, slightly elevated border covered with furfuraceous scales.

Itching is moderate, but in some cases may be severe, particularly at night. Mild elevation of temperature with concomitant febrile symptoms are often present. The disease is rather infrequent.

℞ Barium Sulph } make paste & apply
Zinci Ox } 3-5 min & repeat
10 days.

Etiology.—The cause is unknown. In some respects the disease suggests an acute exanthematous disease.

Diagnosis.—The disease is to be distinguished from tinea circinata, squamous eczema, psoriasis, and the squamous syphiloderm. The acute onset, the rapid progression of the eruption, the extreme superficiality of the lesions, their peculiar shape and coloration, the definite course and spontaneous involution, will usually enable one to make the diagnosis.

Prognosis.—Always favorable. The affection is self-limited, running its course in from four to eight weeks.

Treatment.—For the relief of itching one of the following lotions may be used:

Glycerolin 3%

℞.	Acidi carbolici,	f3j	Naphthol 10% alcohol.
	Zinci oxidi,	3ij	
	Glycerini,	f3ij	In Iodine
	Aquæ,	f℥vj.	

Or—

℞.	Sodii hyposulphit.,	3vj	Hg Amm 1%
	Aquæ,	f℥vj.	

Or a salicylic acid or sulphur ointment, ten and thirty grains to the ounce respectively, may be used. It is doubtful whether treatment exerts any curative effect. Quinin and tonics are at times indicated.

ERYSIPELAS.

Derivation.—Ἐρυθρός, red; πέλλα, the skin.

Synonym.—St. Anthony's fire.

Definition.—Erysipelas is an acute specific inflammation of the skin and subcutaneous tissue, characterized by shining redness, swelling, heat, pain, and vesication, and accompanied by fever and constitutional disturbance.

Symptoms.—The disease is usually ushered in with a chill, malaise, headache, and elevation of temperature (102° to 105° F.). The erysipelatous eruption is highly characteristic. The affected area is sharply defined, of a shining crim-

son or violaceous hue, elevated above the surrounding skin, and firm, hot, and tender to the touch. In addition vesicles or blebs are prone to develop. The patient complains of pain, burning, or itching. The eruption tends to spread by peripheral extension, the older parts first undergoing involution. The eruption in any one locality runs its course in four or five days, ending in desquamation. The disease, however, may last for weeks owing to constant extension.

The face is by far the most frequently affected region. In this situation the eruption is extremely apt to spread over the forehead and scalp to the nape of the neck.

Erysipelas ambulans or *migrans* is a variety which tends to subside rapidly in one region, reappearing in another, the whole process continuing for several weeks.

There is a mild *recurrent* form of erysipelas which is prone to attack the cheeks and the alæ of the nose. The constitutional disturbance is mild or entirely absent. The eruption does not tend to spread beyond the face, and usually disappears in three or four days. It is due to micro-organismal infection through the mucous membranes of the adjacent cavities, particularly the nose.

Etiology.—The affection is due to the introduction into the skin of the *streptococcus erysipelatis*. Depression of the vital forces and the existence of wounds or abrasions act as predisposing causes. In the recurrent variety due to nasal infection catarrhal conditions of that organ predispose.

Prognosis.—Favorable in the vast majority of cases. In rare cases, abscesses or gangrene may develop. In severe cases death may result.

Treatment.—Internally, tincture of the chlorid of iron, ♏x every two or three hours; quinin, gr. ij four times a day; and stimulants. Locally, carbolized petrolatum, twenty-five per cent. ichthyol ointment, or compresses wrung out of a dram to the ounce aqueous solution of hyposulphite of soda,

etc. When the extremities are involved extension may sometimes be checked by the use of tincture of iodin or the stick of nitrate of silver applied to the spreading periphery.

In the recurrent form the nose and mouth should receive careful treatment, detergent washes such as Dobell's solution being employed.

ERYSIPELOID (*Rosenbach*).

Synonyms.—Erysipelas chronicum; erythema migrans.

Definition.—Erysipeloid is an inflammatory affection of the skin, resembling to some extent erysipelas, produced by the special micro-organism of decomposing animal matter.

Symptoms.—There are no constitutional phenomena. The disease affects the fingers and hands of scullions, butchers, fish dealers, etc. Its origin is a wound, from which a sharply defined violaceous or dark crimson zone extends. The spreading is much slower than in erysipelas. Itching and burning are often marked. The condition lasts from one to six weeks, and disappears without desquamation.

The causal micro-organism belongs to the order of Cladothrix.

Treatment.—Antiseptic ointments. Ichthyol, twenty-five per cent.; ammoniated mercury, ten per cent., etc.

DERMATITIS.

Definition.—Dermatitis or inflammation of the skin is a cutaneous disorder characterized by heat, redness, pain, and swelling—in other words, by the ordinary phenomena of inflammation. The term is restricted to acute inflammations, the result of known irritants. For purposes of classification and study several varieties of dermatitis are distinguished:

(*a*) Dermatitis traumatica.

(*b*) Dermatitis calorica.

(*c*) Dermatitis venenata.
(*d*) Dermatitis medicamentosa.
(*e*) Dermatitis gangrænosa.

DERMATITIS TRAUMATICA.

Under this head are included all forms of inflammation due to mechanical violence to the skin, such as contusions, lacerations, and excoriations (due to friction, scratching, etc.). The traumatism produced by scratching is of most importance to the dermatologist.

DERMATITIS CALORICA.

This form of dermatitis is due to exposure to excessive heat (*dermatitis ambustionis,* burn) or to excessive cold (*dermatitis congelationis,* frostbite, chilblain). In both forms we have, according to the severity of the inflammation, erythema, vesication, or gangrene, accompanied by severe pain.

Treatment of Burns.—Ichthyol, ʒij, petrolatum, ℥j. Carron oil (equal parts of linseed-oil and lime-water). Acidum carbolicum, gr. x, acidum boricum, gr. xxx, petrolatum, ℥j. Powder or solution of bicarbonate of soda.

Treatment of Frostbite.—Rubbing with snow. Stimulating applications, such as turpentine, camphor, iodin, ichthyol, carbolized oil, or ointments, etc.

DERMATITIS VENENATA.

This form of inflammation is due to the contact with deleterious animal and vegetable substances. Among these may be mentioned the acids of alkalies, croton oil, mustard, cantharides, analin dyes, etc. The dermatologist is more particularly interested in the dermatitis produced by poisonous plants, chiefly the *Rhus toxicodendron,* poison ivy or oak, and the *Rhus venenata,* poison sumach or dogwood.

The poisonous principle in these plants is a volatile substance—toxicodendric acid.

FIG. 33.—IVY POISONING.

Symptoms.—From a few hours to several days after exposure the hands, face, and genitalia (in a typical case) be-

come the seat if innumerable vesicles and blebs, accompanied by redness, swelling, and great burning or itching. The vesicles and blebs are, at times, angular or stellate, and not infrequently appear in linear streaks. The eruption may be carried to various parts of the body by auto-inoculation. The eruption lasts from one to four weeks. Some individuals are extremely susceptible to ivy poison, so much so that proximity without contact suffices to bring on an attack. Other individuals enjoy comparative immunity. The treatment consists of the application of mildly astringent and sedative lotions and ointments. The following are among the most valuable preparations:

1. Saturated solution of boric acid.
2. Sodium hyposulphite, ʒj to water f℥j.
3. Fluid extract of grindelia robusta, fʒj to water f℥iv.
4. Bromin, ♏x-xv to olive oil f℥j.
5. Equal parts of lotio nigra and aqua calcis.
6. Carbolic acid, gr. x; petrolatum, ℥j.
7. Boric acid, gr. xxx; petrolatum, ℥j.

DERMATITIS MEDICAMENTOSA.

(Drug eruptions.)

This class includes eruptions due to the ingestion or absorption of certain medicaments. Drug eruptions are favored by (*a*) idiosyncrasy, (*b*) excessive cutaneous elimination, (*c*) imperfect renal and intestinal elimination (often due to renal or cardiac disease), (*d*) large doses, (*e*) long-continued administration. Individual susceptibility is the most important factor. The eruption may be macular, papular, vesicular, urticarial, bullous, or hemorrhagic.

The following is a list of the drugs most likely to produce eruptions: Antipyrin, arsenic, belladonna, bromids, chloral, copaiba, cubebs, digitalis, iodids, mercury, opium, quinin, salicylic acid, etc.

Antipyrin.—Out of fifty-two cases collected by Spitz, forty-one were morbilliform, four urticarial, and seven erythemato-papular. Eruptions prone to itch and desquamate. Not uncommon.

Arsenic.—Urticarial eruption most frequent; may, however, be erythematous, papular, or vesicular. Extensive pigmentation may follow long-continued use of arsenic; herpes zoster thought to be produced by it at times. Eruption rare.

Belladonna.—Erythematous eruption resembling scarlatina. Not uncommon.

Bromids.—Pustular (acneiform) eruption most frequent. In children reddish-brown, fungating nodules are quite characteristic. Macular, papular, and bullous eruptions may occasionally occur. Eruption common.

Chloral.—Papular, erythematous, and urticarial eruptions most common; sometimes pustular or hemorrhagic. Eruptions occasional.

Copaiba.—Usually maculo-papular; sometimes scarlatinoid or morbilliform. Eruption not uncommon.

Cubeba.—Same as copaiba. Eruption uncommon.

Digitalis.—Scarlatiniform; maculo-papular. Eruption is rare.

Iodids.—The eruption is usually pustular (acneiform); bullous eruption next in frequency. May be erythematous, papular, pustular, bullous, hemorrhagic, or urticarial. Common.

Mercury.—Erythematous (scarlatinoid) and erysipelatous. Eruption unusual.

Opium.—Maculo-papular and urticarial; may resemble measles or scarlet fever. Eruption uncommon.

Quinin.—Of sixty cases analyzed by Morrow, thirty-eight were erythematous, twelve urticarial, five purpuric, and two vesicular and bullous. The erythema is usually scarla-

[illegible] is usually desquama-[illegible]

—[illegible] is an [illegible] Recession-[illegible] [illegible] is uncommon.

DERMATITIS GANGRENOSA.

Synonyms.—[illegible]

[illegible] DERMATITIS.

Synonyms.—[illegible] multiple disseminat-[illegible]

Definition.—[illegible] having varicella [illegible]

Symptoms.—[illegible] or simple [illegible] pin-sized [illegible] inflammation [illegible] with a [illegible] fever. [illegible] symptoms of [illegible]

Prognosis.—[illegible] number of [illegible]

Treatment.—[illegible] in one-[illegible] days [illegible] hours. Complications [illegible] as they arise. Locally, antiseptic applica-[illegible]

SYMMETRICAL GANGRENE.

Synonyms.—Raynaud's disease; local asphyxia; spon-[illegible] gangrene.

Definition.—A local arterial ischemia, generally followed by a phase, occurring at the periphery of the circulation, and producing symmetrically distributed gangrene of the skin and other tissues in the affected region (Crocker).

Symptoms.—The disease usually attacks the fingers and toes, although the nose and ears are also occasionally affected. With or without preceding pain and numbness, the parts become cold and whitish. After a variable persistence of this stage, local asphyxia develops, characterized by lividity, bluish discoloration and at times swelling and pain. The symptoms in this stage often exhibit marked change from time to time. In most cases the disease goes on to the terminal stage of gangrene, the sphacelated tissues being cast off leaving granulating wounds. Some cases continue for a long time with persistently livid fingers and toes, and may recover, although even in these cases relapses are the rule.

When the patient is debilitated or the affected areas large, death may result.

The disease is in most instances a vasomotor neurosis.

Etiology.—Exposure to cold is the most frequent cause. The affection has been observed to follow diphtheria, typhoid fever, scarlatina, measles, malaria, syphilis, and diabetes.

Prognosis.—In extensive cases in the very old or young the prognosis is serious. When the affected areas are small, the prognosis is good, but there is tendency to recurrence.

Treatment.—When seen early, galvanism with one electrode applied to the spine and the other immersed with the affected part in water is the best treatment. Friction with stimulating liniments, as for frostbites, is also of value.

Diabetic Gangrene.

In advanced cases of diabetes mellitus localized cutaneous gangrene may occur. The process is apt to begin as a bleb, which dries, forms a crust, and is thrown off with the underlying sphacelated skin, leaving a granulating ulcer. The process is apt to attack the middle of the extremities (calves, etc.) rather than the fingers or toes.

FEIGNED ERUPTIONS.

Feigned or artificial eruptions are sometimes seen in hysteric women, criminals, mendicants, and others. They are designed to excite sympathy and charity or are prompted by some morbid idea or other. The dermatitis may be erythematous, bullous, or gangrenous, and is produced by acids, caustics, friction, etc. The peculiarities of feigned eruptions are: (*a*) Their oddity or deviation from the ordinary types of skin disease; (*b*) their sharp definition; (*c*) their limitation to regions accessible to the hands.

FURUNCULUS.

Derivation.—*Furunculus* (L.), a knave.

Synonyms.—Boil; furuncle.

Definition.—A furuncle is an acute circumscribed inflammation of a sebaceous gland or hair-follicle, ending in suppuration and the extrusion of a central necrotic mass.

Symptoms.—A furuncle begins as a painful, deep-seated induration which gradually approaches the surface, showing itself as a rounded or acuminate reddish prominence. In the course of a few days softening takes place, with the formation of a central slough or "core." The resulting depression heals up by granulation with the production of a slight scar. When no suppuration or necrosis takes place the lesion is termed a "blind boil."

Around one furuncle as a focus numerous satellites are apt to form. This may be due to external auto-inoculation or lymphatic transmission. *Furunculosis* is a condition in which there are intermittent outbreaks of boils extending over a period of weeks or months. This condition is not infrequently seen in diabetes and Bright's disease.

Etiology.—Boils are due to the introduction of pyogenic microbes into the hair-follicles or sebaceous glands. Impoverished health renders the soil favorable, but it does not pro-

duce furuncles *per se.* Uncleanliness, itching dermatoses (promoting scratching), and certain occupations (tar and petroleum working) all favor the development of boils.

Pathology.—The process consists of a dense leukocytic infiltration around a sebaceous gland or hair-follicle, with thrombotic obstruction of the capillary blood-vessels and a central necrosis. The exciting organism is a pyogenic microbe, usually the staphylococcus pyogenes aureus.

A similar condition affecting the sweat-glands is considered under the head of Hidradenitis Suppurativa.

Diagnosis.—The ordinary characteristics of a boil are too well known to require discussion here.

Prognosis.—In single furuncles, good. Furunculosis may long remain refractory to treatment.

Treatment.—Single lesions should be incised as soon as the first evidences of suppuration occur.

Abortive applications—such as carbolic acid, nitrate of silver, tincture of iodin—fail, as a rule, to abort, although they may do good as counterirritants. A twenty-five per cent. ichthyol plaster protects the boil and tends to prevent autoinoculation. An excellent method is to apply hot boric acid compresses covered with oiled silk. The use of this lotion upon the surrounding skin lessens the liability to further follicular infection.

In the treatment of furunculosis the urine should be carefully examined to determine whether or not diabetes or Bright's disease exists. The lesions should be treated surgically as early as possible. In obstinate cases tonics and sulphid of calcium (gr. ¼ q. i. d.) may be tried. Brewer's yeast has recently been re-introduced in the treatment of furunculosis with alleged good results in many cases. A teaspoonful or two of the liquid yeast is to be taken in milk or water three times a day.

CARBUNCULUS.

Derivation.—Diminutive of *carbo,* a live coal.

Synonyms.—Anthrax benigna; carbuncle.

Definition.—Carbuncle is an acute phlegmonous inflammation of the skin and subcutaneous tissue, characterized by multiple foci of necrosis and sloughing of the superimposed integument.

Symptoms.—There is, as a rule, but one lesion present, having for its seat of predilection the neck or back. It begins as a flat, painful infiltration, varying in size from a chestnut to an orange. The skin is of a violaceous hue and board-like. At the end of a week or ten days the overlying integument sloughs in numerous points, exposing to view grayish-yellow necrotic masses, from which a sanious pus exudes. This cribriform appearance is characteristic of carbuncle. Later, the entire superjacent skin becomes gangrenous, and, being thrown off with the necrotic masses, leaves a gaping ulceration, which heals up by granulation, with the production of a permanent scar.

The process is usually accompanied by chill, fever, and prostration. In the old and debilitated a fatal septicemia may develop.

Etiology.—Occurs usually after the fortieth year. The same predisposing causes are operative as in furuncle—namely, diabetes, general debility, etc. The exciting cause is the introduction into the skin of a pyogenic micro-organism.

Pathology.—The process begins in the sebaceous glands or hair-follicles. Suppuration occurs simultaneously in numerous adjacent foci. The skin and subcutaneous tissue are enormously swollen and have imbedded in them the yellowish-white necrotic plugs. The process extends laterally and vertically, and ends in a gangrene of the entire area.

Diagnosis.—In the beginning only may furuncle and carbuncle be confounded:

CARBUNCLE.	FURUNCLE.
1. Occurs usually in late adult life.	1. Occurs at any age.
2. Favorite situation, neck or back.	2. Indefinite localization.
3. Chestnut- to orange-sized.	3. Pea- to cherry-sized.
4. Surface flat.	4. Surface round or conical.
5. Skin board-like or brawny.	5. Ordinary inflammatory induration.
6. Multiple suppurating openings.	6. Single opening.
7. Terminates in gangrene.	7. Heals after extrusion of "core."
8. Marked constitutional disturbance.	8. As a rule, absent.

Prognosis.—Favorable except in the aged and debilitated and in diabetics and alcoholics. Carbuncle upon the head or face is more serious than in other localities.

Treatment.—Various methods have been employed. Most authors favor parenchymatous injections of strong caustics rather than making crucial incisions. Crocker recommends the injection of glycerin and carbolic acid, one to two or four, as soon as suppuration begins. Wood and Taylor advise the injection of pure carbolic acid into various portions of the sloughing area. The stick of caustic potash may be bored into the openings of the carbuncle. After gangrene has occurred antiseptic applications, such as hot boric acid compresses, are useful. When septicemic symptoms become marked it is justifiable to excise the entire affected erea. This is usually followed by prompt improvement in the symptoms.

Nutritious food and stimulants are necessary to sustain the strength. Morphin and chloral are often demanded to relieve pain and produce sleep.

EQUINIA.

Derivation.—*Equus*, a horse.

Synonyms.—Glanders; farcy.

Definition.—Equinia is a contagious specific disease de-

rived from horses, characterized by constitutional disturbance and lesions of the respiratory and cutaneous systems.

Symptoms.—The site of inoculation is marked by an inflammatory papule or pustule, which soon degenerates into a ragged, undermined, spreading ulcer, with accompanying lymphangitis and glandular swelling. Later, numerous cutaneous and subcutaneous nodules develop, which break down and discharge (farcy buds). There is usually nasal ulceration, with a foul-smelling discharge. Most cases run an acute course, ending in death. Those that last several months may recover. The constitutional symptoms are fever, prostration, joint pains, and a typhoidal state.

Pathology.—The disease is due to the glanders bacillus (*Baccillus mallei*).

Prognosis.—In the acute form nearly all die; in the chronic form fifty per cent. recover.

Treatment.—Destruction of lesion by curet or caustics. In chronic cases, quinin in large doses, and stimulants.

ANTHRAX.

Synonyms.—Pustula maligna; charbon.

Definition.—Anthrax is a specific disease produced by the bacillus anthracis, characterized by gangrenous carbuncle-like cutaneous lesions.

Symptoms.—The lesion begins as a hemorrhagic bulla or pustule, beneath which a gangrenous eschar with a dusky red infiltrated areola forms. The surrounding skin is markedly edematous and the neighboring lymphatic glands enlarged. The lesions may be one or more, and are usually situated upon the face, hands, or neck. The constitutional symptoms consist of chill, vomiting, fever (104° F. or more), and pains in the head and bones. Later there may occur typhoidal symptoms, and death in two or three days.

Etiology.—The disease is more often derived from the bodies of animals affected with splenic fever than from the living animals themselves; therefore butchers, tanners, wool-sorters, etc., are the usual victims.

Pathology.—The exciting cause is the bacillus anthracis, which, after the first day, may be found in the blood and all the secretions.

Diagnosis.—The distinctive features are a gangrenous patch with vesicular border surrounded by great edema and infiltration, and severe constitutional symptoms. The occupation of the patient is an important factor.

Prognosis.—The disease is fatal in about thirty-three per cent. of cases.

Treatment.—Early free excision. Supportive treatment.

POSTMORTEM PUSTULE.

Synonym.—Dissection wound.

Definition.—Postmortem pustule is a condition resulting from infection from the cadaver, and is characterized by an inflammatory lesion at the point of inoculation, and occasionally lymphangitis, lymphadenitis, and slight constitutional disturbance.

Symptoms.—Inoculation takes place at the site of a cut or abrasion. An itchy red spot is followed by the development of a vesicopustule with a broad, painful, inflammatory areola. Suppuration goes on beneath the crust, which reforms as soon as removed. The lymphatic vessels and glands may be affected, and there is often slight fever and malaise.

Treatment.—Curetting or cauterization of the pustule, followed by antiseptic dressings.

Postmortem tubercle will be considered under the head of Tuberculosa Verrucosa Cutis.

AINHUM.

Derivation.—From a native term meaning "to saw."

Definition.—Ainhum is a tropical endemic disease characterized by a slow, spontaneous amputation of the little toe.

Symptoms.—The affection occurs almost exclusively in Africans and Hindoos. It begins as a circular furrow in the digito-plantar fold of the little toe. This slowly increases in depth until the digit is constricted as by a ligature, when the distal portion swells up and is slowly thrown off by dry gangrene. This is accomplished usually in the course of from five to ten years.

Etiology and Pathology.—Obscure.

Treatment.—In the beginning cure may result from a severing of the constricting band. In advanced cases amputation is required.

TINEA TRICHOPHYTINA.

Derivation.—*Tinea*, a moth-worm; θρίξ, hair; φυτόν, a vegetation.

Synonym.—Ringworm.

There are three varieties:

1. Tinea circinata—ringworm of the body.
2. Tinea tonsurans—ringworm of the scalp.
3. Tinea sycosis—ringworm of the beard.

TINEA CIRCINATA.

Synonyms.—Ringworm of the body; herpes circinatus; tinea trichophytina corporis.

Definition.—Tinea circinata is a contagious vegetable parasitic disease due to the trichophyton fungus and characterized by annular vesiculo-squamous patches upon the body surface.

Symptoms.—The disease begins as one or several rounded

or irregular pea-sized, hyperemic, scaly patches. In a few days these assume a circular shape with minute papules or vesicles around the circumference.

Peripheral spreading and central healing progress hand in hand, so that the patches when fully developed are distinctly annular or ring-shaped. They are usually coin-sized, of a dull pinkish or reddish color, with slightly elevated borders which exhibit a branny desquamation. The confluence of

FIG. 34.—TINEA CRURIS.—(*After Piffard.*)

neighboring patches may occur with the production of gyrate lesions. But two or three patches are, as a rule, present.

Itching is usually slight. The face, neck, and backs of hands are the most frequent seats.

In *tinea cruris* (*eczema marginatum, tinea trichophytina cruris*) the clinical appearances are so much modified as to frequently simulate an eczema intertrigo. The patches are large, diffuse, of a dull or brownish-red color, with a well-

defined marginated and at times slightly elevated border. Outlying circinated patches are usually present.

FIG. 35.—TINEA CIRCINATA.

The eruption spreads with remarkable rapidity, successively involving the thighs, groins, genitals, mons veneris, and nates. Eczema is apt to complicate the affection. The itching is often severe, particularly at night.

Termol. R.R. Roques. 9.00 Gal
2.50 qt.
dilute equal part water in
slip foot or hand + let drip off
1-2 x day

FIG. 38.—TINEA CIRCINATA. ×700.—(*After Kaposi.*)

Tinea Trichophytina Unguium (*Onychomycosis, Ringworm of the Nail*).—Occasionally the nails are invaded by the ringworm fungus. They become opaque, white, thickened, and soft or brittle. Two or three nails are usually affected. The disease runs a chronic course and is refractory to treatment.

Pathology.—The fungus is found in the epidermis, particularly in the corneous layer. Mycelium is abundant, spores scanty. The former consists of long, slender, sharply contoured, bifurcated, jointed threads. The spores are rounded, highly refractile bodies, varying from $^1/_{1000}$ to $^1/_{600}$ of an inch in diameter.

Diagnosis.—Tinea circinata may be distinguished from eczema, psoriasis, and seborrhea by the superficial character of the lesions, their annular configuration, the history, course and finally and conclusively by the microscopic examination.

Method of Examining for the Fungus.—Epidermic scales are scraped off with a knife and placed on a microscopic slide with a drop of caustic potash (20 to 40 per cent.). A cover-glass is then applied, with sufficient pressure to flatten out the scales. The fungus is best studied with an oil-immersion lens, although it can be seen with the dry system.

Prognosis.—As a rule, the affection yields promptly to treatment. Tinea cruris is more rebellious than the ordinary form.

Treatment.—The treatment consists in the use of parasiticide ointments and lotions. Mercury, sulphur, betanaphthol, resorcin, tar, and chrysarobin are all valuable. An efficient formula is:

℞. Hydrarg. ammoniat., ... gr. xx-xl
Ung. zinci oxidi, ... ℥j.

Hyposulphite of sodium (ʒj to aqua f℥j) and bichlorid of mercury (gr. ss-j to aqua f℥j) are useful applications, especially in tinea cruris.

TINEA TONSURANS.

Synonyms.—Ringworm of the scalp; herpes tonsurans; tinea trichophytina capitis.

Definition.—Tinea tonsurans is a contagious vegetable

FIG. 37.—RINGWORM OF THE SCALP.

parasitic disease characterized by circumscribed areas of partial baldness, with evidence of disease of the hair.

Symptoms.—The disease begins as small, rounded, reddened scaly patches, occurring upon any portion of the hairy scalp. Soon the follicles become invaded, and circumscribed hair-fall results. Typical lesions consist of partially bald,

discrete, rounded, coin-sized, slightly reddened patches covered with grayish scales. The follicles are prominent, producing a "goose-flesh" appearance. The hairs are lusterless and consist of "broken or gnawed-off stumps." They lie loosely in the follicles and are easily extracted.

FIG. 38.—HAIR AND ROOT-SHEATH IN TINEA TONSURANS. ×700.—(*After Kaposi.*)

In rare cases ringworm may affect the scalp diffusely, without the production of circumscribed patches (*disseminated ringworm*).

The only subjective symptom is itching, which is usually of a mild character. The disease occurs almost exclusively

in children. In adults it is so rare as to constitute a dermatologic curiosity.

The course of the affection is extremely chronic. When cure results, full restoration of hair takes place.

Tinea kerion is a highly inflammatory ringworm terminating in suppuration. The patches are reddish or yellowish, raised, edematous, and boggy; they are honeycombed with distended openings of hair-follicles, through which exudes a yellowish pus. Burning, itching, tenderness and pain are present in a variable degree. The suppuration of a ringworm hastens its cure, but may destroy the follicles and produce permanent baldness.

Etiology.—The disease is produced by a vegetable parasite, either the *trichophyton fungus* or the *microsporon Audouini.* Ringworm is essentially a disease of childhood. The affection is communicated from one child to another by direct contact or through the medium of caps, brushes, combs, towels, etc. It may also be contracted from the lower animals, such as the cat, dog, horse, or ox.

Tinea circinata in the adult may produce tinea tonsurans in the child and *vice versa.*

Pathology.—The fungus is found in the hair, the hair-follicle, and the epidermis. In this form of the disease the spores are extremely abundant in the hair, producing under the microscope a fish-roe appearance. The mycelium is usually scanty or absent. The hair is prepared by immersion in liquor potassæ and is examined without staining. Only broken-off hairs are to be selected for examination.

Diagnosis.—The characteristic features of tinea tonsurans are circumscribed patches of partial baldness, grayish scales, goose-flesh appearance, broken-off stumps of hair, and the presence of the fungus.

These points will enable one to distinguish the disease from eczema, psoriasis, and seborrhea. The differential

diagnosis from alopecia areata is here appended:

TINEA TONSURANS.	ALOPECIA AREATA.
1. Slow and insidious onset.	1. Rapid onset.
2. Patches are—	2. Patches are—
(*a*) Covered with "broken-off stumps."	(*a*) Totally devoid of hair.
(*b*) More or less reddened.	(*b*) Pale and whitish.
(*c*) Rough and scaly.	(*c*) Smooth and soft.
(*d*) Follicles prominent; goose-flesh appearance.	(*d*) Follicles contracted.
3. Fungus present.	3. Absence of fungus.
4. Occurs almost exclusively in children.	4. Common in adolescence and adult life.

Prognosis.—As to ultimate cure, favorable. As to duration, guarded. Most cases persist from six months to one and a half years.

Treatment.—The treatment consists of (1) daily soap and hot-water cleansings, (2) epilation of diseased hairs, and (3) application of parasiticide ointments and lotions. The scalp will bear remedies of greater strength than the non-hairy surfaces.

The choice of the parasiticide is not a matter of importance. It is the perservering and thorough use of the same that brings success.

Any of the following ointments may be used:

℞. Betanaphthol, ... ʒj
Petrolat., ... ℥j.

℞. Resorcini, ... ʒj
Petrolat., ... ℥j.

℞. Hydrarg. ammoniat., ... ʒj
Petrolat., ... ℥j.

℞. Acidi carbolici, ... gr. xx
Petrolat., ... ℥j.

℞. Sulph. præcip., ... ʒj to ʒij
Petrolat., ... ℥j.

" sulph. Tar aa ℥j
Hydrarg. Amm aa ℥j
Acid. Salicy gr xx 20
Lanoline
Vaseline aa ℥j 16

℞. Chrysarobin, ... gr. xl
Petrolat., ... ℥j.
(To be used cautiously in rebellious cases.)

Or one may employ such lotions as—

℞. Hydrarg. chlor. corrosiv., . . gr. ij-iv to aq. f℥j.

℞. Sodii hyposulph., ... ʒj to aq. f℥j.

The applications are to be made twice daily. Epilation is to be practiced each day, the short, stumpy hairs being removed with a broad, flat-bladed forceps.

The microscope should be repeatedly brought into requisition before any case is pronounced cured.

TINEA SYCOSIS.

Derivation.—Σῦκον, a fig.

Synonyms.—Barber's itch; parasitic sycosis; tinea trichophytina barbæ; ringworm of the beard.

Definition.—Tinea sycosis is a contagious vegetable parasitic affection due to the trichophyton fungus, and attacking the hairs and hair-follicles of the bearded region.

Symptoms.—The disease begins as small, rounded, scaly, reddish patches (tinea circinata). The hairs and their follicles soon become invaded with the production of swelling and induration and the appearance of nodular or lumpy tumefactions. Numerous pustules mark the sites of the hair-follicles. These soon rupture and give exit to a yellowish pus, which dries in the form of crusts. The hairs are dry and brittle, and either break off or fall out.

The chin, neck, and submaxillary region are the regions most frequently affected. The upper lip is almost never attacked.

Itching and burning are present in varying degrees.

The disease, when untreated, persists indefinitely. Unless treatment is extremely thorough, relapses are liable to occur.

Etiology.—The disease is due to the invasion of the hair-follicles by the trichophyton fungus. The affection is usually acquired in the barber shop. The disease, however, is not infreqently contracted from horses and cattle. When acquired from such sources, it is apt to be more severe.

FIG. 39.—TINEA SYCOSIS.

Pathology.—Both the hair and the hair-follicles contain the fungus, which consists of threads of mycelium and spores. Secondary inflammation of the follicles and surrounding tissues, with swelling, infiltration, and suppuration, are present in well-marked cases.

Diagnosis.—The chief affection to be differentiated is ordinary sycosis.

FIG. 40.—TINEA SYCOSIS. ×700.—(*After Kaposi.*)

TINEA SYCOSIS.	SYCOSIS.
1. A typical case shows large, lumpy, or nodular tumefactions.	1. A typical case shows small, discrete pustules pierced by hairs.
2. Hairs broken and easily extracted. Root usually dry.	2. Hairs firmly attached until free suppuration occurs. Roots often swollen with pus.

3. Course rapid. Marked changes from week to week.	3. Course slow. Little change from week to week.
4. Upper lip rarely involved.	4. Upper lip frequently involved.
5. Trichophyton fungus in hairs.	5. Absence of fungus in hairs.

Prognosis.—The disease is at times rebellious to treatment, although most cases get well in one or two months. Relapses are common.

Treatment.—The treatment consists of epilation and the use of parasiticide applications. Crusts should be softened with bland oils and then removed with soap and warm water. Epilation of the diseased hairs should be practiced assiduously until all are removed. The healthy areas of the beard should be shaved.

The following applications are all efficient:

℞. Sulphur. præcip., ... ʒj
Petrolat., ... ℥j.

℞. Hydrarg. sulphat. flav., ... gr. xxx
Petrolat., ... ℥j.

℞. Sodii hyposulph., ... ʒj
Aqua, ... f℥j.

℞. Hydrarg. ammoniat., ... gr. xl
Ung. zinci oxidi, ... ℥j.

℞. Hydrarg. chlor. corrosiv., ... gr. j
Aqua, ... f℥j.

These should be applied two or three times a day.

TINEA VERSICOLOR.

Synonyms.—Pityriasis versicolor; chromophytosis.

Definition.—Tinea versicolor is a vegetable parasitic disease, due to the microsporon furfur, characterized by furfuraceous, yellowish, macular patches, occurring chiefly upon the trunk.

Symptoms.—The disease begins as pinhead- to pea-sized yellowish macules scattered over the affected region. These,

in the course of a few weeks or months, increase in size and coalesce, with the production of large patches. The patches are irregular in shape with sharply defined edges. The color

FIG. 41.—TINEA VERSICOLOR.

is usually fawn-hued, although it may vary from a pale yellow to a brown. Occasionally it has a distinct pinkish tint. The affected area is covered with a fine, furfuraceous, mealy

scaling. When this is not apparent it may be made evident by scratching the surface with the finger-nail.

The eruption is usually confined to the trunk, particularly the chest and interscapular region. The neck, axilla, arm, and in rare cases the face, may also become involved. Itching of a mild character is usually present.

FIG. 42.—MICROSPORON FURFUR. ×700.—(*After Kaposi.*)

Tinea versicolor pursues a chronic course, lasting, untreated, for months and years. The disease, with rare exceptions, is confined to adults. It is but slightly contagious.

Etiology.—The disease is due to the presence and growth in the skin of the *microsporon furfur.*

Pathology.—The corneous layer is permeated with a luxuriant growth of mycelium and spores. The mycelium consists of short, jointed, and angular threads, which may be

clear or contain spores. The spores are rounded, highly refractive bodies, varying in size from a nine-hundredth to a three-hundredth of an inch in diameter. In tinea versicolor there is a characteristic tendency of the spores to become aggregated in masses.

Diagnosis.—Tinea versicolor may easily be distinguished from chloasma, vitiligo, and the macular syphiloderm by attention to the character and distribution of the eruption. In doubtful cases the microscope will decide the question.

Prognosis.—The disease responds promptly to treatment. Relapses are not infrequent.

Treatment.—The treatment is rapidly efficient, a few weeks sufficing in most cases to establish a cure.

The treatment consists of friction with soap and hot water (or, better still, sapo mollis), followed by the application of a parasiticide.

Lotions or ointments may be employed. Sulphur, mercury, tar, resorcin, etc., are among the most efficacious remedies.

℞. Sulph. præcip., ... ʒj
Acidi salicylici, ... gr. xx
Adipis benzoat., ... ℥j.
Sig.—Rub in twice a day.

Solutions of hyposulphite of sodium (ʒj to f℥j) and bichlorid of mercury (gr. j-iv to f℥j) are easy of application and eminently useful.

It is well to continue the treatment for some time after apparent cure in order to preclude the possibility of relapse.

TINEA FAVOSA.

Derivation.—*Favus,* a honey-comb.

Synonym.—Favus.

Definition.—Tinea favosa is a contagious vegetable parasitic disease, due to the Achorion Schonleinii, characterized by cup-shaped, sulphur-yellow crusts perforated by hair.

Symptoms.—The usual seat of the disease is the scalp. The disease begins as a diffuse or circumscribed superficial inflammation with scaling, soon followed by the appearance of pinhead-sized, yellowish crusts seated about the hair-follicles. The crusts increase to the size of peas, when they acquire the characteristics of the "favus-cup" or scutulum. The typical favus-cup is split-pea-sized, rounded, umbilicated, penetrated by a hair, and of a sulphur-yellow color. It is usually friable, crumbling between the fingers like dry mortar. When dislodged from its bed there is exposed to view a reddened, shining, atrophic, cup-shaped, often suppurating excavation which heals up with the production of a scar. As a consequence, more or less permanent baldness results.

The crusts may be discrete or confluent, forming thick, irregularly shaped masses of a honey-comb appearance. In well-marked cases, a peculiar mouse-like or damp-straw odor is present, which is quite characteristic of the disease.

The hairs are dry, lusterless, and brittle, and are apt to split longitudinally, break off, or fall out.

Itching, variable in degree, occurs in most cases.

Favus occasionally attacks the non-hairy portion of the body (*tinea favosa epidermidis*). It may also affect the nails (*tinea favosa unguium, onychomycosis favosa*) causing them to become thickened, yellowish, opaque, and brittle.

The course of the disease is extremely chronic, lasting years, and in some cases a lifetime. The affection is contagious, but not to the same extent as ringworm.

Etiology.—The cause of the disease is a vegetable organism known as the *Achorion Schönleinii.* The disease usually begins in childhood. It exists chiefly among the foreign poor. It is not infrequently contracted from cats and other lower animals.

Pathology.—The fungus occurs in the hair, hair-follicles, and epidermis. The favus crust is made up almost entirely

FIG. 43.—TINEA FAVUS OF THE BODY SURFACE. Rare.

FIG. 44.—HAIR SHAFT AND HAIR BULB IN FAVUS. ×700.—(*After Kaposi.*) *a.* Hair bulb. *b.* Root-sheaths, both abundantly infiltrated with fungus.

of fungus. The favus mycelium consists of slender threads, which appear as flattened tubes, either clear or containing spores. The threads are broader and the joints more numerous than in ringworm. The spores are rounded, highly refractive bodies, varying in size from $^1/_{900}$ to $^1/_{400}$ of an inch in diameter. They differ from the spores of ringworm in their greater variability both as to size and shape. Both spores and mycelium are abundant. Secondary inflammatory changes occur in the corium.

FIG. 45.—FUNGOUS ELEMENTS FROM A FAVUS SCUTULUM. ×700.—(*After Kaposi.*)

Diagnosis.—Tinea favosa is to be differentiated from tinea tonsurans and pustular eczema. The sulphur-yellow, cup-shaped, friable crusts, the scarring, the peculiar odor, and the history will usually enable one to make the diagnosis. Absolute proof is afforded by the microscope.

To examine for fungus, a fragment of crust or a hair is moistened in liquor potassæ and examined under a microscope, without preliminary staining.

Prognosis.—Favus of the scalp is extremely rebellious, lasting often for years. In long-standing cases extensive scarring and permanent hair loss are apt to occur. Favus of the body responds readily to treatment.

Treatment.—The treatment of favus of the scalp consists of epilation of the diseased hairs and the use of parasiticide ointments and lotions. The hair should be closely cropped, and the crusts removed by softening with oils and subsequent soap and water cleansing. The systematic extraction of the diseased hairs with an appropriate forceps is an essential part of the treatment. The parasiticide applications should be made twice daily.

Among the more important remedies may be mentioned the following:

℞.	Hydrarg. chlor. corrosiv., ...	gr. iij-iv
	Aqua, ...	f℥j.
℞.	Sulph. præcip., ...	ʒj-ij
	Petrolat., ...	℥j.
℞.	Hydrarg. oleat., ...	10-20 per cent.
℞.	Sodii hyposulph., ...	ʒj
	Aqua, ...	f℥j.
℞.	Chrysarobin.	ʒj
	Petrolat., ...	℥j.

(To be used with caution.)

The treatment is long and tedious, and is apt to tax the perseverance of the patient. The microscope should be repeatedly used before a case is pronounced cured. Treatment should be continued after apparent cure to guard against relapse.

Favus of the body is seldom rebellious, and may be treated with milder remedies than scalp cases. The crusts should be softened and removed and a mercurial or sulphur ointment rubbed in.

Favus of the nails is, as a rule, obstinate to treatment. The nail should be frequently pared and scraped, and parasiticide ointments rubbed in twice daily.

ERYTHRASMA.

Definition.—Erythrasma is a rare vegetable parasitic disease, due to the microsporon minutissimum, characterized by reddish or brownish patches occurring in the axillary, inguinal, and genito-crural regions.

Symptoms.—The disease occurs as small, rounded, or irregular, well-defined, slightly furfuraceous patches of a reddish or brownish color. The axillary, inguinal, genito-crural, and natal folds are the usual regions involved. The disease is slowly progressive and may last for years. It is accompanied by slight itching.

Etiology and Pathology.—The disease is due to the *microsporon minutissimum,* which consists of interlacing, jointed, bifurcating mycelial threads, and according to some, minute spores. The mycelium and spores are about one-third the size of the ringworm fungus.

Diagnosis.—The disease may be distinguished from tinea versicolor by the absence of the eruption on the trunk, the redder color of the lesions, and the differences in the microscopic appearances.

Treatment.—The disease is amenable to the same treatment that is prescribed for tinea versicolor.

ACTINOMYCOSIS.

Derivation.—*Ἀκτίς*, ray; *μύκης*, mushroom.

Synonym.—Lump-jaw.

Definition.—Actinomycosis is a parasitic disease occurring in the lower animals and man, due to the ray fungus and

characterized by deep subcutaneous tumors or swellings which break down and suppurate.

Symptoms.—The face and neck are the parts usually involved, the parasite gaining entrance to the tissues around

FIG. 46.—A MASS OF ACTINOMYCES SHOWING THE RAY ARRANGEMENT.—(*After Ponfick.*)

carious teeth. The onset of the disease is insidious, weeks or months elapsing before the appearance of cutaneous manifestations.

The lesions consist of deep-seated tumors or swellings

which, approaching the surface, become red or livid in color, and, breaking down, discharge a bloody sero-pus containing characteristic yellow granules. These granules are made up almost exclusively of fungus. Sinuses with uneven nodular edges persist for an indefinite period.

Etiology and Pathology.—The disease is due to the invasion of the organism by the *actinomyces,* or "ray fungus." The fungus consists of club-shaped threads radiating from a common center.

Treatment.—The administration of large doses of potassium iodid has proven successful in many cases and should be given thorough trial. Locally, irrigation with corrosive sublimate solutions is advised. In obstinate cases the parts should be thoroughly curetted.

MYCETOMA.

Derivation.—*Μύκης*, a fungus.

Synonyms.—Podelcoma; fungus foot of India; Madura foot.

Definition.—Mycetoma is an endemic disease, due to the presence of a vegetable fungus, characterized by disintegration of the tissues chiefly of the foot and hand.

Symptoms.—The disease occurs most frequently in India. In a typical case the foot is swollen and infiltrated and beset with pea- to nut-sized tubercles or nodules. These break down with the formation of sinuses which connect with the deeper structures and which give exit to a thin, sero-purulent fluid containing whitish or blackish granules.

The course is chronic, the disease lasting for years.

Treatment.—Complete removal by means of the knife or curet is the only successful treatment.

SCABIES.

Derivation.—*Scabere,* to itch.

Synonym.—Itch.

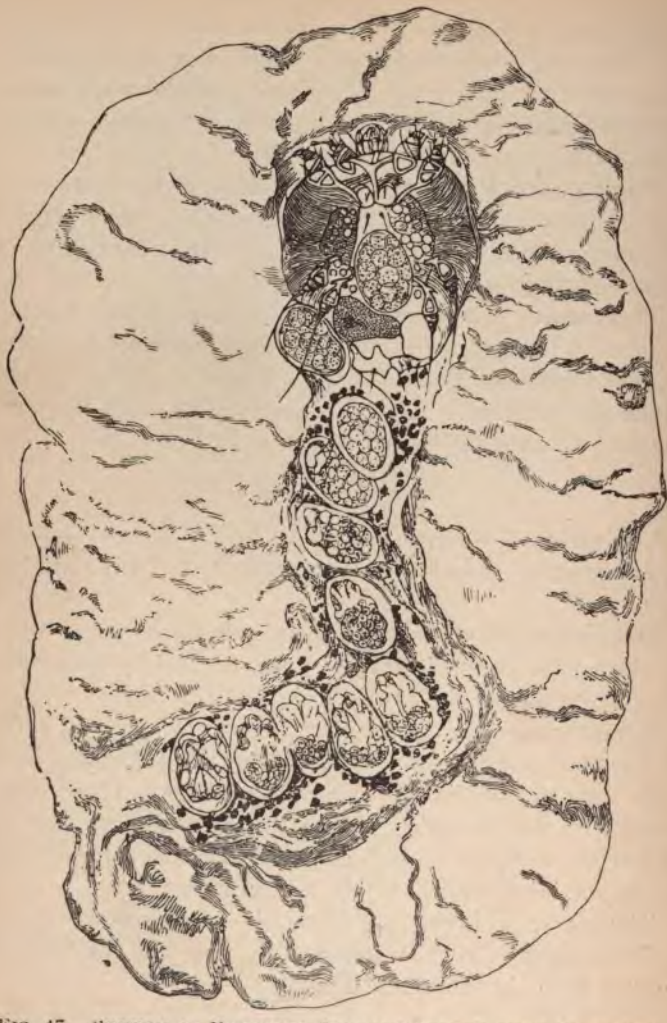

FIG. 47.—SECTION OF EPIDERMIS SHOWING BURROW WITH CONTAINED PARASITE AND OVA.

Definition.—Scabies is a contagious animal parasitic disease, due to the sarcoptes scabiei, characterized by burrows and a multiform eruption, and attended by severe itching.

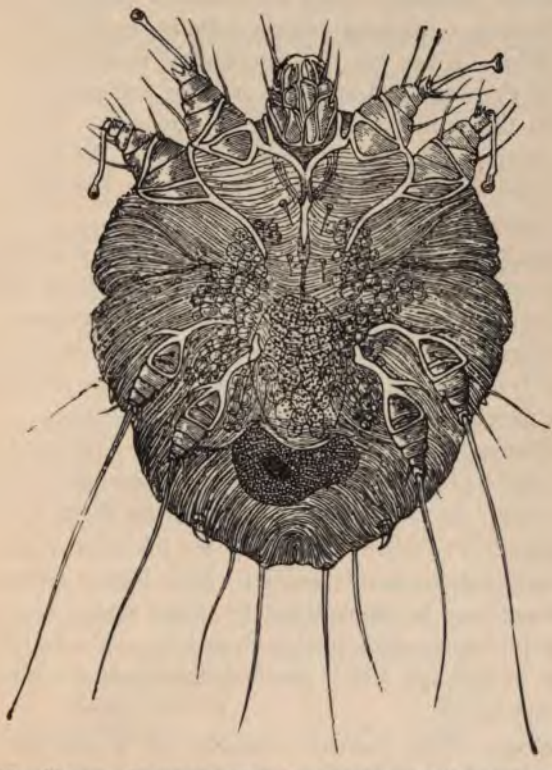

FIG. 48.—MATURE PREGNANT FEMALE ACARUS. ×300.—(*After Kaposi.*)

Symptoms.—The itch mite in burrowing into the skin produces at the point of entrance a small papule, vesicle or pustule. Later, a burrow or cuniculus is formed at this site. The burrow is a straight, tortuous or zigzag, grayish or

blackish, linear, epidermal elevation varying in length from ⅛ to ½ of an inch.

In a well-marked case of itch there may be seen, in addition to the burrows, a multiform eruption consisting of papules, vesicles, pustules, crusts, excoriations (scratch marks), and thickening, occupying certain definite regions where the skin is thin. These are the interdigital spaces, the flexor surface of the wrist and arm, the anterior and posterior axillary folds, the mammæ and nipples (in women), the umbilicus, the buttocks, the penis, the inner side of the thighs and legs and the toes (particularly in infants). The face is exempted except occasionally in infants.

The eruption is attended by intense itching, which is distinctly worse at night. The irresistible scratching leads to the production of the secondary inflammatory symptoms.

In children and individuals with sensitive skin the eruption may reach a high grade of inflammation. In predisposed subjects an eczema may be superadded to the scabies.

The disease develops rapidly in the course of one to two weeks. It is progressive, exhibiting no tendency to spontaneous cure. In untreated cases it may last many months.

Etiology.—The disease is due to the invasion of the skin by the *sarcoptes* or *acarus scabiei.* It is highly contagious. The disease may be transmitted by direct bodily contact or through the intermediation of such articles as the bedclothes. It occurs at any age and is particularly common among the lower classes.

Pathology.—The burrow consists of a narrow tract through the epidermis made by the penetration of the inpregnated female acarus. The mite deposits a half dozen or more eggs and specks of excrement along the course of the tract, and, after reaching the mucous layer, perishes. The ova hatch out in eight or ten days and, effecting their egress from the burrow, start cuniculi of their own.

The itch-mite is a yellowish-white ovoid body just about visible to the eye. The female is twice the size of the male.

Diagnosis.—Scabies consists of the burrows plus an artificial inflammation of the skin produced by the parasite and the scratching.

The characteristic features of the disease are the presence of the burrows, a multiform eruption distributed in a peculiar manner over the surface of the body, the intense itching worse at night, and the history.

Scabies may be distinguished from vesicular or pustular eczema by the presence of the mite and the burrows, the peculiar distribution of the lesions, the progression of the eruption from day to day, and the history of contagion.

From pediculosis corporis the disease may be differentiated by the character of the eruption and the regions affected.

Prognosis.—Favorable. The disease, no matter of what duration, is speedily curable.

Treatment.—The objects of treatment are twofold—to kill the parasite and to subdue the accompanying dermatitis. The itch-mite is easily destroyed by such remedies as sulphur, betanaphthol, balsam of Peru, styrax, tar, staphisagria, etc.

Sulphur is one of the most reliable remedies and is best applied in ointment form. It may be used in conjunction with balsam of Peru, as in the following formula:

℞.	Sulph. præcip.,	ʒj-ij
	Balsam peruv.,	ʒss-j
	Adipis,	℥iss.

Betanaphthol possesses the advantage of being free from odor and more cleanly. It may be used alone (ʒj to ℥j) or combined with sulphur.

Styrax is less irritating than sulphur and is useful in the itch of children:

℞.	Styracis liq.,	℥ss
	Adipis,	℥iss.

Danish Treatment page 799
Dec Sept. 1924 Int. Med Digest

The treatment is to be inaugurated by a protracted hot bath with the vigorous use of soap. The body from neck to foot is then to be thoroughly anointed with the ointment. This may be rubbed in twice a day for three days or nightly for one week. At the end of this time another bath should be taken and the underclothing and bed linen changed and sterilized. Ordinarily, such a treatment will suffice to produce a cure; occasionally, it must be repeated.

Care should be exercised not to *overtreat* cases. The persistence of itching is not always an index of the continuance of the scabies, but is more likely to result from the dermatitis which is, perhaps, being aggravated by the parasiticide application. In such a case a sedative ointment or lotion should be substituted.

PEDICULOSIS.

Derivation.—*Pediculus,* a little foot.

Synonyms.—Lousiness; phthiriasis.

Definition.—Pediculosis is a contagious animal parasitic disease, characterized by the presence of the pediculi, hemorrhagic points and scratch marks.

Symptoms.—There are three varieties:

1. Pediculosis capitis.
2. Pediculosis corporis.
3. Pediculosis pubis.

Pediculosis Capitis.

Pediculosis capitis or capillitii is due to the invasion of the scalp by the pediculus capitis, or head-louse.

It is characterized by severe itching, which excites scratching and leads to the formation of excoriations with serous, purulent or sanguineous exudation. This dries in the form of crusts and mats the hair together. A foul odor is usually present. Owing to the irritation the post-cervical glands may become enlarged and in some cases suppurate. The occipital region is the most frequent seat of this pustular dermatitis.

Scattered papules, pustules, and excoriations are frequently seen about the face and neck.

Pediculi are present in varying numbers, and ova or "nits" in abundance. Ova are grayish, translucent, pyriform bodies attached to the hair by a membranous sheath. They hatch out in from three to eight days. Pediculosis capitis is far more common in children than in adults.

Diagnosis.—Owing to the presence of the pediculi and the "nits," the diagnosis is, as a rule, easy. Every pustular eczema in the occipital region should be regarded with suspicion, and warrants a search for pediculi and ova.

Treatment.—The object of treatment is to kill the pediculi, devitalize the ova, and subdue the accompanying inflammation. Among the most popular and efficacious remedies is petroleum, either pure or with equal parts of olive oil and balsam of Peru. It should be thoroughly applied to the scalp for one or two nights, followed in the morning by a shampoo of the scalp with

1 Fric Coal.
2 Coal oil + olive oil
3 Bichl 1-3000 wash for week

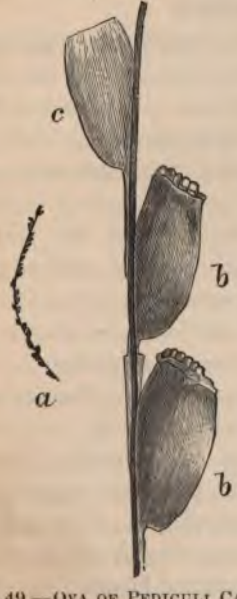

FIG. 49.—OVA OF PEDICULI CAPITIS. *a.* Hair with numerous ova upon it *b. b.* Magnified ova attached to hair: operculum attached. *c.* Empty ovum, operculum fallen off.

FIG. 50.—MALE PEDICULUS CAPITIS. (*After Kuechenmeister.*)

soap and water or tincture of green soap. Other remedies, such as tincture of cocculus indicus, fluid extract of staphisagria (f℥ij to f℥iv dilute acetic acid), or corrosive sublimate (gr. j-iv to f℥j), may be employed.

Where there is much pustulation and crusting the following ointment may be applied:

℞.	Hydrarg. ammoniat., ...	gr. xxx
	Petrolati, ...	℥j.

For the removal of "nits," alkaline solutions (such as carbonate of soda, borax, etc.) or acid solutions (dilute acetic acid) should be frequently applied.

There is rarely need of sacrificing the hair in women, although this may be done in children.

Pediculosis Corporis.

This is produced by the pediculus corporis or vestimenti, a parasite larger than the scalp louse. It resides in the seams of the underclothing, where the ova are deposited. They hatch out in about six days. The louse is merely present upon the skin when foraging.

Fig. 51.—Female Pediculus Corporis.—(*After Kuechenmeister.*)

The perambulation of the parasite produces intense itching, which gives rise to violent scratching. As a result, linear scratch marks, blood crusts, and in chronic cases pigmentation and thickening may be seen. The parts affected are those coming in contact with the seams of the undergarments—namely, the scapular region, the chest, waist and thighs. Hemorrhagic puncta mark the sites from which pediculi have extracted blood.

The disease is common among the poorer classes in adults of middle or advanced age. It is rare in children.

Diagnosis.—The characteristic features are the presence of excoriations, nail marks, blood crusts, and hemorrhagic puncta upon the scapular region and around the waist. Careful search in the seams of the undergarments will usually reveal the existence of the pediculi.

Treatment.—The most important part of the treatment is the disinfection of the clothes and the bed linen. These should be thoroughly boiled or baked.

A lotion of carbolic acid or thymol will relieve the itching quite effectually.

Where disinfection of the clothing can not be carried out it is best to prescribe an ointment of sulphur (ʒj to ℥j) or staphisagria (ʒij to ℥j).

Pediculosis Pubis.

The pediculus pubis, or crab louse, is responsible for this form. It is the smallest of the pediculi, and is found clinging tenaciously to the hair, with the head buried in the follicular orifice. The "nits" are seen attached to the hair shaft.

Fig. 52.—Pediculus Pubis.—(*After Schmarda.*)

Itching about the genitalia, variable in degree, is the most prominent symptom. Hemorrhagic puncta, papules, and excoriations may also be present.

The pubis and perineum are the usual regions involved. Occasionally the axillæ and sternal region are attacked, and in rare cases the beard, eyebrows, or eyelashes.

The disease is almost exclusively observed in adults, and is usually contracted during sexual intercourse.

Diagnosis.—The diagnostic features are itching about the genitalia and the presence of pediculi and ova.

Treatment.—The parts should be washed with soap and water twice daily. Lotions, being more cleanly than ointments, are to be preferred. Corrosive sublimate, the tincture of cocculus indicus or the fluid extract of staphisagria are all excellent applications:

℞. Hydrarg. bichlorid., ... gr. j.
or
Ext. staphisagriæ fld., ... f℥ij
Acidi acetici dil., ... f℥vj.

White precipitate (℥j-℥j) or mercurial ointment are both effective. Vinegar, dilute acetic acid, and soda and borax solutions are of value in effecting the removal of the nits.

CYSTICERCUS CELLULOSÆ CUTIS.

Symptoms.—*Cysticerci* are occasionally observed in the skin as rounded, firm, elastic, pea- to walnut-sized tumors. They occur upon the trunk and extremities, where they may remain unchanged for years.

They are to be distinguished from gummata, sarcomata, etc. The contents, under the microscope, are seen to contain the parasites.

DRACUNCULOSIS.

Synonyms.—Filaria medinensis; Guinea worm.

Symptoms.—The lesions, which consist of pea-sized or larger vesico-papules, are due to the presence of the *dracunculus medinensis.* The worms may at times be felt beneath the skin as a coil of soft string. They are swallowed in their larval form in drinking water, and migrating through the tissues, endeavor to effect an exit through the skin. The foot is the region usually affected.

The mature female is a cylindric nematode, twenty-five to thirty inches in length, and one-tenth of an inch wide. The disease is met with only in tropical countries.

Treatment.—The best treatment is the injection of a solution of 1 : 1000 bichlorid of mercury, followed in a few days by incision and extraction of the dead worm.

IXODES.

Synonym.—Wood-tick.

Symptoms.—These parasites reside but temporarily upon the skin. The proboscis of the tick is inserted into the skin for the purpose of sucking the blood. The animal may thus remain for several days, until the body swells to the size of a pea or bean.

Treatment.—Forcible attempts at removal of the invader should be avoided, as the mandibles might thus be detached in the skin, giving rise to pain and subsequent inflammation. A drop of turpentine or benzine placed upon the head kills the parasite, thus causing it to relinquish its hold.

FIG. 53.—LARVA OF THE LEPTUS. — (*Kuechenmeister.*)

LEPTUS.

Synonyms. — Harvest-bug; leptus autumnalis; mower's mite.

Symptoms.—The *leptus* is a minute, brick-red or yellowish-red insect found in summer and autumn upon bushes and grass. It attacks man by burying its head in the follicular orifices, particularly of the lower limbs.

Treatment.—This consists in the application of carbolized oil, balsam of Peru, sulphur ointment, etc.

ŒSTRUS.

Synonyms.—Gad-fly; bot-fly.

Symptoms.—The larvæ or ova of the gad-fly are deposited in the skin by the adult insect. A painful furuncular swelling occurs which goes on to suppuration. The larvæ

may be expressed with the pus. The affection is common in the tropics.

Treatment.—The furuncular openings should be syringed with a solution of carbolic acid.

PULEX PENETRANS.

Synonyms.—Sand-flea; jigger.

Symptoms.—The minute sand-flea penetrates the skin usually at the toes, giving rise in about a week to painful edema, pustulation, and at times ulceration and gangrene.

The affection is confined to tropical countries.

Treatment.—The insect should be extracted with a blunt needle. The application of chloroform will kill the parasite.

PULEX IRRITANS.

Synonym.—Common flea.

Symptoms.—The flea-bite consists of a hemorrhagic punctum with an erythematous halo. In individuals with sensitive skin a wheal develops.

Treatment.—Lotions of ammonia, thymol or carbolic acid.

CIMEX LECTULARIUS.

Synonym.—Bed-bug.

Symptoms.—This parasite preys upon the skin, sucking the blood of the individual attacked. An inflammatory papule or wheal with a central hemorrhagic punctum marks the site of the bite.

Treatment.—Consists of applications of ammonia water, carbolic acid solution, etc.

CULEX.

Synonyms.—Gnat; mosquito.

Symptoms.—The lesion produced by the mosquito consists of an erythematous spot or a wheal.

Treatment.—A solution of carbolic acid or ammonia will relieve the itching.

CLASS IV.—HEMORRHAGIAE—HEMORRHAGES.

PURPURA.

Derivation.—*Πορφύρα*, purple.

Definition.—Purpura is a hemorrhagic disease characterized by the appearance on the skin of variously sized and shaped reddish-purple macules, not disappearing under pressure.

Symptoms.—There are three chief varieties, distinguished by the premonitory and concomitant constitutional symptoms, by the extent of hemorrhagic extravasation, and by the cause:

1. Purpura simplex.
2. Purpura rheumatica.
3. Purpura hemorrhagica.

Purpura Simplex.

The eruption usually comes out suddenly and consists of pinhead- to pea-sized, round, oval, or irregular claret-redin claret-red or purplish spots. They are circumscribed, smooth, and non-elevated, and are symmetrically distributed, tending particularly to occur upon the lower extremities. Subjective symptoms are, as a rule, absent. There is commonly no systemic disturbance, and the disease tends to a favorable termination in the course of a few weeks.

Purpura Rheumatica (*Peliosis Rheumatica*).

This form is ushered in with fever, lassitude, anorexia, and severe rheumatoid pains, particularly in the lower extremities, the joints of which may be swollen. The eruption consists of well-defined, split-pea- to fingernail-sized hemorrhagic patches, which may be slightly elevated or level with the skin. At first of a pinkish, reddish, or purplish color, they later pass through the color transitions of all ecchy-

moses. The eruption is more or less generalized, but is most marked upon the extremities. The disease may last a few weeks, or persist, in the form of relapses, for several months. It is sometimes associated with erythema multiforme.

PURPURA HÆMORRHAGICA (*Morbus maculosus Werlhofii; land scurvy*).

The onset of the hemorrhagic form is signalized by the occurrence of fever and symptoms of systemic depression. The eruption consists of hemorrhagic patches varying in size from a small coin to the palm of the hand, which come out suddenly and in considerable numbers. The trunk and extremities are the regions usually involved. At the same time bleeding from the mouth, gums, nostrils, bowels, bladder, etc., may take place. The disease may terminate in a fortnight or may continue for weeks. In a certain number of cases it proves fatal.

Etiology.—The causes of purpura are obscure. This disease, especially the hemorrhagic type, occurs more often in debilitated individuals. Some look upon the vasomotor apparatus as the agency primarily at fault; others believe purpura to be an infectious disease. Such drugs as arsenic, potassium iodid, chloral, quinin, and the salicylates may produce hemorrhagic eruptions.

Pathology.—As a result of an alteration in the blood or blood-vessel walls, an extravasation of blood takes place into the tissues. After a variable period of time this undergoes resorption, the changes in the blood-pigment producing the varying colorations. The process is not attended with inflammation.

Diagnosis.—The evident hemorrhagic nature of the lesions and their failure to disappear upon pressure distinguish them as purpuric. Purpura hæmorrhagica may be confounded with scorbutus:

Scorbutus.	Purpura Hæmorrhagica.
1. Occurs in those subject to lack of vegetable food and to bad hygiene.	1. No such etiologic relationship.
2. Definite antecedent symptoms: weakness, impaired circulation, etc.	2. Antecedent signs slight or absent.
3. Onset slow.	3. Onset sudden.
4. Gums spongy, swollen, and bleeding; teeth loose.	4. Gums often bleeding but not swollen.
5. Severe muscular pains.	5. Less marked.
6. Brawny infiltration of lower extremities.	6. Not present.
7. Hemorrhages from mucous membranes not as a rule profuse.	7. Hemorrhages from mucous membranes often so severe as to prove fatal.

Prognosis.—In purpura simplex and rheumatica the prognosis is favorable, recovery taking place in several weeks or months. In purpura hæmorrhagica the prognosis is more guarded, a certain number of cases succumbing to internal hemorrhage.

Treatment.—The treatment of purpura must be adapted to the exigencies of the individual case. Ergot, tincture of the chlorid of iron, quinin, turpentine, and the mineral acids are useful in all forms of the disease. In purpura rheumatica and hæmorrhagica the patient should be confined to his bed and placed upon a nutritious and easily assimilable diet. Locally, astringent lotions and ice, if necessary, may be employed.

CLASS V.—HYPERTROPHIAE—HYPERTROPHIES.

LENTIGO.

Derivation.—*Lens*, a lentil.

Synonyms.—Freckles; ephelides.

Definition.—Lentigo consists of pinhead- to pea-sized,

yellowish, brownish or blackish spots of pigment, occurring chiefly on the face and hands.

Symptoms.—The lesions, commonly known as freckles, are pinhead- to pea-sized, round, oval or irregular, and of a yellowish, brownish or blackish color. They occur chiefly upon the face and the backs of the hands, although they are occasionally observed on the trunk. They are more common during adolescence than at any other period, and are most marked in individuals of blond complexion, particularly red-haired subjects. They ordinarily make their appearance during the summer, and fade partially or completely during the cold seasons.

Etiology.—The condition is due to exposure to the light and heat of the solar rays. Some writers believe that a congenital predisposition is necessary.

Pathology.—Freckles are due to an increased deposition of pigment in circumscribed areas of cells in the basal layer of the epidermis.

Prognosis.—A disappearance of the freckles may be brought about by treatment, but they are extremely apt to return.

Treatment.—The object of treatment is to produce an exfoliation of the epidermal cells containing the pigment. For this purpose solutions of corrosive sublimate, acetic acid, and like preparations are used. Bulkley advises the following:

℞.	Hydrarg. chlor. corrosiv., . . .	gr. vj	
	Acidi acetic. dil., ...	f℥ij	
	Boracis, ...	gr. xl	
	Aq. rosæ, ...	f℥iv.	M.

Sig.—Apply night and morning; at first gently, later vigorously.

Hardaway obtains satisfactory results from the use of the *electrolysis needle.*

CHLOASMA.

Derivation.—*Χλοάζειν*, to be pale green.

Definition.—Chloasma is characterized by yellowish, brownish or blackish pigmentation of the skin, occurring in variously sized and shaped patches or as a diffuse discoloration.

Symptoms.—The patches may be any size from a coin to the palm of the hand or larger. They are irregular or rounded, with fairly defined borders. They are usually fawn-colored, yellowish, brownish or blackish (melanoderma). In the diffuse form the color merges imperceptibly into the surrounding skin.

The affection is most frequently seen upon the face.

Etiology.—There are two varieties:

1. Idiopathic chloasma, due to external causes.
2. Symptomatic chloasma, due to internal causes.

Under *idiopathic chloasma* may be included all of the pigmentations that result from the use of local irritants, such as sinapisms, blisters, scratching, pressure, friction, solar rays, etc.

Symptomatic chloasma includes in its category the pigmentation seen in association with visceral and general diseases, such as uterine disease and pregnancy, Addison's disease, tuberculosis, cancer, malaria, etc. In these cases the pigmentation is usually diffuse and may involve large areas of cutaneous surface.

Chloasma Uterinum.—This is most commonly seen during pregnancy, although it is often observed in pathologic conditions of the uterus and the ovaries. The patches are yellowish or brownish in color, and are usually located about the forehead and eyelids.

In *Addison's disease* the pigmentation is of a brownish, olive-greenish, or bronze tint. The prolonged administra-

tion of *silver* may produce a permanent bluish-gray or slate-colored discoloration of the skin (*argyria*).

A diffuse brownish pigmentation results in rare cases from the long continued use of *arsenic*.

Pathology.—The only change is an increased deposition of pigment in the mucous layer of the epidermis. It is not improbable that pathologic conditions of the sympathetic nervous system play an important rôle in symptomatic chloasma. Thus, in pigmentation resulting from affections of the abdominal viscera the solar plexus is probably implicated.

Diagnosis. Chloasma may be distinguished from tinea versicolor by the presence of the former upon the face, the paucity of the patches, the absence of furfuraceous scaling, and the absence of a fungus parasite.

Prognosis. Depends upon the removability of the cause. Local applications have, as a rule, but a temporary influence.

Treatment. If the pigmentation be due to a systemic cause, this should naturally be treated.

Locally the same measures are employed as in the treatment of lentigo. Duhring recommends:

℞. Hydrarg. chlor. corrosiv., . . . gr. vj
Tr. benzoin. comp., ... f℥iss
Emuls. amygdal. amar., . . . f℥iij. M.
Sig. Apply night and morning.

Or the following ointment, recommended by Kaposi, may be employed:

℞. Hydrarg. ammoniat.,
Sodæ biborat., ... āā ʒj
Ol. rosmarin., ... ♏x
Ung. simpl., ... ℥j.

NÆVUS PIGMENTOSUS.

Derivation.—*Nævus*, a mark.

Synonym.—Pigmentary mole.

Definition.—A circumscribed pigmentary deposit, usually

congenital, with or without associated hypertrophy of other cutaneous structures.

Symptoms.—A "mole" may consist merely of a circumscribed deposit of pigment, or there may be in addition, hypertrophy of the papillæ, of the hairs, and of the connective tissue. Nevi vary in size from a pea to the palm of the hand or larger, are rough or smooth, elevated or non-elevated, and of a brownish or blackish color.

According to the cutaneous structures involved, various forms of pigmentary nevi are distinguished.

Nævus spilus is a term given to a smooth, flat, pigmented nevus devoid of hair.

Nævus pilosus is a pigmented nevus covered with a growth of downy or stiff hairs.

Nævus verrucosus is a pigmented nevus with an irregular or wart-like surface.

Nævus lipomatodes is an elevated pigmented nevus with connective tissue and fat hypertrophy.

Etiology.—Obscure. Hairy moles are apt to be congenital, non-hairy ones acquired.

Pathology.—There is increased pigment deposit in the cells of the rete mucosum and also in the corium. In nævus verrucosus the papillæ are greatly hypertrophied. There is often more or less connective tissue hypertrophy.

Treatment.—The growths may be removed by means of the knife, caustics or electrolysis. The last named is particularly useful in the treatment of hairy moles.

CALLOSITAS.

Derivation.—*Callus,* hard flesh.

Synonyms.—Callus; callosity; tylosis.

Definition.—Callositas consists of hard, circumscribed thickenings of the epidermis, usually involving the hands and feet, and due to hypertrophy of the stratum corneum.

Symptoms.—The condition occurs as slightly elevated, dense, horny patches of variable size, grayish or yellowish in color. The favorite seats are the palms, soles, fingers, and toes. Inflammation is, as a rule, absent, although it may be present and terminate in abscess. When located upon the soles considerable pain in walking is often caused.

Etiology.—The cause of callus is the continued application of pressure or friction; upon the hands, from the use of various tools; upon the feet, from improperly fitting shoes.

Pathology.—The condition is due to a hypertrophy of the horny layer of the epidermis.

Treatment.—When treatment is desired, the hardened skin may be pared off with a sharp knife, after preliminary softening by means of hot water or poultices. Instead of this, a ten to twenty-five per cent. salicylic acid plaster may be worn for several weeks. The plaster should be changed daily and the softened epidermis removed. An efficient treatment is cauterization with a stick of nitrate of silver two or three times a week, the hardened skin being shaved off at each application.

In occupation callosities, change of work is often followed by spontaneous involution.

CLAVUS.

Derivation.—*Clavus*, a nail.

Synonym.—Corn.

Definition.—Clavus is a small, circumscribed, deep-seated, painful, horny growth, usually situated upon the toes.

Symptoms.—The usual seat of corns is the dorsal surface of the toes. They are pea-sized, rounded, dense, horny formations, and may be single or multiple. Occurring between the toes, maceration of the epidermis takes place with the production of a *soft corn*. Corns are painful upon pressure, and often spontaneously painful.

Etiology.—Continued pressure or friction from improperly fitting shoes.

Pathology.—There is hypertrophy of the horny layer, as in callus; but there is also a central conical core, the apex of which rests upon the papillary layer of the skin. It is on account of the latter condition that pressure produces pain.

Treatment.—The removal of the cause and the use of properly fitting footwear are important therapeutic measures.

Corns may be removed by paring off the hypertrophied epidermis, after having previously softened it with soap and hot water. The central core may be excised with a small scalpel. To prevent return, a perforated felt plaster should be worn and daily soaping of the part resorted to.

Instead of using the knife, keratolytic substances, such as salicylic acid, may be used. This may be used as a plaster or in collodion:

℞.	Acidi salicylici, ...	ʒj
	Ol. ricini, ...	♏x
	Collodii, ...	f℥j.

The collodion should be painted on twice a day, a hot foot bath being taken every few days to remove the softened epidermis. Soft corns may be treated with the stick of nitrate of silver and the interposition of absorbent cotton.

CORNU CUTANEUM.

Derivation.—*Cornu,* a horn.

Synonym.—Cutaneous horn.

Definition.—Cornu cutaneum is a circumscribed horny outgrowth of the skin of variable size and shape. The condition is very rare.

Symptoms.—Cutaneous horns are hard, dry, laminated excrescences, not differing materially from the horns of lower animals. They are grayish, yellowish or brownish in color, usually conical and tapering, and are apt to be curved or

twisted rather than straight. They are commonly small, about one inch in length, although horns twelve inches long have been observed. They are usually single.

The horn is concave at its skin insertion, the concavity resting upon normal or hypertrophied papillæ. There is, as

FIG. 54.—CUTANEOUS HORNS.—(*After Van Harlingen.*)

a rule, no pain unless the part is injured, when inflammation and suppuration may result. When the horn is shed, as occasionally takes place, reformation usually occurs. Quite a proportion of cases terminate in epithelioma.

The scalp and face are the seats of predilection.

Etiology.—The causes are not known. The condition rarely occurs before the age of forty. Horns may have their origin in sebaceous cysts, warts or scars.

Pathology.—Horns are made up of densely laminated corneous cells arranged concentrically in columns. The growth has its origin in the rete mucosum; the papillæ at the base are often hypertrophied. Epitheliomatous degeneration not infrequently takes place.

Treatment.—Extirpation, followed by cauterization of the base.

ICHTHYOSIS.

Derivation.—*Ἰχθύς*, a fish.

Synonyms.—Fish-skin disease; xeroderma.

Definition.—A congenital chronic hypertrophic disease, characterized by dryness and scaliness of the skin and a variable amount of papillary hypertrophy.

Symptoms.—Two forms of the disease are distinguished, ichthyosis simplex and ichthyosis hystrix.

Ichthyosis simplex is the common variety encountered. There may be merely dryness and harshness of the skin, with fine, furfuraceous scaling (*xeroderma*). Frequently, however, the disease is more marked, exhibiting variously sized reticulated scales, which may be small and thin or large and thick, resembling fish-scales. Upon the arms and legs the epidermis forms diamond-shaped or polygonal plates, bounded by the natural furrows of the skin.

Ichthyosis hystrix is a rarer and more severe variety. It is characterized by papillary hypertrophy, showing itself clinically as irregular or linear, corrugated, warty or spinous, horny patches.

Ichthyosis simplex involves more or less the entire body-surface. It is most marked, however, upon the extensor surfaces of the arms and legs. Ichthyosis hystrix affects only

[illegible] of the skin, such as the arm, neck, scalp, [illegible], etc.

The course of ichthyosis is extremely chronic. The disease begins usually in the first or second year of life, increases in severity until adult age is reached, and then re-

FIG. 55.—ICHTHYOSIS.—(After Jackson.)

mains stationary, thus continuing throughout the patient's lifetime.

Ichthyosis is markedly influenced by the seasons. It is always worse in cold than in hot weather. In the spring and summer, when perspiration is increased, great improvement takes place.

The disease is not inflammatory, and there is, as a rule, no itching. It is, however, not infrequently complicated by eczema.

Etiology.—Ichthyosis is a congenital disease, although it does not, as a rule, manifest itself before the first or second year. An hereditary influence excites in many cases.

Pathology.—The pathologic process consists of a hyperplasia of the cells of the corneus and mucous layers of the epidermis. The papillary layer of the corium is in many cases also hypertrophied.

Diagnosis.—The characteristic features of ichthyosis are: the harsh, dry skin; furfuraceous scales and polygonal plates; the localization of the eruption; the history and the absence of inflammatory symptoms.

Prognosis.—The prognosis is unfavorable as to cure. Considerable relief, however, may be afforded by proper treatment.

Treatment.—Internal treatment is of little or no value. External treatment is to be solely relied upon. This has for its object the removal of the epidermal scales and the softening of the skin with unguentous substances.

Baths are of great value and are to be employed frequently. Either a simple warm bath or an alkaline bath (sodium bicarb., ℥iv-℥viij to bath) may be used. In mild cases frequent bathing followed by the inunction of some oily or fatty substance will be all-sufficient. For this purpose, petrolatum, adeps, olive oil, oil of sweet almonds, diluted glycerin, etc., may be employed. A simple and efficient inunction consists of:

℞. Lanolini,
Petrolati, ... āā ℥j.

In severe cases the following plan is advised: Friction with soft soap twice daily for four or five days, followed by a bath and the inunction of a simple ointment.

Iodid of potassium in ointment form has been highly spoken of.

℞. Potass. iodid., ... gr. xx
Olei bubuli,
Adipis, ... āā ℥ss
Glycerinæ, ... f℥j. M.
Ft. ung.

—*Milton.*

In ichthyosis hystrix, caustics, the Paquelin cautery or the knife may be necessary to remove the hypertrophic tissues.

VERRUCA.

Derivation.—*Verruca,* an excresence.

Synonym.—Warts.

Definition.—Verruca consists of a pinhead- to bean-sized circumscribed elevation of the skin due to epidermal and papillary hypertrophy.

Symptoms.—Various forms of warts are distinguished.

Verruca Vulgaris.—This is the common wart seen upon the hands. It is a pea-sized, rounded, rough or smooth, broad-based elevation, yellow or brownish in color. It may occur singly or in numbers.

Verruca Plana.—This is distinguished from the ordinary wart by being flat and broad. Flat warts are pea- or finger-nail-sized, but slightly elevated, and of a brownish or blackish color. They occur in numbers, usually upon the backs of elderly individuals (verruca senilis). Occasionally numerous small flat warts occur upon the face, developing with considerable rapidity.

Verruca Filiformis.—These warts are slender, thread-like outgrowths about one-eighth of an inch in length, occurring chiefly upon the face, eyelids, and neck.

Verruca Digitata.—These are slightly elevated pea- to finger-nail-sized excrescences, with numerous digitations branching out from the base. The scalp is the most common site.

Verruca Acuminata (*Pointed Condyloma, Venereal Warts*).—These are pinkish or reddish, sessile or pedunculated, pointed vegetations occurring about the muco-cutaneous surfaces (penis, labia, anus, mouth, etc.) of young individuals. Occurring upon the genitals, they are bathed in an offensive puriform secretion. These warts grow rapidly, not infrequently reaching the size of an egg. They bear at times strong resemblance to a raspberry, cauliflower, or cockscomb.

Etiology.—It is probable that at least some forms of warts are due to micro-organisms, and that they are auto-inoculable and contagious.

Venereal warts are caused by contact with irritating secretions which contain, in all probability, the causal micro-organism.

Pathology.—Warts consist of a hyperplasia of the papillæ of the corium and the overlying layers of the epidermis. A vascular loop is found in the center of each wart.

In the acuminate variety the connective tissue and vascular hypertrophy is marked, while the horny layer is but slightly hyperplastic.

Treatment.—Warts may be removed by caustics, excision, erasion, or electrolysis. The best caustics to be employed are nitric acid, caustic potash, chromic acid, or glacial acetic acid. These should be cautiously applied from time to time until the disappearance of the wart. An excellent method is to scrape away the wart with a curet and apply the stick of nitrate of silver to the base.

Salicylic acid in collodion or alcohol is often successful in causing the disappearance of warts.

℞. Acidi salicylici, ... ʒj
Spts. vini rect., ... f℥j.
Sig.—Apply two or three times a day.

Or—

℞. Acidi salicylici, ... ʒj
Collodii flex., ... f℥j.
Sig.—Apply twice a day.

The use of a 1 : 500 corrosive sublimate solution is sometimes efficacious, as is also an alcoholic solution of resorcin thirty grains to the ounce.

Filiform or digitate warts may be snipped off with a curved scissors, the base being subsequently cauterized.

Venereal warts may be washed with solutions of alum, tannin, or chlorinated soda, and then dusted with calomel, or they may be cauterized with nitric, carbolic, or chromic acid. Cleanliness should be rigorously enjoined.

MOLLUSCUM EPITHELIALE.

Derivation.—*Molluscus,* soft.

Synonym.—Molluscum contagiosum.

Definition.—Molluscum epitheliale is an epithelial disease characterized by pinhead- to pea-sized or larger, smooth, semi-globular, waxy-white or pinkish elevations.

The disease is uncommon.

Symptoms.—The lesions are discrete, usually split-pea-sized, of the color of the skin or pinkish, with often a distinct waxy appearance. The summits are somewhat flattened and contain a central, darkish opening from which a cheesy secretion may be expressed. They are usually situated upon the face, particularly about the eyelids, cheeks, and chin. They increase slowly in size, eventually terminating in suppuration and disintegration. As a rule no scarring is left. The lesions are few, a half-dozen or more being the usual number present.

Etiology.—The disease occurs chiefly in the children of the poorer classes. It is probably contagious.

Pathology.—The disease consists of an enormous hyperplasia of the cells of the rete mucosum, the process in all *probability* beginning in the hair-follicles. The center of the *molluscum tumor* is made up of a number of lobules filled

with ovoidal or rounded, fatty-looking, degenerated epithelial cells, designated as "molluscum bodies."

Diagnosis.—The characteristic features of the disease are: the size of the lesions, their waxy appearance, the presence of

FIG. 56.—MOLLUSCUM EPITHELIALE.—(*After Allen.*)

a central orifice giving exit to a whitish secretion, and the history and course of the affection.

Prognosis.—The condition sometimes disappears spontaneously. It is readily amenable to treatment.

Treatment.—The tumors may be destroyed by incision, expression of their contents, and cauterization of the cavity with the stick of the nitrate of silver.

Again, they may be curetted away or snipped off with a pair of curved scissors. Pedunculated growths may be ligated. Where the lesions are small, the following ointment may be used:

℞. Hydrarg. ammoniat., ... ʒj
Ung. zinci oxidi, ... ℥j.

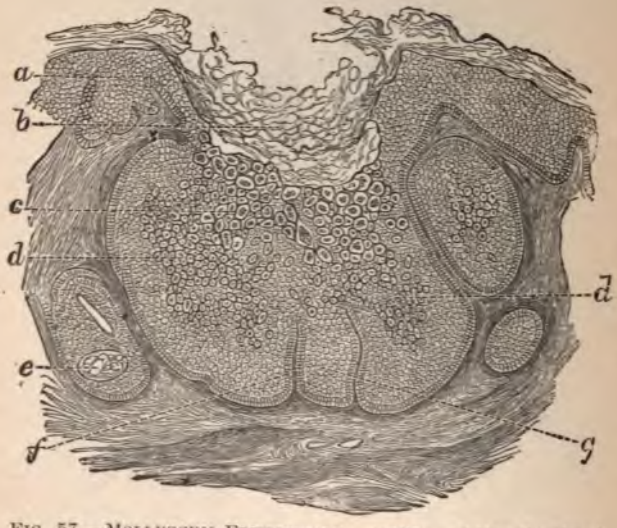

FIG. 57.—MOLLUSCUM EPITHELIALE. ×125.—(*After Crocker.*)

COMEDO.

Derivation.—*Comedo*, glutton; spendthrift.

Synonyms.—Blackheads; flesh-worms.

Definition.—Comedo is a condition characterized by black, pinhead-sized plugs of sebum lying in the mouths of the sebaceous ducts.

Symptoms.—Comedones appear as yellow, brown, blue or black points involving chiefly the nose, forehead, and cheeks. *They may*, however, occur upon other parts of the body.

When the comedo is squeezed out, one sees a yellowish-white, maggot-like body with a dark external point. The dark color is due partly to dust from without and partly to chemical changes in the secretion. Comedones are liable to undergo inflammation and give rise to acne papules or pustules.

Crocker mentions a variety of comedo (*grouped come-*

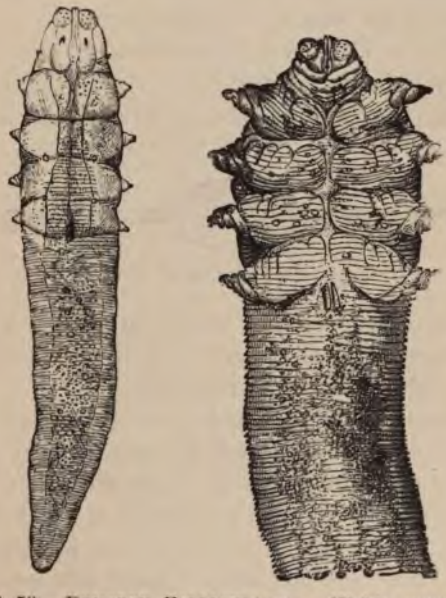

FIGS. 58 and 59.—DEMODEX FOLLICULORUM. Highly magnified.—(*After Nayler.*)

dones) characterized by closely aggregated, often symmetric lesions, occurring upon the temples and cheeks of children and not subject to inflammation.

Etiology.—Puberty, dyspepsia, anemia, constipation, and menstrual disturbance are frequent causes. They probably produce a lack of tonicity in the follicular walls.

Comedones are often produced artificially by deposition

from the atmosphere of various solid impurities. Thus, tar, brass, and iron workers are frequent sufferers from this affection.

Pathology.—Unna claims that there is a thickening of the corneous layer of the external surface and consequently a closure of the duct. The horny lining of the ducts undergoes similar change, and scales are thrown into the canal, which, combining with the sebum, form the comedo.

The *acarus,* or *Demodex folliculorum,* is sometimes accidentally present in comedones.

Prognosis.—Favorable. The condition is apt to recur.

FIG. 60.—CLOVER'S ACNE PRESSER.

Treatment.—The systemic treatment aims at a correction of the predisposing causes. Strychnia, iron, cod-liver oil, and the hypophosphites are often required.

Locally, applications designed to remove the plugs are indicated. The larger ones should be squeezed out either with the fingers or a comedo extractor. Soaps containing sand or chalk are sometimes used. The tincture of green soap (*tinctura saponis viridis*) is an excellent remedy in sluggish cases. Equal parts of alcohol and ether make a nice sebaceous solvent.

The appended formula is at times very efficacious:

℞.	Sulph. præcip., ...	ʒj
	Saponis mollis, ...	ʒj
	Pulv. cretæ, ...	ʒj-ij
	Ung. zinci oxidi, ...	℥j.

Or the following lotion may be used:

℞.	Acidi borici, ...	ʒj
	Spts. vini rect., ...	f℥iij.

MILIUM.

Derivation.—*Milium,* a millet-seed.

Synonyms.—Grutum; strophulus albidus.

Definition.—A condition characterized by the formation of small, round, yellow or pearly-white sebaceous bodies just beneath the epidermis.

Symptoms.—The lesions are most commonly found upon the forehead and cheeks. They vary in size from a millet-seed to a pinhead, are translucent, and project slightly above the level of the skin. They at times undergo calcareous change, producing the so-called *cutaneous calculi.*

Etiology.—They occur in infants and young adults. Causes obscure. Develop at times under scars and in the sites of former attacks of erysipelas and pemphigus.

Pathology.—Milia are believed to be due to the retention of sebaceous matter in superficially seated glands. Under the microscope they are found to consist of concentric layers of epithelial cells around a central core of fat and cells, and surrounded by a thin capsule.

Treatment.—In infants, soap and water are all that is necessary to remove the bodies. In adults the lesions should be incised and the contents expressed. If they recur the sac should be touched with the tincture of iodin. Hardaway recommends electrolysis.

CYSTIS SEBACEA.

Derivation.—Στέαρ, fat.

Synonyms.—Wen; sebaceous cyst or tumor; atheroma; steatoma.

Definition.—A wen is a cyst containing sebaceous matter.

Symptoms.—The cysts are pea- to egg-sized, rounded or oval tumors. The seats of predilection are the scalp, face, neck and back. They are painless unless inflamed, and the overlying skin is pale. They may remain stationary for years,

may grow slowly, or may undergo inflammation and suppuration.

Pathology.—They are due to accumulations of sebaceous matter in the glands; in other words, they are retention cysts.

Treatment.—The overlying skin should be incised and the tumor with its capsule carefully dissected out. If the capsule is allowed to remain, recurrence invariably follows.

KERATOSIS PILARIS.

Derivation.—*Κέρας*, a horn.

Synonyms.—Lichen pilaris; pityriasis pilaris.

Definition.—Keratosis pilaris is a hypertrophic affection characterized by pinhead-sized epidermal accumulations at the mouths of hair-follicles.

Symptoms.—The extensor surfaces of the arms and thighs are the usual seats of the eruption. The lesions consist of closely aggregated pinhead-sized, conical elevations corresponding to the orifices of the hair-follicles. A hair pierces each elevation or is buried within it. The lesions are grayish, whitish, or blackish in color, and are made up of epidermal cells and sebum. The skin is dry and rough, and feels to the hand passed over it not unlike a fine nutmeg-grater.

As a rule, itching is absent. The course of the disease is chronic.

Etiology.—Puberty and infrequent bathing seem to be causal factors. Hyde believes the affection to be more common in people of unusual physical vigor.

Pathology.—The condition consists of an accumulation of horny cells and sebaceous material at the orifices of the hair-follicles.

Diagnosis.—Keratosis pilaris is, as a rule, easy of diagnosis. It may be distinguished from "goose-flesh" (cutis anserina) by the permanence of the lesions as compared with their evanescence in the latter affection.

The lesions of the small papular syphiloderm are more generally distributed, tend to group, and are deeper seated and less scaly than those of keratosis pilaris.

Prognosis.—Favorable.

Treatment.—Simple or alkaline warm baths, with the use of ordinary soap or sapo mollis, will usually suffice. In some cases this may be followed by the inunction of one of the simple ointments.

Later, daily cold sponge baths and friction.

KERATOSIS FOLLICULARIS.

Synonyms.—Psorospermosis; Darier's disease (psorospermose folliculaire végétante).

Definition.—Keratosis follicularis is a hypertrophic affection characterized by pinhead- to pea-sized, dark-colored, acuminated or rounded papules, marking the sites of horny plugs imbedded in funnel-shaped dilatations of the pilo-sebaceous follicles.

Symptoms.—The disease is exceedingly rare. The favorite seats of the eruption are the scalp, face, chest, loins, and inguinal region. The dark-colored papules are surmounted here and there by horny, spinous projections, which, when removed, leave pit-like depressions. Papillomatous vegetations are prone to occur upon opposing skin surfaces, as in the inguinal region. These vegetations are bathed in a purulent secretion, which emits an extremely offensive odor. The disease runs a chronic and progressive course.

Etiology.—The disease is more common in males than in females, and occurs chiefly in childhood and adolescence. Heredity and contagion are possible causal factors.

Pathology.—The disease is primarily a hyperkeratosis of the hair and sebaceous follicles, with secondary hyperplasia of the interpapillary projections of the rete mucosum.

Prognosis.—No cures have been reported, but improvement may take place under treatment.

Treatment.—Frequent baths and inunctions with sapo mollis may be employed, followed by the use of a salicylated dusting powder.

FIG. 61.—RUSSIAN "DOG-FACED MAN," AN EXAMPLE OF EXCESSIVE HIRSUTIES.

HYPERTRICHOSIS.

Derivation.—Ὑπερ, in excess; θριξ, hair.

Synonyms.—Hirsuties; hairiness; hypertrophy of the hair; superfluous hair.

Definition.—Hypertrichosis is a condition characterized by excessive hair-growth either as regards number or size.

Symptoms.—Hair may grow to an unnatural degree upon parts normally the seat of hair, as the mustache, beard, eyebrows, etc., or there may be an abnormal growth upon non-hairy regions. In the latter case the lanugo hairs of the part are hypertrophied. This is the condition so frequently seen upon the upper lips and chins of women.

Excessive hair-growths occurring upon moles constitutes the so-called *nævus pilosus.*

Etiology.—The cause of hirsuties is obscure. Heredity is observed in the most extensive cases. The condition may be

FIG. 62.—NÆVUS PILOSUS ET LIPOMATODES.—(*After Hyde.*)

congenital or acquired; when acquired it is apt to develop after the menopause. Diseases of the uterus and appendages may be causative in some cases. Cutaneous irritation or stimulation may also give rise to this condition.

Treatment.—The cases in which treatment is usually demanded are women with superfluous facial hair-growth.

Superfluous hair may be temporarily removed by *shaving, extraction,* or the use of *depilatories.* The sulphid of barium depilatory, recommended by Duhring, is one of the best:

℞. Barii sulphid., ... ʒij
Pulv. zinci oxidi, ...
Pulv. amyli, ... āā ʒiij.

FIG. 63.—TWENTY-CELL GALVANIC CURRENT FOR ELECTROLYSIS.

This is made into a paste with a little water and spread on the hairy region for ten to fifteen minutes. As soon as burning is experienced it should be removed and followed by a bland ointment. Such applications must be repeated every few days, according to the needs of the case.

The only satisfactory treatment of hirsuties, however, is by means of *electrolysis.* This consists in the insertion of a fine needle into each hair follicle, and then turning on an electric current to destroy the hair papilla. The operation is somewhat painful, but ne[illegible] within the limit of *toleration.*

Stiff hairs alone are to be extirpated. The removal of downy or lanugo hairs is not to be attempted, as the result is likely to be unsatisfactory. The *operation* is performed in the following manner: A fine needle (irido-platinum needle or a fine jeweler's broach), held firmly in a specially devised holder, is attached to the *negative* pole of a *galvanic* battery. The needle is gently inserted into the hair-follicle down to the papilla. The patient holds a sponge electrode (positive pole), and makes the current by bringing it in contact with the palm of the other hand. In ten or twenty seconds a frothing occurs at the mouth of the follicle. The current is then broken by the release of the positive electrode, and the needle is withdrawn. If the papilla has been destroyed, the hair will come out upon the slightest traction with a forceps. If it remains firm, the operation must be repeated. A current of from one to two milliamperes is usually required.

FIG. 64.—ELECTROLYSIS NEEDLE-HOLDER.—(*Duhring.*)

A wheal-like elevation soon develops at the site of the operation, but disappears in the course of a few hours. Occasionally pustulation occurs.

To avoid *scarring*, attention should be paid to the following points:

(1) The use of a fine needle; (2) the avoidance of too prolonged a current; (3) the avoidance of too strong a current; (4) care not to operate at the same sitting upon hairs in too close proximity.

Hot *water, calamin* lotion, or a 1 : 1000 solution of corro-

sive sublimate, sopped on after the operation, lessens the inflammation and the tendency to suppuration and scarring.

ELEPHANTIASIS.

Derivation.—*Ἐλέφας*, an elephant.

Synonyms.—Elephantiasis arabum; pachydermia elephant leg; Barbadoes leg.

Definition.—Elephantiasis is a chronic hypertrophic disease of the skin and subcutaneous tissue due to obstruction of the lymphatic channels, resulting in enormous enlargement and thickening of the part, with papillary outgrowth.

Symptoms.—The most frequent seats of elephantiasis are the leg and foot, although the penis, scrotum, clitoris, and other parts are at times involved.

The affection usually begins as an erysipelatous inflammation, accompanied by fever, lymphangitis, pain, swelling, and heat, and followed by more or less permanent enlargement of the part. Such attacks recur at intervals of a few months, the affected area each time becoming larger. Finally a state of chronic hypertrophy is reached, the limb is greatly enlarged, the skin and subcutaneous tissue are enormously thickened, and the surface pigmented and covered with papillomatous growths and fissures. The maceration of the epidermis and the collection of decomposing sweat, sebum, and effete products give rise to an offensive odor.

There is, as a rule, no pain, although during the acute exacerbations it may be severe. The enormous weight of the hypertrophied part may make locomotion difficult or even impossible. The course of the affection is chronic.

Etiology.—The disease is most common in tropical countries, where it occurs chiefly in those subject to bad hygiene and poor food. It is due to inflammation and obstruction of the lymphatic vessels by the *filaria sanguinis hominis*. Sporadic cases may be due to obstruction of the lymphatics from

other causes, such as recurrent erysipelas, ulcers, cicatrices, tumors, etc.

Pathology.—There is a hyperplasia, participated in by the subcutaneous tissue and all of the layers of the skin. The chief change is in the subcutaneous tissue, which is enormously hypertrophied and traversed by irregular bundles of connective tissue. Where the surface of the skin is warty,

FIG. 65.—ELEPHANTIASIS.

the papillæ are greatly elongated. Both blood-vessels and lymphatics are enormously distended, the latter leading to dilated lymph-spaces. The neighboring lymphatic glands are enlarged. In advanced cases the muscles undergo fatty degeneration and the bones become enlarged.

Diagnosis.—The history of recurrent erysipelatous inflammation, with slowly progressing hypertrophy, is peculiar to elephantiasis. In advanced cases the appearances are unmistakable.

Prognosis.—In the beginning the process may at times be arrested. When the growth is far advanced, treatment accomplishes but little.

Treatment.—The erysipelatous attacks are to be treated by rest, hot or cold applications, and the internal administration of salines and quinin.

Good food and hygiene, tonics, and change of climate are important matters in endemic cases. Elastic compression by means of a well-applied rubber bandage is the most efficient therapeutic measure. Green soap and the mercurial ointments may be rubbed into the skin.

In advanced elephantiasis of the leg one may resort to stretching or partial exsection of the sciatic nerve, or digital or instrumental compression or even ligation of the femoral artery.

Elephantiasis of the scrotum is best treated by amputation.

DERMATOLYSIS.

Synonyms.—Cutis pendula; fibroma pendulum; lax skin; "elastic skin."

Definition.—Dermatolysis is a rare disease, characterized by hypertrophy and laxity of the skin and subcutaneous tissues, with a tendency to hang in folds.

Some writers apply the name dermatolysis to an abnormal laxity and elasticity of the skin with hypertrophy, as seen in the so-called "elastic-skin men."

Symptoms.—The condition may be congenital or acquired, and may be slight in extent or involve large areas. The subcutaneous tissue and the skin, with its component structures, hair, glands, etc., are all hypertrophied. In marked cases the skin, which is often rugose and pigmented, hangs in huge folds like a garment.

There are no subjective symptoms except the inconvenience occasioned by the size and weight of the growth.

Etiology.—Obscure. The condition is allied to fibroma molluscum.

Pathology.—There is hypertrophy of all the structures of the skin and subcutaneous tissue

In the so-called "elastic skin," the elastic tissue is normal, but the connective-tissue fibers are converted into a myxomatous-looking tissue.

Treatment.—The mass is to be excised when its location and extent permit. There is no tendency to recurrence.

ONYCHAUXIS.

Derivation.—Ὄνυξ, a nail; αὐξέειν, to grow.

Synonym.—Hypertrophy of the nail.

FIG. 66.—HYPERTROPHY OF NAIL.—(*After Van Harlingen.*)

Definition.—Onychauxis is an increase in the size of the nail, either in length, breadth, or thickness.

Symptoms.—Hypertrophy of the nail may be congenital or acquired, idiopathic or symptomatic, as in ichthyosis or *syphilis. The nail* may be merely enlarged or there may be

coincident structural changes. Thus, the nail may become roughened, furrowed, and opaque, and have a yellowish, brownish, or blackish hue.

Lateral growth may result in inflammation of the surrounding tissues (*paronychia*), or the matrix itself may undergo inflammation (*onychia*).

Onychogryphosis is a term used to denote nails which have become curved and claw-like.

Etiology.—In acquired cases the condition is usually a manifestation of psoriasis, ichthyosis, leprosy, syphilis, etc.

Treatment.—The excessive nail tissue should be removed with a knife or scissors. Symptomatic cases should be treated in connection with the associated disease.

In paronychia the imbedded nail edge should be trimmed off and cotton packed in between the nail and the soft parts.

CLASS VI.—ATROPHIAE—ATROPHIES.

ALBINISMUS.

Derivation.—Albus, white.

Synonym.—Albinism.

Definition.—Albinism is a congenital affection characterized by partial or complete absence of pigment in the skin, hair and eyes.

Symptoms.—In complete albinism the skin is preternaturally white, and the entire hair of the body is fine, silky, and of a whitish or yellowish-white color. The irides have a pinkish or pale bluish hue, and the pupils, owing to the lack of pigment in the choroid, show the orange-red color of the fundus. Photophobia, nystagmus, and nictitation occur as a result of absence of the protective pigment, and are of considerable annoyance to the patient.

Partial albinism occurs chiefly in negroes, where it mani-

fests itself as variously sized and shaped depigmented, milky-white patches. The hairs upon such patches are also white. The term "piebald" is commonly applied to such individuals. "Albinoes" not infrequently exhibit physical and mental inferiority.

Etiology.—Unknown. Heredity seems to be a factor, inasmuch as several children in the same family are usually affected.

Pathology.—The skin is normal, with the exception that there is absence of pigment in the rete mucosum.

Treatment.—Treatment is entirely without avail.

VITILIGO.

Derivation.—*Vitium,* a blemish.

Synonyms.—Leukoderma; acquired piebald skin.

Definition.—Vitiligo is an acquired pigmentary affection characterized by variously sized and shaped whitish patches with hyperpigmented borders.

Symptoms.—The condition manifests itself as rounded, oval or irregular milk-white or pinkish-white spots, which tend slowly or rapidly to spread, at times coalescing and producing large patches. These are smooth, soft, sharply defined, and neither elevated nor depressed. The surrounding skin shows increased pigmentation, being usually brownish-yellow in color. The hairs upon the affected areas may or may not turn white.

The disease progresses slowly, becoming conspicuous only after a duration of years. In rare cases the affection may involve the greater part, or indeed the whole of the body. Vitiligo lasts throughout life.

The eruption may occur upon any portion of the cutaneous surface, although it is prone to elect the backs of the hands, neck, and the trunk.

There are no subjective symptoms. Disfigurement is the

sible inconvenience. The affection is frequent in negroes, in whom it produces a most striking appearance.

Etiology.—Vitiligo occurs in adult life. In many cases

FIG. 67.—VITILIGO IN A COLORED WOMAN.

there is no ascertainable cause. It is due, in all probability, to a disturbance of innervation. It is occasionally associated with morphea, alopecia areata, and exophthalmic goiter.

Pathology.—The skin is normal, with the exception of an

unequal distribution of coloring-matter. In the white spots there is total absence of pigment, whereas in the darkened borders the pigment is abnormally increased.

Diagnosis.—Vitiligo is to be distinguished from chloasma, tinea versicolor, morphea, and leprosy:

VITILIGO.	CHLOASMA.	TINEA VERSICOLOR.	MORPHEA.	LEPROSY.
Patches are smooth and white with hyperpigmented borders.	Patches are brownish-yellow; no white spots.	Patches are brownish-yellow; furfuraceous scaling; fungus.	Structural changes in the corium.	May be whitish or yellowish, but are anesthetic.

Prognosis.—In rare cases spontaneous recovery has been observed, but the affection may be said to be practically incurable.

Treatment.—From what has been said, it is evident that the treatment is highly unsatisfactory. Duhring advises the long-continued administration of small doses of arsenic. Locally, lotions of corrosive sublimate or acetic acid, as recommended for chloasma, may be applied to the pigmented borders with a view of dissipating the color and lessening the contrast.

ATROPHIA CUTIS.

Derivation.—Ἀ, privitive, τροφή, nutrition.

Synonyms.—Atrophy of the skin; atrophoderma.

Definition.—Atrophy of the skin is a condition characterized either by diminution in the bulk of the skin or degeneration of its component structures.

Symptoms.—Under the general heading of cutaneous atrophy several varieties are to be considered.

ATROPHIA SENILIS (*Senile Atrophy*).

This term is applied to the degenerative cutaneous changes that occur in old age. The skin is thin, dry, shriveled, pig-

mented in spots, and covered with branny scales. The hair, and the sweat and sebaceous glands may disappear or the last named may undergo degeneration.

Atrophoderma Neuriticum (*Glossy Skin*).

Glossy skin is a rare atrophic affection, occurring usually upon the fingers, and characterized by a smooth, tense, pinkish, shining appearance, with loss of hair and incurvation of

Fig. 68.—Atrophy of Skin.—(*After Van Harlingen.*)

the nails. It is accompanied and preceded by considerable burning pain, and is due to injury or disease of a nerve. The treatment consists of protection from cold and traumatism, the condition tending itself to spontaneous recovery.

General Idiopathic Atrophy.

This is an extremely rare affection involving large areas of skin, such as an entire limb. The skin is thinned, dry, and scaly, and exhibits a marbling of purplish or reddish-brown spots or streaks, often ending in pigmentation. The disease is slowly progressive.

STRIÆ ET MACULÆ ATROPHICÆ (*Atrophic Lines and Spots*).

This form of atrophy may be idiopathic or symptomatic.

In the idopathic variety there develop without known cause erythematous spots and lines, which, after a variable duration, terminate in atrophy. When fully developed, the atrophic areas are from one to two inches in length, and are white, glistening, depressed, perceptibly thinned and of a whitish or bluish-gray color. They are usually seen about the buttocks, trochanters, pelvis, and thighs. The symptomatic variety is exemplified in the so-called *lineæ albicantes* of pregnancy. The fibers of connective tissue are separated and the papillæ effaced.

XERODERMA PIGMENTOSUM.

Derivation.—*Ξηρὸς*, dry; *δέρμα*, skin.

Synonyms.—Atrophoderma pigmentosum; angioma pigmentosum et atrophicum; Kaposi's disease.

Definition.—Xeroderma pigmentosum is a rare congenital disease characterized successively by pigmentation, telangiectasis, cutaneous atrophy, and malignant papillary tumors, ending fatally.

Symptoms.—The disease usually begins in the first or second year of life and is slowly progressive. In the beginning, freckle-like pigmentations appear upon the face, neck, and backs of hands. Later, atrophic depressions, telangiectases, and diffuse atrophy make their appearance. In the course of a few years warty growths occur upon the pigmented spots and develop into epitheliomatous, sarcomatous, or angiomatous tumors. The disease terminates fatally after a lapse of some years.

Etiology.—Congenital predisposition is the only known cause. Several children in the same family are usually affected.

Pathology.—Crocker believes the disease to be "an atro-

phic degeneration of the skin, dependent upon a primary neurosis to which there is a congenital predisposition."

Prognosis.—Nearly all cases terminate fatally.

Treatment.—Local application may be employed to ameliorate the condition of the skin, and when advisable the growths may be removed surgically.

SCLEREMA NEONATORUM.

Derivation.—Σκληρὸς, hard; νέων, lately.

Synonyms.—Scleroderma neonatorum; sclerema of the new-born.

Definition.—Sclerema neonatorum is a disease occurring at or shortly after birth, characterized by induration of the skin and subcutaneous tissue, and local and general circulatory disturbance.

Symptoms.—The disease begins usually in the lower extremities and spreads upward, involving the trunk, arms, and face. The skin is reddish, purplish or mottled, edematous, hard, rigid, and cold. The rigidity, which resembles "rigor mortis," renders motion of the joints almost impossible. Respiration is feeble, the pulse weak, and the temperature subnormal. The infant is unable to take nourishment, and death results in a few days or weeks. In very rare instances recovery may spontaneously take place.

Etiology.—Obscure. Occurs most frequently in premature children. The immediate cause is a faulty capillary circulation due to pneumonia, feeble vitality, etc.

Treatment.—The treatment consists of: (1) Keeping up the body temperature (by means of an incubator, wrapping in wool, or hot baths); (2) maintaining nutrition (by feeding through a tube, etc.); (3) centripetal friction with warm oils.

SCLERODERMA.

Derivation.—Σκληρὸς, hard; δέρμα, the skin.

Synonyms.—Hidebound disease; sclerema adultorum; scleriasis; dermatosclerosis.

Definition.—Scleroderma is a disease characterized by circumscribed or diffuse induration, rigidity and stiffening of the integument, terminating in atrophy.



FIG. 69.—SCLERODERMA.
a. Epidermis. *b*. Rete Malpighii, greatly pigmented. *c*. Cutis, very vascular. *d*. Pigment stripe from an obliterated vessel. *e*. Masses of pigment. *f*, *f*. Sections of muscular fibers. *g*. Longitudinal bands of the same.

Symptoms.—The disease is exceedingly rare. The skin manifestations may be preceded or accompanied by disturbance of cutaneous sensibility, such as pain, prickling, tingling, formication, etc., and by muscular cramps. The disease begins as a pronounced stiffening or hardening of the skin, which progresses gradually, or more rarely rapidly, until marked induration results. In some cases an edema-

tous stage may precede the induration. When the disease is typically developed, the skin is thickened, tense, hard, and immovable, acquiring in an advanced stage the feel of frozen skin, leather, or even wood. It is bound down to the structures beneath, and is incapable of being pinched up. There is usually pigmentation of a yellowish or brownish hue.

After a variable duration the stage of induration passes on to the stage of atrophy. The skin then becomes thinned, shiny, and tensely stretched over the bony prominences. The phalangeal joints are apt to become ankylosed in a semi-flexed position (sclerodactylia).

The course of the disease is chronic, although in rare cases it may be acute. The general health is, as a rule, not compromised. The parts most affected are the neck, face, forearms, chest, and lower extremities.

Etiology.—Scleroderma occurs chiefly in early adult and middle age, and is far more common in women than in men. Exposure to cold and wet, rheumatism, and nerve shocks have been causal in many cases. The disease is brought about through the implication of the nervous system.

Pathology.—The chief changes noted in scleroderma are: an increase and condensation of the connective tissue in the corium and subcutaneous tissue, an increase in the elastic tissue, and a diminution in the caliber of the blood-vessels. Later there is atrophy of the subcutaneous tissues.

Diagnosis.—The peculiar immobile, indurated, tightly adherent condition of the skin is highly characteristic of the disease. Morphea is looked upon by most writers as a circumscribed form of scleroderma.

Prognosis.—Unfavorable; a few cases undergo spontaneous involution, but the majority persists throughout life.

Treatment.—Internal treatment is to be based upon general principles, arsenic, quinin, and cod-liver oil being frequently of value. Locally, baths, massage with oily substances, and electricity may be employed with benefit.

MORPHEA.

Derivation.—*Μορφή*, a blotch.

Synonyms.—Circumscribed scleroderma; keloid of Addison.

Definition.—Morphea is a disease characterized by rounded or oval, well-defined, firm, coin-sized or larger patches of a whitish-yellow or pinkish color surrounded by a violaceous zone.

Symptoms.—Discrete, rounded, oval or elongated patches varying in size from a pea to the palm of the hand, develop slowly upon the face, neck, chest, abdomen, or extremities. When fully formed they are, as a rule, firm to the touch, but not hard. The color is pale pinkish, yellowish, violaceous, or whitish. The surface is often shiny with a polished ivory appearance. Around the patches is a zone of a lilac or violaceous hue, due to dilated blood-vessels, or there may be yellowish or brownish pigmentation.

The course is variable, but as a rule chronic. The patches may undergo involution, or may terminate in atrophy, leaving the integument whitish, thinned, shriveled, and bound to the tissues beneath.

Etiology.—As in scleroderma, the nervous system is probably the seat of the disorder.

The disease occurs more frequently in women than in men. Many writers look upon morphea as a circumscribed scleroderma.

Pathology.—Microscopically, there is seen an exudation around the sweat and sebaceous glands and blood-vessels, lessening the caliber of the latter. An atrophy or flattening of the papilla with an increase and condensation of the connective tissue take place, later resulting in atrophy.

Diagnosis.—There should not be much difficulty in distinguishing the patches of morphea from those of vitiligo *and nerve-leprosy*. The patches of vitiligo show no struc-

tural changes; neither do those of nerve-leprosy, which are, in addition, anesthetic.

Prognosis.—Guarded. Patches may disappear spontaneously, but are more likely to persist indefinitely.

Treatment.—The treatment is practically that of scleroderma—namely, tonics, massage, and electricity.

CANITIES.

Derivation.—*Canus,* white.

Synonyms.—Grayness of the hair; whitening of the hair.

Definition.—Canities is an atrophic pigmentary affection of the hair characterized by circumscribed or general graying or whitening.

Symptoms.—When occurring in advanced years the condition is to be looked upon as physiologic (*canities senilis*). Not infrequently it occurs in early adult life (*canities prematura*). It may involve the entire hair of the head or only small patches, forming tufts of gray or white hair. The loss of pigment, as a rule, takes place slowly; it must be admitted, however, that in rare cases it is possible for hair to "turn white in a single night." The condition persists throughout life.

Etiology.—Physiologic whitening of the hair is due to senility. The premature forms may be due to heredity, psychic shocks (fright, fear, etc.), and functional and organic nervous diseases.

Pathology.—The microscope shows partial or complete loss of pigment in the hair substance. Sudden graying is supposed to be due to the sudden appearance of air-bubbles in the shafts of the hair.

Treatment.—Internal remedies are of little or no value. The whitened hair may be dyed with:

℞.	Argent. nitrat., ...	gr. xv
	Ammon. carb., ...	gr. xxij
	Ung. adipis, ...	℥j.

For black shade [illegible]

℞. Acidi pyrogall., ... gr. xv
Aq. cologn., ... ʒss
Aq. rosæ, ... f℥iss.
For brown shade (Kaposi).

ALOPECIA.

Derivation.—Ἀλώπηξ, a fox.

Synonyms.—Baldness; calvities.

Definition.—Alopecia is a physiologic or pathologic deficiency or loss of hair, either partial or complete. The forms of alopecia may be classified as follows:

- I. Congenital alopecia.
- II. Senile alopecia.
- III. Premature alopecia.
  - (*a*) Idiopathic.
    - Hereditary predisposition.
  - (*b*) Symptomatic.
    - (1) Local diseases.
      - Seborrhea.
      - Eczema seborrhœicum.
      - Psoriasis.
      - Erysipelas.
      - Lupus erythematosus.
      - Syphilodermata.
      - Folliculitis.
      - Tinea tonsurans.
      - Tinea favosa, etc.
    - (2) General diseases.
      - Acute.
        - Typhoid fever.
        - Variola.
        - Scarlatina.
        - Pregnancy, etc.
      - Chronic.
        - Syphilis.
        - Leprosy.
        - Myxedema.
        - Neurasthenia.
        - Chronic intoxications.
        - Anemia.
        - Diabetes.
        - Cancer.
        - Uric acid diathesis.
        - Phthisis, etc.

Congenital Alopecia.—This commonly manifests itself either as a scanty growth, a development only in certain localities, or as a retarded appearance of the hair. In rare cases there may be complete absence of the hair, due to arrested development of the follicles. In such cases hereditary predisposition is usually present, and there is apt to be, in addition, delayed or defective dentition.

Senile Alopecia.—As the name indicates, this form of baldness is observed in the aged. With the atrophic skin

changes that accompany senility there takes place a gradual thinning of the hair, beginning upon the vertex of the scalp, the frontal and the temporal regions, and slowly leading to a more or less complete baldness of the calvarium.

PREMATURE ALOPECIA.—This form of alopecia occurs in individuals chiefly between the ages of twenty and thirty-five. It may be either idiopathic or symptomatic.

In the *idiopathic* variety the scalp presents no abnormal condition. At first only a few hairs fall from time to time, being replaced by a shorter and finer growth. Later these fall and are followed by still finer hairs. In this manner the entire hair of the scalp may be lost. The affection occurs in both sexes, although much less frequently in women than in men. Heredity appears to be a strong predisposing factor.

The *symptomatic* form results from various local and general diseases. Rapid falling of the hair (*defluvium capillorum*) follows acute diseases, such as typhoid fever, smallpox, etc. Full regeneration of the hair follows the restoration to health.

Rapid and extensive loss of hair occurs with frequency in the early stages of syphilis. The most prolific cause of premature alopecia is chronic dry seborrhea (*dandruff*) of the scalp. This affection, after a long duration, leads to atrophy of the hair-follicles.

Other local diseases, such as lupus erythematous, erysipelas, psoriasis, eczema, tinea tonsurans, tinea favosa, etc., may all produce more or less marked alopecia.

Prognosis.—In congenital and senile alopecia treatment is of little or no avail. In idiopathic premature alopecia the prognosis should be extremely guarded. In symptomatic alopecia, particularly when there is a removable cause and no hereditary predisposition, the prognosis may be considered more favorable.

Treatment.—Internal treatment is to be employed when-

ever the condition depends upon a systemic cause. Such tonics as iron, strychnin, phosphorus, arsenic, and cod-liver oil may often be prescribed with advantage.

Local treatment is of great importance, particularly when dandruff is present. It consists of the proper cleansing of the scalp and the stimulation of the sebaceous glands to healthy action.

The tincture of green soap makes an admirable shampoo for the removal of epithelial and sebaceous debris. This may be advantageously followed by such a hair wash as:

℞.	Resorcini, ...	ʒij	
	Acidi salicylici, ...	gr. xxx-ʒj	
	Ol. ricini, ...	f℥ss-f℥iss	
	Spts. vini rect., . . . q. s. ad	f℥vj	
	Ol. bergamott., ...	f℥j.	M.

When greater stimulation is desired, the following should be used:

℞.	Hydrarg. bichlorid., ...	gr. xij	
	Betanaphtol, ...	gr. xxx	
	Ol. ricini, ...	f℥j	
	Spts. vini rect., . . . q. s. ad	f℥vj	
	Ol. bergamott., ...	♏xxx.	M.

Sig.—Hair wash.

When the scalp is accessible, ointments may be used.

℞.	Sulph. præcip., ...	gr. xxx-ʒj
	Petrolat., ...	℥ss
	Ol. bergamott., ...	♏xxx.

ALOPECIA AREATA.

Derivation.—Ἀλώπηξ, a fox.

Synonyms.—Alopecia circumscripta; area Celsi.

Definition.—Alopecia areata is a disease of the hairy system characterized by the more or less sudden occurrence of round or oval, circumscribed, bald patches, in rare cases coalescing and producing total baldness.

Fig. 70.—Alopecia Areata in Mother and Child.

Symptoms.—The disease is usually limited to the scalp, but may affect the beard, eyebrows, eyelashes, and, in rare instances, the entire cutaneous surface.

As a rule, one, two or more patches are present upon the scalp. They are circumscribed and rounded, and vary in size from a coin to the palm of the hand. The skin is smooth, soft, of a dead-white color, and totally devoid of hair. Occasionally the patches are pinkish as a result of slight hy-

FIG. 71.—SAME CHILD, FOUR MONTHS AFTER INSTITUTION OF TREATMENT.

peremia. The follicular openings are contracted and less prominent than in the healthy scalp. To the feel the skin is thin, soft, and pliable. In the beginning the patches are level or slightly elevated, whilst later they are sometimes slightly depressed.

The course of the disease is extremely variable. In some cases the bald patches develop suddenly in the course of a few hours. In other cases the hair loss is gradual, extending over a period of a few days or weeks. The areas then

Fig. 72.—Same Child, Ten Months after Institution of Treatment.

spread by peripheral extension until they reach a certain size, when they remain stationary.

The duration of the disease varies greatly. Recovery seldom occurs in less than a few months, while many cases last several years. In young individuals the hair usually returns sooner or later. In adults the baldness may persist and prove refractory to all treatment.

When regrowth occurs, the patch is first covered by fine, downy, whitish hairs, which are either shed or later converted into coarse and pigmented hairs.

As a rule, there are no subjective symptoms.

Etiology.—The disease is said to have its origin in a functional nerve disturbance, interfering with the innervation of the hair-follicles. It has been noted to follow psychic shocks (fright, etc.), injuries to the scalp, and section of nerves.

French writers insist upon the parasitic nature of alopecia areata, and cite epidemics of this disease in support of its contagious character.

It is probable that there are two varieties, the one trophoneurotic and the other parasitic.

Pathology.—The affected hairs show an atrophy of the shaft and the bulb. The skin changes are at first mildly inflammatory, later atrophic.

Diagnosis.—Alopecia areata is chiefly apt to be confounded with tinea tonsurans.

ALOPECIA AREATA.	RINGWORM.
1. Rapid onset.	1. Slow, insidious onset.
2. Patches are:	2. Patches are:
(*a*) Totally devoid of hair.	(*a*) Covered with broken-off stumps.
(*b*) Pale or whitish in color.	(*b*) More or less reddened.
(*c*) Smooth or soft.	(*c*) Rough and scaly.
(*d*) Follicles contracted.	(*d*) Follicles prominent; "goose-flesh" appearance.
3. Absence of fungus.	3. Trichophyton fungus present.
4. Common in *adolescence* and *adult life.*	4. Occurs almost exclusively in childhood.

Prognosis.—In children recovery usually takes place. In young adults the prognosis is guardedly favorable, while in advanced adults it is unfavorable. The duration of the disease is uncertain and relapses are not uncommon.

Treatment.—The internal treatment consists of the use of such tonics as iron, quinin, strychnin, cod-liver oil, phosphorus, and arsenic. Duhring considers arsenic to be "especially serviceable."

The local treatment has for its object the stimulation of the scalp and the consequent increased blood-supply to the follicles. Among the many medicaments which have been advised are alcohol, cantharides, capsicum, the essential oils, turpentine, carbolic acid, ammonia, sulphur, iodin, mercury, betanaphtol, etc.

The following lotion will be found of value:

℞. Tinct. cantharidis,
Tinct. capsici, ... āā f℥iss
Ol. ricini, ... f℥ij
Aq. cologn., ... f℥j. M.
Sig. Brush in vigorously once or twice a day.

Instead of lotions, ointments such as the following may be employed:

℞ Betanaphtol, ... gr. xxx
Petrolat., ... ℥ss
Ol. bergamott., ... ♏xxx. M.
Sig. Rub in thoroughly twice a day.

An efficient treatment consists in the swabbing of the bald areas once or twice a week with

℞ Acidi carbolici,
Spts. vini recti, ... āā ℥ss.

The faradic current applied with a wire-brush electrode is often useful. In obstinate cases blistering of the affected areas may be resorted to.

ATROPHIA PILORUM PROPRIA.

Synonym.—Atrophy of the hair.

Definition.—An idiopathic or symptomatic atrophy of the hair, characterized by diminution of size, dryness, brittleness, and tendency to splitting.

Symptoms.—Symptomatic atrophy of the hair occurs in seborrhea, ringworm, phthisis, syphilis, the various fevers, etc.

The idiopathic form is exemplified in the following affections:

Fragilitas Crinium.

This condition is marked by a brittle condition of the hair shaft. Commonly the caliber of the hair varies at different

Fig. 73.—Trichorrhexis Nodosa.—(*After Crocker.*)

points, due to the presence of uneven and irregular formations. There is, in addition, tendency to splitting of the hair into two or more filaments.

Trichorrhexis Nodosa.

This condition is most frequently observed in the beard and mustache. It is characterized by spindle-shaped, bulbous, translucent swellings along the hair shaft. Rupture takes place at the points of distention, the hairs frequently breaking off and leaving brush-like stumps.

Treatment.—The treatment is not very satisfactory. Repeated cutting or shaving of the hair is sometimes followed by improvement.

ATROPHIA UNGUIS.

Synonyms.—Onychatrophia; atrophy of the nail.

Definition.—A congenital or acquired condition, characterized by decreased size or thickness of the nail, softening, splitting, crumbling, and discoloration.

Symptoms.—In congenital atrophy the nails may be absent, defective, or distorted. In acquired atrophy, which is more common, the nail may be thin, opaque, narrow, friable, furrowed, laminated, and otherwise distorted. Acquired atrophy results from wasting general diseases, syphilis, and nerve injuries, and from such local disorders as psoriasis and eczema. When the nail is invaded by the fungus of ringworm or favus it is termed *onychomycosis.*

Treatment.—The treatment varies according to the cause. Syphilis and other constitutional diseases must receive their appropriate treatment. In other cases trimming and scraping of the nails and friction with green soap are often of value. In onychomycosis mercurial preparations are of particular efficiency.

CLASS VII.—NEOPLASMATA—NEW GROWTHS.

KELOID.

Derivation. Νηλίς, a claw.

Synonyms. Cheloid; keloid of Alibert.

Definition. Keloid is a connective-tissue new growth appearing as variously sized and shaped, smooth, firm, reddish, cicatriform elevations.

Symptoms. The disease usually begins as a small pea-sized nodule, which, during the course of years, slowly in-

creases in size. The shape is variable, being at times ovalish, cylindrical, crab-shaped, or streaked. The growth is well defined, firmly implanted in the skin, smooth, firm, and dense, with a shining pinkish or reddish color. Pain and tenderness are occasionally experienced.

FIG. 74.—SECTION OF A KELOID FROM THE FOREHEAD.
a. Epidermis. *b*. Rete Malpighii. *c*. Tissue of the cutis. *d*. Remnant of the cutis. *e*. Tense fibrous keloid tissue. *f*. Cell infiltration around the vessels.

The favorite situation is upon the trunk, particularly over the sternum.

Etiology.—*Spontaneous keloid,* or that form developing upon normal skin, is obscure as to origin. *Cicatricial* or *false keloid* springs up at the site of wounds, such as burns, cuts, leech bites, acne, and variola lesions, etc.

Keloid is much more frequent in the colored than in the white race.

o

Pathology.—Keloid is made up of dense bundles of white fibrous tissue, running parallel with the axis of the tumor. The growth has its seat in the corium.

Prognosis.—Spontaneous involution occurs occasionally, although the growth is apt to persist throughout life.

Treatment.—Usually unsatisfactory. Excision is nearly always followed by recurrence. Multiple scarifications and electrolysis have been advised.

Benefit sometimes follows the long-continued application of lead or mercurial plaster.

FIG. 75.—FIBROMA.

FIBROMA.

Derivation.—*Fibra,* a fiber.

Synonyms.—Molluscum fibrosum; fibroma molluscum; molluscum pendulum.

Definition.—Fibroma is a connective-tissue growth situated in the corium and subcutaneous tissue, characterized by sessile or pedunculated, soft or firm, rounded, painless tumors, varying in size from a split pea to an egg, or larger.

Symptoms.—Fibromata occur either singly or, more commonly, in numbers, when they are distributed over the greater part of the body. They vary in size from a pea to a cherry or even a pear. They have a uniformly soft consistence and are frequently pedunculated. The overlying skin may be

normal, pinkish or reddish, stretched, hypertrophied, or atrophied. The tumors are painless. Pendulous growths of great size occasionally ulcerate.

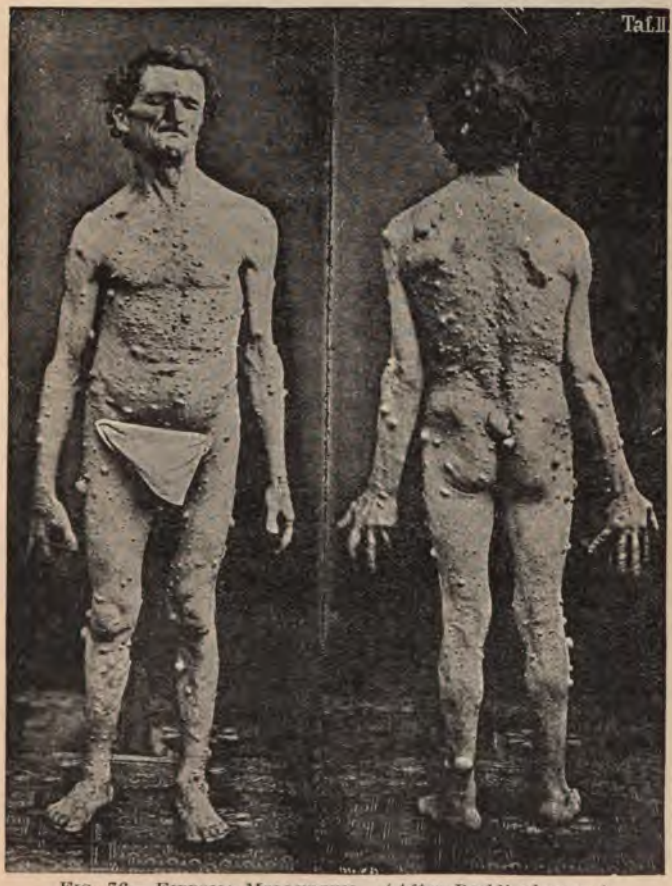

FIG. 76.—FIBROMA MOLLUSCUM.—(*After Recklinghausen.*)

Etiology.—Obscure. Hereditary predisposition is the only known cause.

Pathology.—Recent tumors are made up of gelatinous young connective tissue; old tumors of dense, closely packed, fibrous tissue. The growths are situated in the corium and subcutaneous tissue.

Diagnosis.—Molluscum fibrosum is to be distinguished from lipoma and neuroma. Lipomata are lobulated and softer, and neuromata are accompanied by pain.

Prognosis.—The tumors tend to increase in size and number, and persist throughout life.

Treatment.—Pedunculated tumors may be removed by means of a ligature or galvano-cautery. Others, if not too numerous, may be excised with the knife.

NEUROMA.

Derivation.—*Νεῦρον*, a nerve.

Synonym.—Nerve tumor.

Definition.—Neuroma of the skin is an affection characterized by one or more pinhead- to hazel-nut-sized tubercles, made up of connective tissue and nerve-fibers, and accompanied by severe paroxysmal pain.

Symptoms.—The condition is exceedingly rare. The nodules are purplish or pinkish, elastic and immovable, both painful and tender on pressure. The accompanying paroxysmal pain is often excruciating.

Pathology.—The growths are really neuro-fibromata, consisting of a mixture of connective tissue and medullated and non-medullated nerve-fibers. The tumors are seated in the corium.

Treatment.—Excision of the nerve-trunk leading to the growths has been twice tried, resulting in one case in temporary and in the other case in permanent amelioration.

XANTHOMA.

Derivation.—*Ξανθός*, yellow.

Synonyms.—Xanthelasma; vitiligoidea.

Definition.—Xanthoma is a connective-tissue new growth,

characterized by circumscribed flat or slightly raised yellowish patches or tubercles, commonly situated on the eyelids.

Symptoms.—There are two varieties—the macular (*xanthoma planum*) and the tubercular (*xanthoma tuberosum*).

FIG. 77.—LARGE XANTHOMA PLAQUE FROM EYELID.—(*After Crocker.*)
a. Rete Malpighii, many of the cells of which are undergoing vacuolation as at *e.* *b, b.* Cylindrical masses of xanthoma cells formed around a vessel. *c.* Hair-follicle. *d.* Multi-nucleated granular xanthoma giant cell.

XANTHOMA PLANUM

Occurs usually upon the upper eyelids as pea-sized or larger, soft, smooth, flat or slightly elevated, circumscribed patches of a "chamois leather" color.

XANTHOMA TUBEROSUM

Occurs upon the neck, body, or extremities as pinhead- to pea-sized or larger, rounded, raised, yellowish patches or tubercles.

The two forms occasionally coexist. When the lesions are numerous and wide-spread the designation *xanthoma multiplex* is employed.

A form of xanthoma known as *xanthoma diabeticorum* occurs in individuals suffering from glycosuria. The eruption usually disappears as the underlying condition improves.

Etiology.—Xanthoma occurs usually in middle life, and is more common in women than in men. There is often an antecedent history of jaundice, particularly in the tuberous variety.

Pathology.—Pollitzer's investigations would seem to prove that the chief pathologic process in xanthoma planum is a fatty degeneration of embryonically misplaced muscle fibers in the skin.

Microscopic sections show a connective-tissue new growth, in the interstices of which are nests of large epithelioid, fatty degenerated and infiltrated cells.

Prognosis.—After progressing to a certain size the lesions remain stationary for an indefinite period.

Treatment.—Whenever desired the growths may be removed by means of the knife, galvano-cautery, or electrolysis.

MYOMA.

Derivation.—Μῦς, muscle.

Synonyms.—Myoma cutis; dermatomyoma; liomyoma cutis.

Definition.—Myoma cutis is a rare affection, characterized by single, or more rarely multiple, smooth, pale red, pea- to bean-sized tumors, made up of smooth muscle fibers.

Symptoms.—Simple myoma (liomyoma) is rare and appears as small, pea-sized, pale red elastic growths, occurring most frequently upon the upper extremities.

Dartoic myoma (more common) appears usually as a solitary hazel-nut- to orange-sized, sessile or pedunculated tumor, occurring upon the breasts, scrotum, or labia majora.

Pathology.—The tumors consist chiefly of unstriped muscular fibers, but may contain fibrous connective tissue (*fibromyoma*), vascular tissue (*angiomyoma, myoma telangiectodes*), or lymphatic tissue (*lymphangiomyoma*).

FIG. 78.—MYOMA.

Treatment.—When practicable, excision may be advised.

NÆVUS VASCULOSUS.

Synonyms.—Nævus sanguineus; angioma.

Definition.—Vascular nevi are congenital formations composed chiefly of blood-vessels, having their seats in the skin and subcutaneous tissue.

Symptoms.—There are two varieties:

1. *Port-wine Mark, Nævus Flammeus, Angioma Simplex.*—Flat, non-elevated, smooth patches of a reddish or purplish color.

2. *Angioma Cavernosum, Nævus Tuberosus.*—Circumscribed, elevated, erectile, pulsating, purplish tumors, with a rugose or smooth surface.

Both varieties are seen most frequently upon the head and face.

Pathology.—In the flat or simple angioma there is a new growth, involving chiefly the capillaries of the corium. In angioma cavernosum there is a hypertrophy of the blood-vessels (both arteries and veins), of the corium, and of the subcutaneous tissue, with a variable amount of connective-tissue overgrowth.

Treatment.—Pinhead-sized nevi are best treated by electrolysis, the thermo-cautery, or nitric acid applied upon a pointed stick. For the "port-wine mark" electrolysis is the most valuable procedure.

Cavernous angioma may be treated by vaccination, ligation, galvano-cautery, electrolysis, or excision.

TELANGIECTASIS.

Definition.—Telangiectasis is a term applied to a vascular new growth or enlargement of capillaries developed in adult life.

Telangiectases are *acquired* growths; nevi are *congenital* growths.

Symptoms.—They occur either in circumscribed, elevated, pea-sized patches, with radiating capillaries (*nævus araneus, spider nevus*), or as a generalized dilatation of vessels (*rosacea*). The latter is apt to be complicated by acne lesions. The face and chest are the regions usually affected.

Treatment.—The condition is most successfully treated by electrolysis.

LYMPHANGIOMA.

Derivation.—ἀγγεῖον, vessel. *Lympha,* lymph.

Symptoms.—The disease is extremely rare. There are two varieties:

LYMPHANGIOMA CIRCUMSCRIPTUM (*lymphangiectodes*) is *characterized by* numerous small, closely aggregated, deep-*seated translucent* vesicles, which have either the normal tint

of the skin or are yellowish or pinkish. They are usually seated upon the upper parts of the extremities.

The disease, as a rule, makes its appearance in infancy or early childhood.

LYMPHANGIOMA TUBEROSUM MULTIPLEX appears as numerous, scattered, pea- to bean-sized, elevated, brownish-red, glistening tubercles, occurring most frequently upon the trunk. The tubercles are somewhat painful on pressure.

Pathology.—Lymphangioma shows, under the microscope, both dilatation of preëxisting lymph-channels and formation of new lymphatic vessels and spaces.

Treatment.—When desirable, extirpation by means of electrolysis or excision.

RHINOSCLEROMA.

Derivation.—*Ρίς*, or *ῥίν*, the nose; *σκληρός*, hard.

Definition.—Rhinoscleroma is a rare disease, affecting the skin and mucous membrane of the nose, and characterized by irregularly shaped, flattened new growths of almost stony hardness.

Symptoms.—The growth, which begins usually upon the alæ of the nose, consists of circumscribed, dense, hard nodules, which tend to become confluent. The overlying skin is normal in color or may be reddened. The disease runs an extremely slow course, the growths gradually encroaching upon the nares until partial or complete stenosis is produced. Ulceration rarely, if ever, occurs. There are no subjective symptoms.

Pathology.—The growth is looked upon as an infectious granuloma. Bacilli have been isolated which are believed to be causative. The microscope shows a dense cell infiltration.

Prognosis.—Unfavorable. The affection usually persists throughout life.

Treatment.—Antiseptic tampons or tents are va preserve the caliber of the nasal orifices. Caustics knife have been used, but the results of treatment ar isfactory. Excision is followed by recurrence.

FIG. 79.—RHINOSCLEROMA.—(*After Hebra.*)

LUPUS ERYTHEMATOSUS.

Derivation.—*Lupus,* a wolf.

Synonyms.—Lupus erythematodes; seborrhea congestiva; lupus non-exedens.

Definition.—Lupus erythematosus is a cutaneous new growth characterized by well-defined reddish patches covered with yellowish or grayish adherent scales.

Symptoms.—The disease begins as one or more rounded or oval, pinhead- to pea-sized erythematous spots, which increase in size, either by peripheral extension or by coalescence of neighboring lesions. When fully developed, the disease appears as one or more sharply marginated, reddish or violaceous patches, varying in size from a small coin to the palm of the hand. The surface is covered with grayish or yellowish scales, firmly adherent to and dipping down into

the patulous and distended openings of the sebaceous glands. The border of the patch is somewhat elevated, while the central portion is slightly depressed. Whitish atrophic scarring is usually present although ulceration never occurs.

FIG. 80.—LUPUS ERYTHEMATOSUS, THE SO-CALLED "BUTTERFLY-SHAPED PATCH."

There is more or less infiltration and thickening. The subjective symptoms consist of moderate itching and burning.

The region most frequently affected is the face, particularly the cheeks and nose. The lips and, more rarely, the buccal mucous membrane may also be attacked.

The disease pursues a slow course, lasting months, and at times years. Occasionally involution of the patches occurs, with or without the persistence of scars.

Etiology:—The cause is obscure. Erythematous lupus is

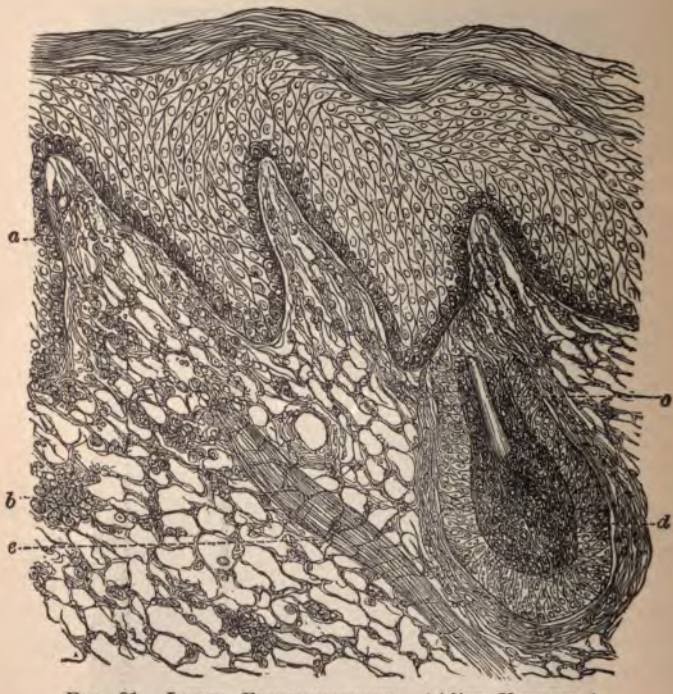

FIG. 81.—LUPUS ERYTHEMATOSUS.—(*After Neumann.*)
a. Enlarged papillæ with cell infiltration. *b.* Great accumulation of cells. *c.* Hair. *d.* Sebaceous gland with infiltration. *e.* Arrector pili.

essentially a disease of adult life. It is more common in women than in men. Disorders of the sebaceous glands act as predisposing causes, and a seborrhea not infrequently precedes its development. French writers believe the disease is caused by the toxins of the tubercle bacillus.

Pathology.—Lupus erythematosus is considered by some as a new growth, by others as a chronic inflammation. There is visible under the microscope a dense, small cell infiltration in the upper layers of the corium, particularly around the blood-vessels. Some of these cells are observed later to undergo granular and fatty degeneration. The sebaceous glands are hypertrophied. The layers of the epidermis are atrophied.

Diagnosis.—Lupus erythematosus may be distinguished from lupus vulgaris as follows:

LUPUS ERYTHEMATOSUS.	LUPUS VULGARIS.
1. Develops in adult life.	1. Develops in childhood or youth.
2. Disease is superficial.	2. Disease is deep-seated.
3. The lesions are well-defined scaly patches.	3. The lesions are discrete papules and tubercles.
4. Sebaceous ducts patulous or distended.	4. Sebaceous system not involved.
5. Ulceration never occurs.	5. Ulceration with scarring nearly always present.

Prognosis.—Favorable as to ultimate cure, but guarded as to duration of disease.

Treatment.—No known drug has any constant influence upon the disease, although such remedies as iodin, arsenic, cod-liver oil, etc., are occasionally of value.

The local treatment consists of the use of sedative or stimulating applications, caustics or surgical manipulation according to the nature of the case.

Inasmuch as a certain number of cases get spontaneously well with little or no scarring, the milder remedies should always be given a fair trial before proceeding to the use of caustics and the like.

Most cases do well under stimulating applications. An admirable method is to vigorously rub into the part, every day or every other day, sapo viridis or the tincture of green

soap. This may be followed by a soothing ointment.

Sulphur, either in ointment (ʒj to ʒij of precipitated sulphur to ℥j) or lotion, is a most efficient remedy.

A combination of sulphur and tar makes a useful formula:

℞. Sulph. præcip., ... ʒj
Ol. cadini, ... fʒj
Ung. zinci oxidi, ... ℥j. M.
Sig.—Apply twice a day.

Crocker speaks well of the use of collodion either alone or with salicylic acid (gr. x-xxx to ʒj) incorporated in it.

Plasters are frequently of great value. Those most employed are the ordinary mercurial plaster and a ten to twenty per cent. salicylic acid plaster.

When these remedies fail, and when the affection is severe and of long standing, one may cautiously resort to the use of such caustics as pure carbolic or trichloracetic acid, liquor potassæ, nitrate of silver, etc.

Scarification and superficial curetting are often followed by good results. Concentrated sun and electric light (Finsen treatment) and the X-rays have acted well in some cases.

LUPUS VULGARIS.

Derivation. *Lupus*, a wolf.

Synonyms. Lupus exedens; lupus exulcerans; noli-me-tangere; tuberculosis of the skin (one form).

Definition. Lupus vulgaris is a tuberculous cellular new growth, characterized by reddish or brownish patches consisting of papules, nodules, and flat infiltrations, usually terminating in ulceration and scarring.

Symptoms.—The disease commonly begins as numerous pinpoint- to pinhead-sized, grouped or disseminated, reddish, yellowish, or brownish flat papules. They are softer than the surrounding skin, in which they appear to be imbedded. Hutchinson has likened their appearance to "apple jelly."

These papules develop later into pea-sized or larger tubercles or nodules, which ultimately become aggregated in variously sized and shaped patches covered with imperfectly formed epidermis. After a variable duration the nodules

FIG. 82.—LUPUS VULGARIS.

coalesce chiefly by individual extension, forming dull red, raised, soft patches.

The lupus nodules or patches may remain stationary for some time, but sooner or later undergo retrogressive change.

The lesions may disappear by absorption, leaving a somewhat scarred, scaly, and atrophic skin (*lupus exfoliativus*), or, as is the more usual course, by ulceration, with resulting crusts and cicatrices (*lupus exedens, lupus exulcerans*).

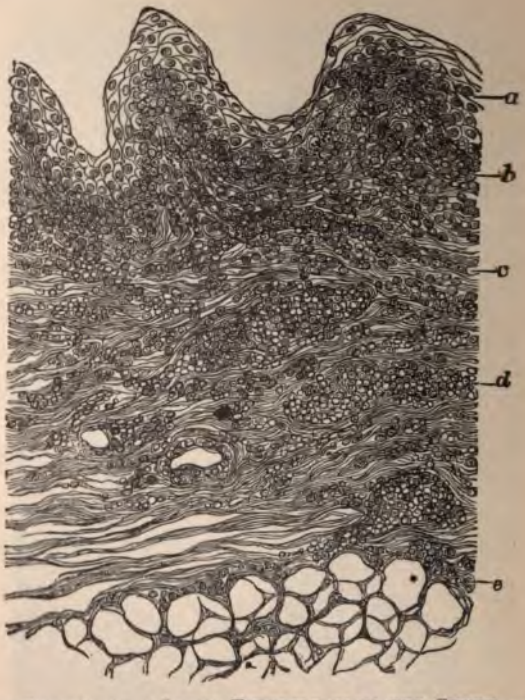

FIG. 83.—SECTION OF A LUPUS TUBERCLE FROM THE CHEEK.—(*After Neumann.*)

a. Rete Malpighii. *b.* Cell infiltration of the papilla. *c* and *d.* Accumulation of cells in the upper and lower layers of the cutis. *e.* The same in the panniculus adiposus.

At times exuberant granulations spring up upon the borders of the ulcer (*lupus hypertrophicus*), or there may develop even papillomatous outgrowths (*lupus papillomatosus*).

The most frequent seat of lupus is upon the face, particularly the nose, cheeks, and ears. The trunk and extremities may also be involved. Besides the skin, lupus occasionally attacks the mucous membrane and cartilage of the nose, mouth, pharynx, larynx, or ears.

Subjective symptoms are, as a rule, wanting, although there may be slight pain.

The course of the disease is eminently chronic, the affection persisting for years, and frequently a lifetime.

Etiology.—The vast majority of cases begin before the age of twenty, and many before the age of ten. The disease, however, is never congenital.

Lupus vulgaris is due to the invasion of the skin by the tubercle bacillus.

Pathology.—A section of lupus tissue shows, under the microscope, sharply circumscribed nests of cell infiltration in the deeper layers of the corium. Epithelioid cells are present in varying numbers, and giant cells in abundance. Tubercle bacilli are few, and only discoverable by examination of many sections. When ulceration occurs, the center of the nodules undergoes coagulation necrosis and fatty degeneration. Inoculation of lupus tissue into a guinea-pig will produce a generalized tuberculosis.

Diagnosis.—The diseases most apt to be confounded with lupus vulgaris are the tubercular syphiloderm, lupus erythematosus, and epithelioma.

Lupus Vulgaris.	Tubercular Syphiloderm.
1. Develops usually before the age of puberty.	1. Develops after the age of puberty.
2. Course slow.	2. Course rapid.
3. History, perhaps, of scrofulous hereditary tendency.	3. History of infection.
4. Concomitant signs of tuberculous diathesis.	4. Concomitant signs of syphilis.
5. Nodules soft.	5. Nodules hard.

6. Ulcers are comparatively superficial, with irregular undermined edges; discharge slight; crusts scant and reddish-brown.	6. Ulcers are deep, with sharp-cut edges; discharge copious; crusts bulky and greenish.
7. Scars yellowish, shrunken, and hard.	7. Scars whitish, soft and smooth.
8. Refractory to all but destructive measures.	8. Rapid healing under the iodids and mercury.

The differential diagnosis from lupus erythematosus will be found under that disease.

LUPUS VULGARIS.	EPITHELIOMA.
1. Develops usually before puberty.	1. Develops in middle and advanced life.
2. Course extremely slow.	2. Course more rapid.
3. Little or no pain.	3. Usually painful.
4. Ulcers multiple and superficial.	4. Ulcers single and deep.
5. Edges and base soft.	5. Edges and base hard. Characteristic pearly border.

Prognosis.—The disease runs an eminently chronic course. The prognosis depends upon the age of the patient and the form, extent, and duration of the disease. Occurring in small, circumscribed patches the prognosis is favorable.

Treatment.—General hygienic measures, such as nutritious diet, fresh air, exercise, etc., should receive attention. In many cases the administration of such remedies as cod-liver oil, iodid of iron, etc., is indicated, although no direct curative influence is to be expected from their use. Thyroid extract and tuberculin have been used in some cases with encouraging results. Their curative value, however, is at the present time still conjectural.

Local treatment has for its object the extirpation of the lupus tissue with as little resultant scarring as possible.

Before resorting to chemical caustics or surgical interference, it is well in some cases to employ milder measures.

In hyperemic cases the condition is sometimes improved by the continued application of calamin lotion. Mercurial plaster occasionally exerts a beneficent influence on the disease. A salicylic acid (twenty per cent.), creasote (forty per cent.), or resorcin plaster may be used with good results.

Most cases, however, require more heroic treatment.

The *solid stick of nitrate of silver* is useful in the treatment of small discrete lesions. It is bored into the tissue until the nodule is destroyed. Every few days new lesions are attacked.

FIG. 84.—DERMAL CURETS.

Pyrogallic acid is a slow but practically painless caustic. It may be used in ointment or as a paint.

Brocq advises the following:

℞. Acidi pyrogallici,
Acidi salicylici, ... āā gr. l
Collodii, ... f℥j. M.

SIG.—Paint on the part every day until a slough is produced.

Arsenious acid is a rapid caustic, exerting a selective action upon diseased tissue. It is, however, very painful, and can only be used over small areas on account of the danger of absorption.

℞. Acidi arseniosi, ... gr. xx
Pulv. acaciæ, ... ʒj.
Aquæ, q. s. ft. past. M.

SIG.—Spread on lint and apply for twenty-four hours. Then poultice until slough comes away.

Chlorid of zinc is an efficient caustic, not so painful as arsenic. It does not, however, select diseased tissue.

℞. Zinci chloridi, ... ℥xvj
Pulv. opii, ... ℥iss
Acidi hydrochlorici, ... f℥vj
Aq. bullientis, ... f℥xx. M.
(Middlesex Hospital formula.)

SIG.—To one ounce of the solution add two drams of wheaten flour. Spread the paste upon lint and apply for twenty-four hours.

Curetting is an extremely valuable procedure. It is often supplemented by the use of a caustic or the application of the Paquelin cautery.

FIG. 85.—MULTIPLE SCARIFIER.

Scarification is a most useful measure, particularly in diffuse superficial patches. Numerous parallel incisions, crossed at right angles by others, are made through the skin by means of a sharp scalpel or scarifier. This is often advantageously followed by the application of an iodoform ointment or a bichlorid of mercury lotion.

The *galvano-cautery* and the *Paquelin cautery* find a distinct field of usefulness in the treatment of certain forms of this disease.

The employment of concentrated sunlight and electric light with an apparatus specially devised by Finsen, has given most excellent results both as regards permanence of cure and subsequent cosmetic appearance. The treatment is however, long and tedious and requires an expensive outfit. Within recent months most encouraging results in the treatment of lupus have been reported from the use of the X rays; one advantage of the latter treatment is that a large

portion or the entire diseased area may be exposed to the rays at one time thus greatly shortening the period of treatment.

BLASTOMYCETIC DERMATITIS.

Definition.—A rare disease, produced by the invasion of the skin by the blastomyces, and characterized by warty or papillomatous outgrowths.

Symptoms.—The dorsum of the hand and the anterior surface of the leg are the regions most frequently affected. The disease begins as a maculo-papule or nodule, which tends to break down and suppurate.

Later the surface becomes warty or papillomatous and exudes a puriform secretion. The disease pursues a chronic course. It must be differentiated from verrucose tuberculosis, lupus vulgaris, and the late syphiloderm, to which it may bear a very close resemblance. The yeast fungus is found in the skin and may be grown in culture.

Treatment.—In at least one case considerable improvement followed the use of potassium iodid. The local treatment is practically the same as that employed in lupus vulgaris.

SCROFULODERMA.

Derivation.—*Scrofa,* a sow.

Definition.—Scrofuloderma is a tuberculous affection of the skin and subcutaneous tissues, originating in the lymph-glands and terminating in ulceration of the integument.

Symptoms.—The affection begins in one or more lymph-glands, which become swollen, constituting variously sized tumors, unaccompanied by redness or pain. Later these glands undergo caseation and suppuration, the overlying skin becoming tense, violaceous, and riddled with sinuses, which permit the escape of a caseous, sanious pus.

The scrofulous ulcer is usually almond-shaped, with thin, violaceous, undermined edges, and an uneven base made up of pale, flabby granulations.

The course is slowly progressive. When cicatrization occurs the scars are seen to be irregular, knotty, and hard.

The most common seat of the disease is about the face and neck.

Conjunctivitis, keratitis, blepharitis, rhinorrhea, otorrhea, bone trouble, etc., are at times associated with the lymphatic and cutaneous involvement.

Etiology.—Scrofuloderma is a form of cutaneous tuberculosis and is due to the tubercle bacillus.

Diagnosis.—From lupus vulgaris, scrofuloderma may be distinguished by the absence of outlying tubercles and patches. From syphilis it may be distinguished by the peculiar character of the scrofulous ulcer, the history, course, and presence of other signs of struma.

Treatment.—The constitutional treatment consists of good food, proper hygiene, and the use of such tonics as cod-liver oil, and iodid of iron.

The local treatment has for its object the destruction of the ulcers. This may be accomplished by the use of the curet or caustics.

TUBERCULOSIS CUTIS ORIFICIALIS.

This form of tuberculosis of the skin is characterized by indolent, discrete, round or oval, shallow, granulating ulcers, often covered with thin crusts, occurring in the neighborhood of the orifices of the body (anus, vulva, nose, and mouth). The ulcers are painless, have no tendency to heal, and pursue a slow, progressive course. There is nearly always visceral tuberculosis present, and frequently there are lesions of the adjacent mucous tracts which show yellowish miliary papules.

This affection was formerly regarded as the sole manifestation of true tuberculosis of the skin.

VERRUCA NECROGENICA.

Synonyms.—Tuberculosis verrucosa cutis; postmortem wart; anatomic tubercle.

Definition.—Verruca necrogenica is a tuberculous dis-

FIG. 86.—VERRUCA NECROGENICA.—(*After model in Guy's Museum.*)

ease occurring usually about the knuckles, characterized by one or several verrucous nodules.

Symptoms.—The affection begins at the site of an abrasion as an inflammatory vesico-pustule; this slowly increases in size, and is attended by burning and itching. The fully developed lesion is usually bean-sized, flattened, and covered with a horny or warty surface or with crusts. The fingers and knuckles are the favorite seats.

A somewhat similar condition, described under the name of *tuberculosis verrucosa cutis*, is characterized by circum-

scribed, warty plaques, of a violaceous color, occurring most commonly upon the forearms and legs.

Etiology.—The affection occurs in physicians, dissecting room attendants, and those coming in contact with the cadaver.

Pathology.—The disease is produced by inoculation with the tubercle bacillus. This organism is found in the tissues.

Prognosis.—Unless proper treatment is instituted the disease is progressive. General tuberculous infection is rare.

Treatment.—The treatment consists of destruction of the diseased tissues by means of the curet or such caustics as nitric acid, caustic potash, etc. The preliminary application of a twenty-five per cent. salicylic acid plaster facilitates the treatment.

SYPHILODERMA.

Derivation.—Σῦς, and φίλος, a companion of swine.

Synonyms.—Syphilis cutanea; dermatosyphilis; syphilis of the skin; lues.

Definition.—Syphilis is a chronic, specific, contagious, hereditary disease, involving with predilection the skin and nervous system, but capable of affecting any organ or tissue.

Symptoms.—Syphiloderma constitutes about ten per cent. of all skin affections.

The eruption of syphilis may be macular, papular, vesicular (rare), pustular, bullous, tubercular, gummatous, or mixed.

General characteristics of syphilitic eruptions:

1. Distribution.—Early or secondary eruptions are generalized and symmetric. The late or tertiary eruptions are circumscribed and asymmetric.

2. Color.—The color is brownish or yellowish-red, often ham- or copper-colored. The lesions have a cold, non-inflammatory appearance.

3. Absence of subjective symptoms.—Itching, burning, and pain are, as a rule, absent.

4. Polymorphism or multiformity.—Several types of lesions are often seen associated, such as papules and pustules.

5. Configuration.—Papular and tubercular eruptions, particularly the latter, are apt to assume a circular, crescentic, or serpiginous arrangement.

The early eruptions of syphilis are often preceded by fever, lassitude, headache, muscular and osseous pains, and accompanied by anemia, enlargement of lymphatic glands, congestion and ulceration of throat, mucous patches, alopecia, etc.

The early eruptions may be distinguished from the late eruptions as follows:

Early Eruptions.	Late Eruptions.
1. Accompanied by constitutional disturbances, sore throat, alopecia, etc.	1. Accompanied by osteocopic pains and stigmata of former manifestations.
2. Eruption generalized and symmetric.	2. Eruption circumscribed and asymmetric.
3. Lesions comparatively superficial and not destructive.	3. Lesions deep-seated and destructive.
4. Eruption macular, papular, or pustular.	4. Eruption tubercular, gummatous, and ulcerative.

Syphiloderma Erythematosum (*Macular Syphiloderm, Roseola*).—The macular syphilide is the most frequent form assumed by the early eruption. It develops, usually, from six to eight weeks after the initial lesion. It is characterized by rounded, oval, or irregular, pea- to finger-nail-sized, ill-defined macules, which are at first of a rose-red color, later becoming violaceous, brownish, or yellowish. The trunk, particularly the anterior surface, and the extremities are most abundantly involved. The face is usually exempted. The eruption lasts from one to four weeks. Papular lesions may also be present.

Diagnosis.—The macular syphiloderm is to be differentiated from measles, tinea versicolor, and the rashes due to copaiba and other drugs.

MACULAR SYPHILODERM.	MEASLES.	TINEA VERSICOLOR.	DERMATITIS MEDICAMENTOSA (COPAIBA, QUININ)
(1) Associated symptoms of syphilis, mucous patches, alopecia, enlarged glands, etc.	(1)	(1)	(1)
(2) Fever occasional and usually slight.	(2) Considerable fever and catarrhal symptoms involving eyes, throat and chest.	(2)	(2) Fever occasional.
(3) Eruption chiefly on trunk and extremities; face usually free.	(3) Face first involved; later trunk and extremities	(3) Eruption confined to chest, shoulders and back.	(3) Face often involved.
(4) Eruption consists of pea to finger-nail-sized, oval or rounded macules, at first rose-red, later violaceous, brownish or yellowish.	(4) Eruption consists of pinkish-red irregular macules or maculo-papules, at times crescentically arranged; appearance "blotchy."	(4) Eruption consists of large irregular, yellowish-brown macules. Furfuraceous scaling. Fungus present.	(4) Eruption erythematous or urticarial.
(5) Itching absent.	(5) Itching moderate.	(5) Itching moderate.	(5) Itching severe.

SYPHILODERMA PAPULOSUM occurs as two varieties—the large and the small papular syphilide.

The SMALL PAPULAR SYPHILODERM (*miliary papular syphilide*) may occur as an early or late manifestation. It is characterized by a profuse eruption, most abundant upon the trunk, arms, and thighs, consisting of disseminated or grouped, pinhead- to millet-seed-sized, rounded or acuminated firm papules, with vesicular, pustular, or scaly summits. The color is at first bright red, later brownish-red. Small pustules or large papules may be interspersed.

Diagnosis.—The miliary papular syphiloderm may be distinguished from lichen scrofulosum, psoriasis punctata, ker-

atosis pilaris, and lichen ruber by the distribution and extent of the eruption, the presence of interspersed large papules and pustules, and the associated symptoms of syphilis.

The LARGE PAPULAR SYPHILODERM (*lenticular papular*

FIG. 87.—SYPHILODERMA PAPULO-TUBERCULOSUM.

syphilide) is an extremely common manifestation of syphilis, following often upon the macular eruption. It is characterized by pea- to fingernail-sized, rounded or oval, convexly flat, firm, brownish-red papules. The lesions develop slowly, and are at first smooth, later scaly. The eruption is usually

extensive, the forehead, nape of neck, chin, arms, genitals, etc., often being involved. The eruption persists for several weeks or months, responding rather readily to treatment.

The large, flat, papular syphiloderm may undergo certain changes, giving rise to (1) the moist papule and (2) the squamous papule.

The *moist papule* (*mucous patch, flat condyloma*) is a

FIG. 88.—MOIST PAPULES.

modified, large papular syphilide, occurring upon opposing skin surfaces such as the nates, perineum, genitalia, etc. It differs from the dry papule in being moist, softer, and flatter, and covered with a grayish mucoid pellicle made up of macerated epidermis. Large flat patches are occasionally formed through the coalescence of neighboring lesions. Moist papules occasionally become hypertrophic and covered with

warty papillary growths (*hypertrophic* or *vegetating papules*).

The PAPULOSQUAMOUS SYPHILODERM (*squamous syphilide*) results when the papules begin to desquamate. The lesions are flattened and covered with thin, scanty, dirty-grayish scales. The eruption is rarely extensive. It may occur anywhere upon the body, but shows a predilection for the palms and soles (*palmar* and *plantar syphiloderm*), where it constitutes an obstinate manifestation. When both palms or soles are affected the eruption is probably an early one; when unilateral it is late.

Diagnosis.—The disease most apt to be confounded with the papulosquamous syphiloderm is psoriasis.

PAPULOSQUAMOUS SYPHILODERM.	PSORIASIS.
1. History of syphilis.	1. History, perhaps, of previous outbreaks.
2. Concomitant signs present.	2. No associated signs.
3. Favorite seats, palms and soles.	3. Favorite seats, knees and elbows.
4. Itching usually absent.	4. Itching present.
5. Multiformity of lesions; uniformity in size.	5. Uniformity of lesions; great variation in size.
6. Scales scanty and dirty-grayish.	6. Scales abundant, lamellar, and silvery.
7. Beneath the scales, infiltrated, dull red papules.	7. Beneath the scales, flat, reddish patches.

SYPHILODERMA VESICULOSUM.—The vesicular syphilide is by far the rarest of all the cutaneous manifestations of syphilis. It occurs as small miliary or larger pea-sized (*varicelliform syphilide*), occasionally umbilicated vesicles, developing usually upon regions where the skin is thin. Papules and pustules may also be present. The eruption is an early one and runs a rapid course.

SYPHILODERMA PUSTULOSUM may be divided into four sub-varieties: (1) Small acuminated pustular syphilide, (2) large acuminated pustular syphilide, (3) small flat pustular syphilide, (4) large flat pustular syphilide.

The SMALL ACUMINATED PUSTULAR SYPHILODERM (*miliary pustular syphilide*) occurs as an early or late secondary manifestation. It is usually profusely generalized, consisting

FIG. 89.—PAPULO-SQUAMOUS SYPHILODERM OF THE PALM.

of small, disseminated or grouped, pinhead- to millet-seed-sized, acuminated pustules seated upon a dull red papular base. The lesions are located at the mouths of hair-follicles, *and are seen to* be perforated by hairs. They soon dry to

crusts, which fall off, leaving a fringe-like annular epidermal exfoliation around the base, which has been termed the "collarette." Miliary papules may also be present. The favorite regions are the arms, thighs, chest, and back.

The LARGE ACUMINATED PUSTULAR SYPHILODERM (*acneiform syphilide, varioliform syphilide*) is a rather uncommon manifestation, occurring early and running a rapid and benign course. It consists of split-pea-sized or larger acuminated pustules, somewhat resembling acne or variolous lesions. The pustules dry to crusts, beneath which superficial ulceration takes place. The favorite regions are the scalp, face, and trunk; more rarely the extremities.

Diagnosis.—Acne and smallpox are to be differentiated from this form of syphilide.

PAPULOPUSTULAR SYPHILODERM.	ACNE.
1. Concomitant signs of syphilis.	1. Absent.
2. Occurs usually in adult life.	2. Occurs at age of puberty.
3. Course acute.	3. Course chronic, with exacerbations.
4. Distribution general.	4. Limitation of lesions to face.
5. Color brownish-red or ham-colored.	5. Color light or dark red.
6. Tendency to ulceration.	6. No tendency to ulceration.

Smallpox may be distinguished by the more severe constitutional disturbance, the early shot-like induration, the course of the lesions, their umbilication, and the absence of concomitant signs of syphilis.

The SMALL FLAT PUSTULAR SYPHILODERM (*impetigoform syphilide*) is characterized by small, flat, pea-sized pustules, grouped in irregular clusters and occurring in the first year of the disease. Crusting occurs early and is profuse (*pustulo-crustaceous syphilide*), the color being yellowish, greenish or brownish. Beneath the crusts superficial or deep ulceration occurs. The favorite seats are the nose, mouth, beard, scalp, and genitals.

Diagnosis.—The small, flat, pustular syphilide may be differentiated from contagious impetigo and pustular eczema by the history and course of the disease, the occurrence of ulceration, and the concomitant signs of syphilis.

The LARGE FLAT PUSTULAR SYPHILODERM (*ecthyma-form syphilide*) occurs as a generalized eruption, consisting of large fingernail-sized, flat pustules, seated upon a dark red base. The pustules tend rapidly to crust.

There are two varieties—the superficial and the deep. The superficial form is characterized by flat, roundish or oval, brownish crusts, beneath which is a superficial ulceration. This is a common and benign manifestation, occurring during the first year of the disease. The favorite seats are the back, shoulders and extremities.

In the deep form, or *rupia,* the crusts are more bulky, conical, of a greenish or blackish color, and concentrically stratified, like the layers of an oyster-shell. Beneath the crust is a deep, pinched-out ulcer, covered with a greenish-yellow, puriform secretion. It is a late and malignant form.

SYPHILODERMA TUBERCULOSUM (*Tubercular Syphilide*). —This is a late or tertiary manifestation, occurring usually between two and ten years after infection. It is characterized by disseminated or grouped pea- to hazel-nut-sized, rounded or acuminated, smooth, firm, deeply seated nodules. The color is brownish-red, bluish-red, coppery, or yellowish-brown. The lesions are, as a rule, comparatively few, and tend to become aggregated in groups, arranging themselves in circles or segments thereof. The coalescence of neighboring groups may produce patches of serpentine configuration (*serpiginous tubercular syphiloderm*). The eruption develops most frequently upon the face, particularly about the forehead and nose.

Tubercles disappear either by absorption, leaving a brownish stain, or by ulceration, with the production of scars. The

ulcer is deeply punched out, with sharp-cut edges, often crescentic in shape, and covered with a grayish-yellow, gummy secretion, which dries into brownish or greenish crusts.

Diagnosis.—The tubercular syphiloderm is to be distinguished from lupus vulgaris, leprosy, and epithelioma, particularly the first named.

Tubercular Syphiloderm.	Lupus Vulgaris.
1. Develops after the age of puberty.	1. Develops usually at or before puberty.
2. Course more or less rapid.	2. Course extremely slow.
3. History of infection.	3. History negative.
4. Concomitant signs of syphilis.	4. Concomitant signs, perhaps, of tubercular diathesis.
5. Nodules firm.	5. Nodules soft.
6. Ulcers are deep, with sharp-cut edges. Discharges copious, crusts bulky and greenish.	6. Ulcers superficial, with soft, irregular, undermined edges. Discharges slight, crusts scanty and reddish-brown.
7. Scars whitish, soft and smooth.	7. Scars yellowish, shrunken, and hard.
8. Rapid healing under iodids and mercury.	8. Refractory to all but destructive measures.

Syphiloderma Gummosum (*Gummatous Syphilide*).—This is a tertiary manifestation occurring some years after the contraction of the disease. It is characterized by a circumscribed infiltration in the subcutaneous tissue, manifesting itself clinically as one or several slightly raised, rounded, or flat, painless tumors (*gumma, gummy tumor, syphiloma*).

The overlying skin is in the beginning normal, becoming pinkish or reddish only when ulceration is threatened. The deposit is at first pea-sized, but in the course of several weeks or months reaches the dimensions of a hazel-nut or walnut. It then softens, breaks down, and ulcerates, destroying the skin, subcutaneous tissue, and at times other structures. The scarring is always smoother and less disfiguring than anticipated.

FIG. 90.—ULCERATING GUMMATOUS SYPHILODERM OF LEG.

Diagnosis.—The gumma may be distinguished from furuncle, carbuncle, abscess, carcinoma, fibroma, lipoma, etc., by the origin, course, and appearance of the lesion, and the associated history.

SYPHILODERMA BULLOSUM (*bullous syphilide, pemphigus syphiliticus*) occurs as an early symptom in hereditary syphilis and more rarely as a late manifestation in the acquired form. The blebs are discrete, disseminated, round or oval, pea- to walnut-sized, and surrounded by a slight areola. The contents are at first serous, rapidly becoming purulent, and drying into brownish or greenish crusts. The crusts may be large, bulky, and raised or rupial, as seen in the large, flat, pustular syphiloderm. Beneath the crusts are erosions or ulcers, which heal with the formation of pigmented cicatrices. The bullous syphilide usually occurs in broken-down, cachectic individuals.

HEREDITARY SYPHILIS.

While infants are occasionally born with the syphilitic eruption upon them, it is far more common for it to develop some weeks after birth. Nearly all cases exhibit the secondary outbreak before the end of the second month, and only rarely after the third month. The most common eruptions are the macular, papular, and bullous.

The *macular* eruption consists of fingernail- to palm-sized indistinct yellowish or brownish-red, or copper-colored erythematous patches, covered with a shining and wrinkled epidermis. The palms, soles, buttocks, thighs, and genitalia are frequently attacked. The patches may be dry or moist, the latter resembling at times erythema intertrigo or eczema.

The *papular* eruption often develops from the macular, the combination constituting the commonest syphilide observed in the infant. The papules are pea- to fingernail-sized, smooth, glazed, and usually of a brownish or yellowish-red color.

Occurring in the folds of the skin, they often degenerate into moist papules.

FIG. 91.—SYPHILITIC PAPULE FROM THE THIGH.—(*After Neumann.*) *a.* Epidermis. *b.* Rete Malpighii. *c, c.* Cell infiltration in the corium and panniculus adiposus. *d, d.* New formation of connective tissue. *e.* Panniculus adiposus.

The *bullous* eruption is usually present at birth. It consists of variously sized discrete, flat, or semi-globular blebs, *situated upon a* [illegible] lthy-looking skin. When rupture

takes place an excoriated or ulcerated base is exposed. The palms, soles, fingers, and toes are most frequently involved.

In addition to the above eruptions, the syphilitic infant presents a *weazened, senile, emaciated appearance, coryza* or *snuffles, hoarseness, mucous patches* in the mouth, etc.

Pathology.—Syphilis is an infectious granuloma due in

FIG. 92.—CIRCINATE SQUAMOUS SYPHILIDE. ×125.—(*After Crocker.*)
a. Horny layers forming scales. *b.* Oblique section of an enlarged papilla in a greatly thickened rete mucosum. *c.* Enormously enlarged papilla with cell exudation separating its fibers. *d.* Dense round cell infiltration in masses around the vessels. *e.* Similar cell exudation around a vessel of the deeper plexus. There is also a scanty cell effusion all through the corium.

all probability to the invasion of the system by a specific micro-organism.

The syphilitic process is characterized by a distinctly circumscribed and homogeneous cell infiltration, tending to spread upon the periphery, at the same time undergoing cen-

tral involution. The infiltrate, which lies in the corium and subcutaneous tissue, disappears either by absorption or ulceration.

Prognosis.—The prognosis of acquired syphilis is in the vast majority of cases favorable. Malignant cases in rare instances prove fatal. In hereditary syphilis the prognosis is guarded, many infants succumbing to the disease.

Treatment.—The treatment of syphilis is largely constitutional, although this is at times supplemented by local measures. The constitutional treatment includes the use of *mercury,* the *iodids,* and *tonics.*

Mercury is used alone in the early or secondary period, and conjoined with the use of potassium iodid in the late or tertiary stage. It exerts a specific curative influence upon the disease. It is to be used continuously for one year, and intermittently for one, two, or three years longer. The duration of the treatment in syphilis depends greatly upon the severity of the disease, and therefore varies much in different patients. Some patients after a six months' treatment remain permanently free from symptoms. Others treated for several years will continue to have outbreaks. As a matter of caution, all cases should be treated for two years, and some cases much longer.

Mercury may be administered by mouth, inunction, hypodermic injection, fumigation, or intravenous injection.

1. *By mouth* it is usually given in pill form as:

(*a*) Hydrargyrum protiodidum, gr. ⅛-½ t. i. d.

(*b*) Hydrargyrum biniodidum or bichlodid., gr. $^1/_{16}$-$^1/_8$ t.i.d.

(*c*) Hydrarg. chlor. mit., gr. ¼-½ t. i. d.

(*d*) Hydrarg. cum creta, gr. j-ij t. i. d.

2. *Inunctions* are of great efficiency and may always be relied upon to produce a rapid effect. One dram of mercurial ointment is rubbed in each night.

3. *Hypodermic injections* are used to produce a sudden and vigorous impression upon the disease, and are principally

indicated in malignant cases or where important organs are affected. Both soluble (corrosive chlorid) and insoluble (mild chlorid) preparations are employed.

4. *Fumigations* or mercurial vapor baths are useful, and may be used in appropriate cases. Calomel (gr. xx-xxx) is the preparation usually employed.

5. *Intravenous injections* of soluble mercurial salts have been recently introduced, and are said to be rapidly efficient, painless, and free from danger.

Iodids.—The potassium salt is the drug usually administered. It is of particular value in late eruptions, and should be combined with mercury. Many doubt the curative value of the iodids and look upon them merely as absorbents. The iodids are ordinarily given in from five- to fifteen-grain doses. The following makes a palatable combination:

℞. Hydrarg. chlor. corrosiv., . . . gr. j
Potass. iodid., ... ℥ss
Tr. cardamoni comp., . q. s. ad f℥iij. M.
Sig.—One tablespoonful in water after meals.

When the iodids are not well borne by the stomach, it is well to administer them in saturated solution, well diluted in milk, given immediately after meals.

Tonics.—Such drugs as iron, cod-liver oil, quinin, etc., are extremely useful at times in building up the health of syphilitic patients. They may be used in the secondary stage in conjunction with mercury. The syrup of hydriodic acid is often of value when the iodids are not tolerated.

Local Treatment.—The following are some of the local remedies used in the treatment of syphilodermata:

Corrosive chlorid baths (two drams to thirty gallons), in extensive pustular eruptions.

Powdered calomel, as a dusting-powder, for moist papules.

Mercurial plaster, applied to chancre and to late tubercular lesions.

Black-wash or bichlorid lotion, in offensive ulcerations.

Treatment of Hereditary Syphilis.—The remedies are practically the same as those employed in the treatment of acquired syphilis. Preference is, however, usually given to (1) mercurial inunction, (2) calomel, gr. $^1/_{12}$-$^1/_6$ t. i. d., (3) mercury with chalk, gr. ½-j t. i. d.

The inunction may be prescribed as follows:

℞. Ung. hydrargyri,
Adipis, ... āā ℥ss.
M. et in part. No. viij div.
Sig.—Spread one portion upon abdominal binder each day.

The syrup of the iodid of iron in five- or ten-minim doses constitutes a valuable tonic in the later stages of the disease.

LEPRA.

Derivation.—*Λεπρὸς*, rough or scaly.

Synonyms.—Leprosy; elephantiasis græcorum.

Definition.—Leprosy is a chronic infectious disease due to a specific bacillus, affecting with predilection the skin and nervous systems, with the production of infiltrations, ulcerations, anesthesia, paralyses, and gangrene.

Symptoms.—The disease is, like syphilis, a constitutional one, and may affect any organ or tissue. Its course, as a rule, is slow and insidious. Premonitory symptoms such as mental depression, languor, malaise, drowsiness, anorexia, nausea, chills, febrile attacks, and bone pains may precede the characteristic manifestations of the disease by several weeks, months, or years.

There are two forms of leprosy, (1) tubercular leprosy and (2) anesthetic leprosy. The two forms may coexist, constituting the mixed type.

Lepra Tuberculosa (*Tubercular Leprosy*).—This form commonly begins as smooth, reddish, yellowish, or brownish, bean-sized infiltrated macules (*lepra maculosa*), which

may disappear, or after a variable duration develop into tubercles. The latter vary in size from a pea to a hazel-nut, are yellowish, reddish-brown, or bronze-tinted, and most com-

FIG. 93.—TUBERCULAR LEPROSY.—(*After Van Harlingen.*)

monly situated about the face. The forehead is particularly apt to be affected, the thickening and the exaggeration of the folds of the skin producing the so-called leonine expression (*leontiasis*).

Leprous tubercles persist often for a long time. They may disappear by absorption or ulceration, the latter occurring for the most part about the fingers and toes. The mucous membranes may be attacked early in the disease.

LEPRA ANÆSTHETICA (*Anesthetic Leprosy*).—This form is not infrequently preceded by hyperesthesia, pruritus, and

FIG. 94.—MUTILATION OF HANDS IN ANESTHETIC LEPROSY.—(*After Van Harlingen.*)

neuralgic pains. The first cutaneous manifestation consists usually of an irregular outbreak of blebs, which rupture and are followed by pigmentation. Instead of blebs there may develop erythematous spots of a bluish-red or reddish-brown color, later becoming yellowish or brownish. These spread by peripheral extension, at the same time healing in the center. Over these areas there is at first hyperesthesia; later this

gives way to anesthesia, so that the prick of a pin can not be felt.

In advanced cases there may occur severe nerve pains, paralyses, wasting of muscles, and loss of fingers and toes by absorption, ulceration, or gangrene (*lepra mutilans*).

Etiology.—Leprosy is caused by the invasion of the organism by the *bacillus lepræ*. Heredity, climate, soil, and mode of living act as predisposing causes.

FIG. 95.—ADVANCED CASE OF MIXED TUBERCULAR AND ANESTHETIC LEPROSY.

The contagion may be effected through direct or mediate inoculation, the upper respiratory passages probably constituting a frequent avenue of entrance of the micro-organism.

Pathology.—The disease consists of a deposit of cells in the corium and subcutaneous tissue, similar to those seen in lupus and syphilis. The specific bacillus is found in the tubercles, infiltrations, lymphatic glands, nerves, etc.

Diagnosis.—Advanced cases of leprosy are easily recognized. The disease may be confounded with syphilis, mor-

phea, vitiligo, and lupus. The occurrence of anesthesia and the history and course of the disease will usually enable one to make the diagnosis. In doubtful cases the microscope should be resorted to, with the view of discovering the bacilli in the affected tissues.

Prognosis.—Always unfavorable. The disease progresses, with rare exceptions, to a fatal termination. The course is more rapid in the tubercular than in the anesthetic form.

Treatment.—Nutritious food, good hygiene, and removal to a healthful climate are important therapeutic measures.

The remedies which have proven most valuable in the treatment of leprosy are chaulmoogra oil and gurjun oil, used both internally and externally (in the tubercular variety), and strychnin in large doses (in the anesthetic form).

FRAMBESIA.

Derivation.—Fr. *framboise,* a raspberry.

Synonyms.—Yaws; pian; Peruvian wart.

Definition.—Frambesia is an infectious disease, endemic in certain tropical countries, characterized by papules, tubercles, and tumors having the appearance of raspberries.

Symptoms.—The disease, which is preceded by prodromal constitutional symptoms, begins as small, pinhead- to pea-sized papules or tubercles, which resemble red currants or raspberries. These increase to the size of cherries, at the same time becoming flatter and studded with yellowish points. Ulceration occurs, with the discharge of a thin, fetid, yellowish fluid. The disease is confined to tropical countries, and is observed chiefly on the west coast of Africa.

The face, upper and lower extremities, and genitalia are usually affected.

The disease may last for months, and in debilitated individuals for years.

Frambesia is contagious, and due to a specific bacillus.

Treatment.—In simple cases the disease yields readily to mild parasiticides. In severe cases tonics, such as quinin, iron, and strychnin, are required.

EPITHELIOMA.

Synonyms.—Epithelial cancer; carcinoma epitheliale; rodent ulcer.

Symptoms.—Three varieties of epithelioma are recognized—the superficial, deep, and papillary.

FIG. 96.—SQUAMOUS EPITHELIOMA.

FIG. 97.—CYLINDRIC-CELLED EPITHELIOMA.

SUPERFICIAL EPITHELIOMA (*Flat* or *Discoid Variety*).—This form of the disease makes its appearance as one or more grouped yellowish or reddish papules, or as flat infiltrations, warty outgrowths, or degenerative seborrheic patches. These show a tendency to become excoriated and covered with brownish or yellowish crusts. In the course of several months or years the deposit increases or new lesions appear, which undergo degeneration with the formation of superficial ulcers.

The ulcer is usually roundish, with sharply defined, flat or raised, indurated, rounded, pearly edges. The base is hard, reddish, uneven, easily disposed to bleed, and secretes a scanty yellowish fluid.

The general health is unimpaired, pain slight, and lymphatic involvement absent.

DEEP-SEATED EPITHELIOMA (*Infiltrating Variety*).—This form develops from the superficial variety or from a nodule having its seat in the corium and subcutaneous tissue. The

FIG. 98.—SUPERFICIAL FLAT EPITHELIOMA.

nodule is pea- to walnut-sized, firm, indurated, rounded or flat, shining, and of a reddish or purplish color. After a lapse of some months ulceration takes place. The ulcer is deep, rounded, or irregular in shape, with on uneven, reddened, *easily-bleeding* base, and hard, everted, purplish edges. An

areola of redness and infiltration indicates the spreading infiltration.

The lymphatic glands become involved, the pain is severe and of a lancinating character, and the patient slowly succumbs through marasmus, hemorrhage, or exhaustion.

PAPILLARY EPITHELIOMA.—This form may develop from the superficial or deep variety or from an ordinary wart. It appears either as a pea- to fingernail-sized verrucous elevation, or a larger, coin-sized, lobulated, spongy, papillary growth. The surface may be dry and covered with horny yellow scales, or moist and covered with uneven, exuberant granulations secreting a sanguineous or translucent fluid. Disintegration occurs with the production first of fissures and later of ulcers. The course is progressive and malignant.

Epithelioma involves with predilection the face, particularly the lower lips, eyelids, and nose. The penis, labia, and other parts of the body are not infrequently affected.

Etiology.—Obscure. Occurs after middle life, and more frequently in men than in women.

Pathology.—The process consists of an abnormal downgrowth into the corium of the interpapillary projections of the rete mucosum, a proliferation of the rete cells, their isolation in the corium in the form of nests, the occurrence of "pearly bodies," and certain secondary inflammatory changes.

Diagnosis.—Epithelioma may be confounded with warts, the ulcerating syphiloderm, and lupus vulgaris.

The age of the patient, the occurrence of ulceration, the general appearance of the growth, the history, and the course will usually enable one to distinguish an epithelioma from a wart.

From syphiloderm, epithelioma may be differentiated as follows:

EPITHELIOMA.	TUBERCULAR ULCERATING SYPHILIDE.
1. Occurs *in late life.*	1. Occurs in middle and early life.

2. No history or concomitant signs.	2. History and concomitant signs of syphilis.
3. Evolution slow.	3. Evolution rapid.
4. Ulceration single.	4. Ulceration usually multiple.
5. Edges of ulcer hard and indurated. Discharge scanty, bloody and stringy.	5. Edges of ulcer not indurated. Discharge abundant, yellowish, and creamy.
6. Lancinating pain.	6. No pain.
7. Yields only to destruction.	7. Heals under the use of iodids and mercury.

The differential diagnosis from lupus vulgaris will be found under that disease.

Prognosis.—The superficial form resulting from seborrheic degeneration may be permanently cured by early and thorough destruction. In the other forms the prognosis is more grave, and will depend upon the age of the patient, the extent of the disease, the rapidity of the process, etc.

Treatment.—The treatment consists of thorough destruction of the diseased tissues. One of the best methods of accomplishing this end is erasion by means of the dermal curet, followed by cauterization of the part; or, if in a convenient situation, the growth may be excised. In some cases such caustics as arsenic, caustic potash, or pyrogallic acid may be employed.

PAGET'S DISEASE OF THE NIPPLE.

Synonym.—Malignant papillary dermatitis.

Definition.—Paget's disease is a malignant affection of the nipple and areola, characterized at first by an eczematoid process, which later terminates in carcinoma of the skin and mammary gland.

Symptoms.—The disease attacks women usually between the ages of forty and sixty. But one breast is involved.

A typical case exhibits a sharply-defined, red, raw, granulating surface, copiously exuding a clear, viscid secretion. The infiltration present has been aptly likened to the feel of a

button or large coin through a handkerchief. Burning, itching, and pain are usually severe. Cancerous involvement of the nipple and breast is the almost invariable outcome.

Pathology.—Under the microscope there is visible a proliferation of cells of the mucous layer, prolongation of the

FIG. 99.—ROUND-CELLED SARCOMA.

FIG. 100.—SPINDLE-CELLED SARCOMA.

FIG. 101.—MELANOTIC SARCOMA.

FIG. 102.—GIANT-CELLED SARCOMA.

rete pegs, formation of epithelial nests, dilatation of papillary blood-vessels, perivascular cell infiltration, and loss of the superficial epiderm.

A sharp line of demarcation separates the diseased tissue from the healthy border.

Diagnosis.—Paget's disease may be distinguished from eczema by the more advanced age of the patient, the sharp definition of the patch, the peculiar raw, granular appearance, the button-like infiltration, and the course of the disease.

Prognosis.—If early recognized and treated, cure may result.

Treatment.—If there is doubt as to the diagnosis, the part should be treated as an eczema. When the diagnosis is fully established, the best and safest treatment is ablation of the entire breast.

SARCOMA.

Derivation.—Σάρξ, flesh.

Definition.—Sarcoma is a malignant disease, characterized by variously sized, shaped, and colored tumors, occurring in the skin and subcutaneous tissues either as primary or secondary growths.

Symptoms.—The disease is characterized by pea- to hazelnut-sized or larger, discrete, pigmented or non-pigmented nodules or tumors. The non-pigmented tumors are smooth, firm, elastic, and reddish, violaceous, or brownish in color.

The multiple pigmented sarcoma (*melano-sarcoma*) begins as pinhead- to pea-sized, brownish, bluish, or blackish growths, occurring most frequently upon the dorsum and sole of the foot and upon the hands. The nodules exhibit a marked tendency to bleed.

Prognosis.—The prognosis is unfavorable, nearly all cases terminating fatally.

Treatment.—Highly unsatisfactory. Ablation of the tumors by the knife is followed, as a rule, by recurrence.

Hypodermic injections of Fowler's solution in the region of the growths have proven successful in several cases.

GRANULOMA FUNGOIDES.

Synonyms.—Mycosis fungoides; inflammatory fungoid neoplasm.

Definition.—A chronic, malignant, infectious disease, characterized primarily by an eruption of an urticarial, ecze-

matoid, or lichenoid appearance, and later by ulcerating fungoid tumors.

Symptoms.—In the early or "premycosic" stage the affection begins as an urticarial, erythematous, eczematous, or

FIG. 103.—MYCOSIS FUNGOIDES.—(*After Van Harlingen.*)

lichenoid eruption, accompanied by itching and burning. After a duration of some months or years this is followed by flat or slightly elevated plaques of a pinkish-red color.

In the second stage there appear pea- to fist-sized, reddish or violaceous, shining tumors, which may develop from the above-described plaques, or may spring up independently. They at times develop with remarkable rapidity, and spontaneously disappear just as quickly. More commonly they undergo abscess formation and ulceration, and present the appearance of a mushroom or fungoid growth.

FIG. 104.—HIGHLY MAGNIFIED PORTION OF A MYCOSIS FUNGOIDES TUMOR, SHOWING CELLS EMBEDDED IN A DELICATE FIBROUS STROMA.—(*After Crocker.*)

Pathology.—The microscopic appearances strongly resemble those of the round cell and lympho-sarcomata.

Prognosis.—The result is almost invariably fatal.

Treatment.—No treatment has been of any avail. In the relief of itching, quinin and antipyrin have been found of value.

CLASS VIII.—ANOMALIES OF SECRETION OF THE GLANDS.

HYPERIDROSIS.

Derivation.—Ὑπερ, in excess; ἱδρώς, sweat.

Synonyms.—Idrosis; hydrosis; ephidrosis; sudatoria; *polydrosis; excessive* sweating.

Definition.—Hyperidrosis is a functional disorder of the sweat-glands characterized by an excessive secretion of sweat.

The affection may be general or local.

Symptoms.—The hands, when affected, are cold and clammy. In severe cases the water drops from the palms, incapacitating the patient from all manual work. The feet,

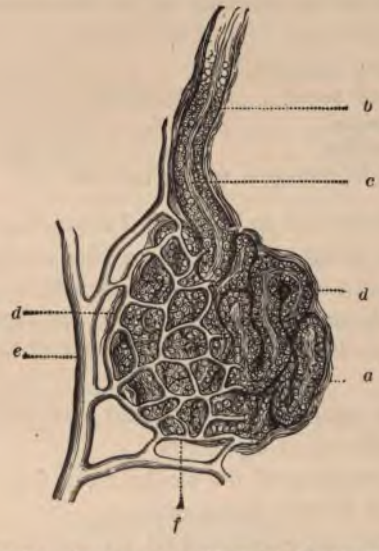

FIG. 105.—A NORMAL SWEAT-GLAND HIGHLY MAGNIFIED.—(*Neumann.*) *a.* Sweat-coil with secreting epithelial cells. *b.* Sweat-duct. *c.* Lumen of duct. *d, d.* Connective-tissue capsule. *e* and *f.* Arterial trunk and capillaries supplying the gland.

when affected, become tender, so that walking produces pain. The soles are reddened and the epidermis macerated.

Etiology.—General hyperidrosis results from faulty innervation. It may, however, be physiologic, as during violent muscular exertion. The local forms are probably due to *some disturbance* of the vasomotor apparatus.

Treatment.—In general hyperidrosis constitutional remedies are to be employed—belladonna or atropin, ergot, nux vomica, mineral acids, quinin, etc. Crocker speaks highly of sulphur, given in dram doses twice daily, for both general and local sweating. For the local forms the remedies are, for the greater part, to be applied to the affected regions. Upon the palms this condition is much more refractory to treatment than upon the soles. The following prescription will be found of great value in the treatment of sweating feet:

℞. Acidi salicylici, ... gr. xx
Acidi borici, ... ʒj
Lanolini,
Petrolati, ... āā ℥ss. M.
SIG.—To be rubbed in well at bedtime.

The feet ought not to be washed more than once a week. It is well also to strew boric acid in the stockings. Hebra's plan was to wrap up the feet in an ointment of ung. lithargyri (diachylon ointment), and continue the treatment for a fortnight. Crocker recommends the use of belladonna ointment.

All of these remedies will be found more efficient in sweating feet than in sweating hands.

To check sweating of the axillæ for a few hours apply a sponge soaked in very hot water.

Faradization and galvanization are sometimes of value in hyperidrosis.

BROMIDROSIS.

Derivation.—*Βρῶμος*, a stench.

Synonym.—Osmidrosis.

Definition.—Bromidrosis is a functional disorder of the sweat-glands characterized by sweat secretion of an offensive odor.

Symptoms.—The condition may be symptomatic, as in uremia, rheumatism, etc.

There is usually an excessive sweating, although the amount may be normal. The odor is often sufficient to unfit the sufferer for society.

Etiology.—Obscure. Usually occurs upon the feet of young persons.

Pathology.—The sweat is not offensive when secreted, but soon becomes so from the action of micro-organisms.

Treatment.—It is practically that of hyperidrosis.

ANIDROSIS.

Derivation.—*Ἀ*, privative, and *ἱδρώς*, sweat.

Synonym.—Decrease or absence of sweating.

Definition.—A disorder of the sweat-glands characterized by diminution or suppression of sweat.

Symptoms.—It may be symptomatic, as in diabetes, fevers, etc. It may also be due to faulty innervation. There may be but slight diminution of sweat secretion, or total absence.

Treatment.—In congenital cases nothing is of avail. In acquired cases, one may employ massage, electricity, vapor and alkaline baths, etc.

CHROMIDROSIS.

Derivation.—*Χρῶμα*, color, and *ἱδρώς*, sweat.

Definition.—A disorder of the sweat-glands characterized by colored sweat.

Symptoms.—There are two forms—idiopathic and accidental (color due to certain substances taken into the system). The color in the idiopathic form is usually black or sepia. The orbital region is usually affected.

Accidental Forms.—Green sweat is found frequently in copper-workers. Red sweat, which occurs often in the

axillæ, is due to the action of the bacterium prodigiosum, and is often associated with lepothrix.

Treatment.—The treatment is based upon broad general principles.

URIDROSIS.

Derivation.—*Οὖρον*, urine; *ἱδρώς*, sweat.

Synonym.—Sudor urinosus.

Definition.—A condition characterized by the excretion through the sweat-glands of constituents of the urine in considerable quantity.

Symptoms.—The sweat normally contains small quantities of urea. In suppression of the urine, as in Bright's disease, cholera, etc., urinary products are eliminated through the sweat-glands. There is a urinous odor to the skin, and sometimes a deposition of salts on the skin.

HEMATIDROSIS.

Derivation.—*Αἷμα*, blood; *ἱδρώς*, sweat.

Synonym.—Bloody sweat.

Definition.—A condition characterized by hemorrhage from the sweat-pores.

Symptoms.—Very rare. Occurs in young hysteric women. Has been observed on the face, ears, umbilicus, hands and feet.

PHOSPHORIDROSIS.

Derivation.—*Φωσφόρος*, phosphorus; *ἱδρώς*, sweat.

Definition.—A rare condition characterized by phosphorescent sweat. Has been observed after the ingestion of phosphorus and of fish, but is probably due to a species of photobacterium.

SUDAMEN.

Derivation.—*Sudor*, sweat.

Synonym.—Miliaria crystallina.

Definition.—An eruption characterized by the formation

of numerous superficial, pinhead, transparent vesicles, occurring during the course of febrile diseases.

Symptoms.—The vesicles are non-inflammatory. They have been aptly described as resembling "dew-drops." They are most abundant upon the trunk and neck, and disappear in the course of a few days.

Pathology.—The vesicles are due to a collection of sweat in the upper layers of the epidermis as a result of obstruction of the sweat-ducts.

Treatment.—The affection undergoes spontaneous involution.

MILIARIA.

Derivation.—*Milium,* millet.

Synonyms.—Prickly heat; lichen tropicus; red gum; strophulus.

Definition.—A mild inflammatory affection, caused by obstruction of the sweat-ducts, characterized by the occurrence of small papules and vesicles at their mouths.

Symptoms.—The affection comes on suddenly, after profuse perspiration. The lesions are discrete, never tending to coalesce. Itching is usually present. The trunk is the seat of predilection. In children it is apt to be complicated by furunculosis.

Pathology.—Obstruction of sweat-ducts, with surrounding inflammation.

Treatment.—Prophylactic. Children should be lightly clad in thin woolens, and kept in cool places. Constipation should be avoided. Sedative lotions and dusting-powders constitute the local treatment. The following is a useful combination:

℞. Acidi carbolici, ... ♏xxx
Acidi borici, ... ʒj
Zinci oxidi,
Pulv. calaminæ, ... āā ʒiss
Glycerini, ... fʒij
Spts. vini rect., ... fʒij
Aquæ, ... q. s. ad f℥vj. M.

Sig.—Sop on the skin *pro re nata.*

Or a dusting powder may be used:

℞. Magnes. carbonat.,
Acidi borici,
Pulv. amyli, ... āā ʒij. M.

An excellent method is to sop on a saturated solution of boric acid, and follow this with a dusting-powder. When the entire body is involved, bran, starch, or alkaline baths may be employed with good results.

HYDROCYSTOMA.

Derivation.—Ἱδρώς, sweat.

Definition.—A condition characterized by the formation upon the face of firm, discrete, pinhead- to split-pea-sized vesicles, due to obstruction of the sweat-ducts.

Symptoms.—The lesions are usually confined to the face, although they may appear on the neck also. The vesicles are tense, with clear contents (acid in reaction), and a purplish color upon the periphery. The condition improves or disappears in winter, but is almost sure to recur in hot weather. Washer-women are prone to it.

Pathology.—The vesicle are due to the obstruction of sweat-ducts in the corium. As a result, a cystic dilatation of the duct occurs.

Treatment.—Those affected should avoid occupations that promote perspiration. Residence in a cool climate is eminently desirable. The results of treatment are not very brilliant. Robinson advises friction with sapo mollis and water and puncturing the vesicles with a needle.

HIDRADENITIS SUPPURATIVA.

Definition.—An inflammatory disease of the sweat-glands characterized by deep-seated, shot-like nodules, which suppurate and produce scars.

Symptoms.—The axilla, nipple, anus, scrotum, and labia majora are the regions most commonly affected. In these parts the lesions may be single or multiple. Occasionally, the face, neck, and trunk may be the seat of an extensive eruption. The lesion begins as a deep, painless, bird-shot-like nodule, which in the course of one or two weeks grows to the size of a pea. The overlying skin becomes reddened, adherent, and somewhat painful on pressure. A few days later a yellowish center appears, the epidermis breaks down, and one or two drops of creamy pus exude. A pigmented patch or a depressed scar remains after the healing of the lesion.

Pathology.—The pathologic process is an acute suppurative inflammation of the sweat-glands and periglandular tissue, terminating in their destruction.

Prognosis.—The disease tends to spontaneous cure, though it may last for years.

Treatment.—This must be guided by the general condition of the patient. Such tonics as iron, strychnin, and quinin are frequently indicated. The nodules should be incised and antiseptic dressings applied.

SEBORRHEA.

Derivation.—*Sebum,* suet; *ῥέω*, to flow.

Synonyms.—Dandruff; pityriasis; ichthyosis sébacé; eczema seborrhœicum.

Definition.—A disorder of the fat-producing glands characterized by an increased and altered secretion of sebum, producing an oily or scaly condition upon the skin.

Symptoms.—There are two forms—*seborrhœa oleosa* and *seborrhœa sicca.*

Seborrhœa Oleosa.—This form manifests itself as an inordinate oiliness of the skin. The parts usually affected are the forehead, cheeks, and nose. The mouths of the follicles are dilated, and there is often an enlargement of the superficial blood-vessels. The face looks dirty and begrimed, owing to the adhesion to the skin of particles of dust.

Seborrhœa sicca (*dandruff*) manifests itself as an accumulation of yellow or grayish scales, occurring upon the scalp or non-hairy regions. When the face is involved, the eyebrows and beard are usually first affected.

Upon the scalp this condition is generally associated with falling of the hair.

The *vernix caseosa* is an intra-uterine seborrhea, physiologic in character. The *smegma præputii* is also a seborrhea; as a result of the decomposition of the secretion, balanitis sometimes develops.

Etiology.—The causation is obscure. The disease occurs most frequently at the age of puberty. It is more common in women than in men, and in dark-complexioned people than in blonds. It may be idiopathic, but is frequently met with in persons affected with tuberculosis, chlorosis, general debility, and gastro-intestinal disorders.

Diagnosis.—Oily seborrhea can scarcely be confounded with any other affection. Seborrhœa sicca is to be distinguished from psoriasis, eczema, erythematous lupus, and ringworm. These are all characterized by redness and more or less thickening.

Pathology.—There is an overaction of the sebaceous glands and sweat-glands, at times accompanied by a slight degree of inflammation. Some observers consider the affection as micro-organismal in character.

Prognosis.—Favorable. Long-standing cases affecting

arsenic,

rec-

Extra. cinchon. fluid. gtt. ℥i
Bals Peruv. gtt XV
Cantharid tinct gtt XXIV
Succ. citri m XV
Ung Pomat ʒ 155
Rub scalp 1-3 x day.

T. A. DONLON
PRESCRIPTION DRUGGIST
SUTTER AND FILLMORE STREETS
TELEPHONE WEST 249
OPEN ALL NIGHT SAN FRANCISCO

Hg Cl 2 gr I
Tr Canthar. dram II
Ac Salicylic dram I
Sft Vin Rect die quod ʒ IV

LANUGO

ng cells.
nf of se-

grain.
e treat-

ove the

crusts and scales, and then to use stimulating and astringent applications, with a view to favorably influencing the glandular secretions. Resorcin, sulphur, and salicylic acid are the three sovereign remedies.

To soften crusts upon the scalp:

℞. Acidi salicylici, ... gr. xx
Ol. olivæ, ... fʒiv.

This may be followed by the use of the *tincture of green soap* to remove the epithelial debris. One of the following preparations may then be employed:

℞. Resorcin, ... ʒij
Ol. ricini, ... fʒss
Spts. vini rect.,
Spts. myrciæ (bay rum), . . āā fʒiij. M.
Sig.—Shampoo head at night.

Upon nonhairy regions, or when there is but little hair upon the scalp, salves may be used:

℞. Sulph. præcip., ... gr. xx-xxx
Petrolati, ... ℥ss
Ol. bergamottæ, ... ♏xx.

Or—

℞. Acidi salicylici, ... gr. x
Petrolati, ... ℥ss.

Ammoniated mercury, calomel, carbolic acid, and other remedies are also employed, but the foregoing will be found to give the best results.

For oily seborrhea:

(*a*) Equal parts of alcohol and ether.

Or—

(*b*) Acidi borici, ... gr. xxx-ʒj
Spts. vini rect., ... fʒij.

Or—

(*c*) Acidi tannici, ... gr. xxx-ʒj
Spts. vini rect.,
Aquæ, ... āā fʒj.

ASTEATOSIS.

Derivation.—*'A* privative; *στέαρ*, fat.

Definition.—Asteatosis is a condition characterized by a diminution or suppression of the sebaceous secretion.

Symptoms.—The skin is harsh and dry and frequently desquamating.

Idiopathic cases are rare. The condition often accompanies psoriasis, leprosy, ichthyosis, prurigo, scleroderma, and lichen ruber.

Treatment.—Inunctions of fatty substances.

CLASS IX.—NEUROSES.

HYPERESTHESIA.

Hyperesthesia is a condition characterized by an increased sensibility of the skin. This may occur in various functional and organic nervous diseases, such as hysteria, leprosy, etc.

DERMATALGIA.

Synonyms.—Neuralgia of the skin; dermalgia; rheumatism of the skin.

Definition.—Dermatalgia is characterized by pain confined to the skin, not the result of structural change.

Symptoms.—The symptoms are entirely subjective. The surface of the skin is normal. The pain is spontaneous, but is increased by pressure, friction of clothing, etc.

Small, circumscribed areas, particularly hairy regions, are affected. The affection occurs most frequently in adult females.

Etiology.—Rheumatism is looked upon as causative in most cases. It may also occur in hysteria and chlorosis.

Treatment.—General treatment is to be directed to the cause. Locally, counterirritants and the galvanic current are of value.

ANESTHESIA.

Anesthesia is characterized by impairment or entire loss of cutaneous sensibility. It is usually circumscribed, and is observed in functional and organic nerve diseases. It is a characteristic feature of anesthetic leprosy.

PRURITUS.

Derivation.—*Prurire,* to itch.

Definition.—Pruritus is a functional cutaneous disease characterized by itching, without structural alteration of the skin.

Symptoms.—Itching is the sole symptom. It may partake of a tickling, pricking, crawling, or tingling character. The patient is invariably prompted to scratch and rub the affected part. As a result of long-continued scratching, excoriations, papules, and thickening of the skin may result. The itching is paroxysmal, and nearly always worse at night.

Pruritus may be general (*pruritus universalis*) or local (*pruritus localis*). The regions commonly attacked in the latter variety are the anus (*pruritus ani*), the vulva (*pruritus vulvæ*), and the scrotum (*pruritus scroti*).

Pruritus is far more common in advanced life (*pruritus senilis*).

The form of pruritus occurring during the cold months of the year is designated *pruritus hiemalis.*

Etiology.—Generalized pruritus may be caused by Bright's disease, diabetes, hepatic affections, digestive and intestinal disturbances, nervous disorders, pregnancy, uterine and ovarian disease, ingestion of certain medicaments, etc.

Pruritus vulvæ is not infrequently produced by irritating vaginal discharges. It is a common symptom in diabetes. Pruritus ani may be caused by hemorrhoids, fissures, seatworms, etc., or may be due to gout or to some other constitutional condition.

Diagnosis.—Pediculosis corporis may usually be differentiated from pruritus by the localization of the scratch marks and the presence of the parasites in the garments.

Prognosis.—Guarded. Depends upon the nature and removability of the cause.

Treatment.—The cause must be assiduously investigated and treated.

Internal Treatment.—Diet and hygiene should be carefully regulated. The various visceral diseases must receive appropriate treatment. In obscure cases the mineral acids, quinin, strychnin, atropin, gelsemium, pilocarpin, and arsenic may be variously tested.

Local treatment is designed to give merely temporary relief from the distressing itching.

The following are some of the best antipruritic lotions:

(1)	Acidi carbolici, ...	ʒj-ʒiij
	Glycerini, ...	ʒij
	Spts. vini rect., ...	f℥iv
	Aquæ, ... q. s. ad	Oj.
(2)	Liq. carbonis detergens, ...	℥ss-℥ij
	Aquæ, ...	Oj.
(3)	Thymol, ...	ʒss-ʒij
	Liq. potassæ, ...	ʒij
	Glycerini, ...	℥ss
	Aquæ, ...	Oj.

For pruritus vulvæ one may use: (1) Saturated solution of boric acid; (2) compound tincture of benzoin (painted on), (3) vaginal injections of alum, zinc sulphate, etc.

For pruritus ani:

(1)	Acidi carbolici, ...	gr. x-xx
	Hydrarg. chlor. mit., ...	gr. xx-xxx
	Ung. zinci oxidi, ...	℥j.
(2)	Hydrarg. chlor. corrosiv., . . .	gr. viij-xvj
	Aquæ, ...	f℥viij.
(3)	Acidi carbolici, ...	gr. x-xxv
	Picis liquidæ, ...	f℥j-f℥ij
	Lanolin, ...	℥j.

INDEX.

A.

PAGE

ACARUS folliculorum, . . 184
scabiei, ... 156
Achorion Schönleinii, . . 146
Acne, ... 86
artificialis, ... 87
cachecticorum, . . . 88
frontalis, ... 97
hypertrophica, . . . 95
indurata, ... 87
-keloid, ... 98
necrotica, ... 97
papulosa, ... 87
punctata, ... 87
pustulosa, ... 87
rosacea, ... 93
varioliformis, . . . 97
vulgaris, ... 86
Acquired piebald skin, . . 197
Acrodynia, ... 36
Actinomycosis, ... 151
Acute circumscribed edema, 41
Addison's disease, . . . 169
Ainhum, ... 130
Albinism, ... 196
Alopecia, ... 207
areata, ... 209
circumscripta, . . . 209
congenital, ... 207
premature, ... 208
senile, ... 207
Anatomic tubercle, . . . 239
Anemia of the skin, . . . 26
Anesthesia, ... 280
Anesthetic leprosy, . . . 258
Angioma, ... 223
cavernosum, ... 223
pigmentosum et atrophicum, ... 201

PAGE

Angioma simplex, ... 223
Angiomyoma, ... 223
Angioneurotic edema, . . 41
Anidrosis, ... 271
Anthrax, ... 128
benigna, ... 126
Antipyrin, eruption from, . 121
Area Celsi, ... 209
Argyria, ... 170
Arsenic, ... 107, 235
eruption from, . . . 121
Asteatosis, ... 279
Atheroma, ... 185
Atrophia cutis, ... 199
pilorum propria, . . . 215
senilis, ... 199
unguis, ... 216
Atrophic lines and spots, . 201
Atrophoderma neuriticum, . 200
pigmentosum, . . . 201
Atrophy of the hair, . . . 215
of the nails, ... 216
of the skin, ... 199

B.

BACILLUS lepræ, ... 259
Baldness, ... 207
Barbadoes leg, ... 192
Barbers' itch, ... 139
Bed-bug, ... 164
Belladonna, eruption from, . 121
Blackheads, ... 182
Blastomycetic dermatitis, . 237
Blebs, ... 20
Blood-vessels of skin, . . 14
Bloody sweat, ... 272

PAGE

Boil, ... 124
Bot-fly, ... 163
Bromidrosis, ... 270
Bromids, eruption from, . . 121
Bulb-corpuscle, ... 14
Bullæ, ... 20
Burn, ... 118

C.

CALLOSITAS, ... 171
Callus, ... 171
Calvities, ... 207
Canities, ... 206
prematura, ... 206
senilis, ... 206
Carbuncle, ... 126
Carbunculus, ... 126
Carcinoma epitheliale, . . 261
Chafing, ... 28
Chapping, ... 43
Charbon, ... 128
Cheiro-pompholyx, . . . 73
Cheloid, ... 216
Chilblain 118
Chloasma, ... 169
uterinum, ... 169
Chloral, eruption from, . . 121
Chromidrosis, ... 271
Chromophytosis, ... 142
Chrysarobin, ... 114
Cimex lectularius, . . . 164
Cingulum, ... 77
Circumscribed scleroderma, . 205
Classification, ... 21, 25
Clavus, ... 172
Clear layer, ... 9
Coccogenic sycosis, . . . 98
Comedo, ... 182
Compound zinc sulphid lotion, 92
Condyloma, flat, ... 244
pointed, ... 179
Copaiba, eruption from, . . 121
Corium, ... 12
Corn, ... 172
Cornu cutaneum, ... 173
Corpuscles of Krause, . . 14
of Meissner, ... 14

PAGE

Crab-louse, ... 151
Crusts, ... 20
Cubebs, eruptions from, . . 121
Culex, ... 164
Curetting, ... 236
Cutaneous calculi, . . . 185
horn, ... 173
Cutis pendula, ... 194
vera, ... 12
Cysticercus cellulosæ, . . 162
Cystis sebacea, ... 185

D.

DANDRUFF, ... 208, 276
Darier's disease, ... 187
Defluvium capillorum, . . 208
Demodex folliculorum, . . 184
Depilatories, ... 190
Derma, ... 12
Dermalgia, ... 279
Dermatalgia, ... 279
Dermatitis, ... 117
ambustionis, ... 118
blastomycetica, ... 237
calorica, ... 118
congelationis, ... 118
contusiformis, ... 33
exfoliativa, ... 112
gangrænosa, ... 122
gangrænosum infantum, 122
herpetiformis, ... 67
medicamentosa, ... 120
papillaris capillitii, . . 98
seborrhœica, ... 58
traumatica, ... 118
venenata, ... 118
Dermatolysis, ... 194
Dermatomyoma, ... 222
Dermatosclerosis, ... 203
Dermatosyphilis, ... 240
Dermographism, ... 38
Diabetic gangrene, ... 123
Diet in eczema, ... 51
Digitalis, eruption from, . . 121
Dissection wounds, ... 129
Disseminated ringworm, . 136
Dracunculosis, ... 162

PAGE

Drug eruptions, ... 120
Duhring's disease 67
Dysidrosis, ... 73

E.

ECTHYMA, ... 66
Eczema, ... 41
erythematosum, ... 43
fissum, ... 46
impetiginosum, ... 45
madidans, ... 45
marginatum, ... 131
papillomatosum, ... 46
papulosum, ... 43
pustulosum, ... 45
rubrum, ... 45
sclerosum, ... 46
seborrhœicum, ... 58
squamosum, ... 45
verrucosum, ... 46
vesiculosum, ... 43
Elastic skin, ... 194
Electrolysis, ... 190
Elephantiasis, ... 192
arabum, ... 192
græcorum, ... 256
Elephant leg, ... 192
Embryonic development of skin, ... 9
Ephelides, ... 167
Ephidrosis, ... 268
Epidermis, ... 9
Epithelial cancer, ... 261
Epithelioma, ... 261
deep-seated, ... 262
papillary, ... 263
superficial, ... 261
Equinia, ... 127
Erysipelas, ... 115
ambulans, ... 116
chronicum, ... 117
migrans, ... 116
Erysipeloid, ... 117
Erythema, ... 27
annulare, ... 29
bullosum, ... 31
circinatum, ... 29

PAGE

Erythema, epidemic, ... 36
exsudativum, ... 29
multiforme, ... 29
figuratum, ... 30
gyratum, ... 30
hyperæmicum, ... 27
induratum, ... 34
intertrigo, ... 28
iris, ... 30
migrans, ... 117
multiforme, ... 29
nodosum, ... 33
papulosum, ... 30
scarlatinoides, ... 32
simplex, ... 27
vesiculosum, ... 31
Erythrasma, ... 151
Excessive sweating, ... 268
Excoriations, ... 21

F.

FARCY, ... 127
Favus, ... 145
Feigned eruptions, ... 124
Fibroma, ... 218
molluscum, ... 218
pendulum, ... 194
Fibromyoma, ... 223
Filaria medinensis, ... 162
sanguinis hominis, . . . 192
Fish-skin disease, ... 175
Fissures, ... 21
Flat condyloma, ... 244
epithelioma, ... 261
Flea, ... 164
Flesh-worms, ... 182
Folliculitis barbæ, ... 98
Fragilitas crinium, ... 215
Frambesia, ... 260
Freckles, ... 167
Frost-bite, ... 118
Fumigations of mercury, . 254
Fungus foot of India, . . 153
Furuncle, ... 124
Furunculosis, ... 124
Furunculus, ... 124A

G.

PAGE
GAD-FLY, ... 163
Gangrene, ... 122
General exfoliative dermatitis, ... 112
idiopathic atrophy, . . 200
Giant urticaria, ... 38
Glanders, ... 127
Glands, sebaceous, ... 15
sweat, ... 15
Glossy skin, ... 200
Glyco-gelatine dressing, . . 57
Gnat, ... 164
Granular layer, ... 11
Granuloma fungoides, . . 266
Grayness of the hair, . . 206
Grutum, ... 185
Guinea worm, ... 162
Gumma, ... 249
Gummy tumor, ... 249

H.

HAIR, ... 17
Hairiness, ... 188
Harvest bug, ... 163
Hematidrosis, ... 272
Hereditary syphilis, . . . 251
Herpes circinatus, . . . 130
facialis, ... 76
febrilis, ... 76
gestationis, ... 67
iris, ... 30
labialis, ... 76
præputialis, ... 76
progenitalis, ... 76
simplex, ... 75
tonsurans, ... 135
maculosus, . . . 114
zoster, ... 77
Hide-bound disease, . . . 203
Hidradenitis suppurativa, . 275
Hidrocystoma, ... 274
Hirsuties, ... 188
Hives, ... 36
Horny layer of the skin, . . 9
Hydron, ... 67
Hydrosis, ... 268
Hyperemia, ... 26
PAGE
Hyperesthesia, ... 279
Hyperidrosis, ... 268
Hypertrichosis, ... 188
Hypertrophic papule, . . 245
Hypertrophy of the hair, . 188
of the nail, ... 195

I.

ICHTHYOSIS, ... 175
hystrix, ... 175
sébacé, ... 275
simplex, ... 175
Idrosis, ... 268
Impetigo, ... 60
contagiosa, ... 60
herpetiformis, . . . 65
simplex, ... 63
Inflammatory fungoid neoplasm, ... 266
Intravenous injections of mercury, ... 254
Inunctions of mercury, . . 254
Iodids, ... 121
eruption from, . . . 121
Itch, ... 153
Ivy poison, ... 118
Ixodes, ... 163

J.

JIGGER, ... 164

K.

KAPOSI'S disease, ... 201
Keloid, ... 216
of Addison, ... 205
of Alibert, ... 216
Keratosis follicularis, . . 187
pilaris, ... 186
Kerion, ... 137
Kummerfeld's solution, . . 92

L.

PAGE
LAND scurvy, ... 166
Lassar's paste, ... 56
Lax skin, ... 194
Lentigo, ... 167
Leontiasis, ... 257
Lepra, ... 256
anæsthetica, ... 258
maculosa, ... 256
mutilans, ... 259
tuberculosa, ... 2.
Leprosy, ... 256
Leptus autumnalis, . . . 163
Leukoderma, ... 197
Lichen, ... 81
pilaris, ... 186
planus, ... 81
ruber, ... 81
acuminatus, . . 81
planus, ... 81
scrofulosus, ... 84
tropicus, ... 273
urticatus, ... 38
Lineæ albicantes, ... 201
Liomyoma cutis, ... 222
Liquor carbonis detergens, . 55
picis alkalinus, . . . 57
Local asphyxia, ... 122
Lousiness, ... 158
Lues, ... 240
Lump-jaw, ... 151
Lupoid sycosis, ... 102
Lupus erythematodes, . . 226
erythematosus, . . . 226
exedens, ... 230
exfoliativus, ... 232
exulcerans, ... 230
hypertrophicus, . . . 232
papillomatosus, . . . 232
vulgaris, ... 230
Lymphangiectodes, . . . 224
Lymphangioma, ... 224
circumscriptum, . . . 224
tuberosum multiplex, . 225
Lymphangiomyoma, . . . 223
Lymph-vessels of skin, . . 14

M.

MACULES, ... 20
Madura foot, ... 153
PAGE
Malignant papillary dermatitis, ... 264
pustule, ... 128
Melanoderma, ... 169
Melanosarcoma, ... 266
Mercurial inunctions, . 254-256
Mercury, eruption from, . . 121
Microsporon Audouini, . . 137
furfur, ... 144
minutissimum, . . . 151
Miliaria, ... 273
crystallina 272
Miliary papular syphilide, . 242
pustular syphilide, . . 246
Milium, ... 185
Moist papule, ... 244
Mole, ... 171
Molluscum contagiosum, . . 180
epitheliale, ... 180
fibrosum, ... 218
pendulum, ... 218
Morbus maculosus Werlhofii, ... 166
Morphea, ... 205
Mosquito, ... 164
Mowers' mite, ... 163
Mucous layer of the skin, . 11
patch, ... 244
Muscles of the skin, . . 14, 15
Mycetoma, ... 153
Mycosis fungoides, . . . 266
Myoma, ... 222
cutis, ... 222
telangiectodes, . . . 223

N.

NÆVUS araneus, ... 224
flammeus, ... 223
lipomatodes, ... 171
pigmentosus, ... 170
pilosus, ... 171
sanguineus, ... 223
spilus, ... 171
tuberosus, ... 223
vasculosus, ... 223
verrucosus, ... 171
Nail, ... 19
atrophy of, ... 216
hypertrophy of, ... 195

PAGE

Nerve corpuscles, ... 14
tumor, ... 220
Nerves of the skin, ... 14
Nettle-rash, ... 36
Neuralgia of the skin, . . 279
Neuroma, ... 220

O.

ŒSTRUS, ... 163
Onychatrophia, ... 216
Onychauxis, ... 195
Onychogryphosis, ... 196
Onychomycosis, ... 134
Opium, eruptions from, . . 121
Osmidrosis, ... 270
Ova of pediculi, ... 162

P.

PACHYDERMIA, ... 192
Pacinian corpuscle, ... 15
Paget's disease, ... 264
Panniculus adiposus, . . . 14
Papillary layer of the skin, 12
Papules, ... 20
Parasitic sycosis, ... 139
Pediculosis, ... 158
capitis, ... 158
corporis, ... 160
pubis, ... 161
Peliosis rheumatica, ... 165
Pellagra, ... 35
Pemphigus, ... 70
foliaceus, ... 71
syphiliticus, ... 251
vegetans, ... 72
vulgaris, ... 71
Peruvian wart, ... 260
Phosphoridrosis, ... 272
Phthiriasis, ... 158
Pian, ... 260
Pigmentary mole, ... 170
Pigmentationes, ... 21

PAGE

Pityriasis, ... 275
maculata et circinata, . 114
pilaris, ... 186
rosea, ... 114
rubra, ... 110
follicularis, . . . 110
pilaris, ... 110
versicolor, ... 142
Podelcoma, ... 153
Polydrosis, ... 268
Pomphi, ... 20
Pompholyx, ... 73
Portwine mark, ... 224
Postmortem pustule, . . . 129
wart, ... 239
Prickly heat, ... 273
Prurigo, ... 84
Pruritus, ... 280
ani, ... 280
hiemalis, ... 280
localis, ... 280
scroti, ... 280
senilis, ... 280
universalis, ... 280
vulvæ, ... 280
Psoriasis, ... 102
annulata, ... 105
circinata, ... 105
diffusa, ... 105
guttata, ... 105
gyrata, ... 105
nummularis, ... 105
punctata, ... 105
Psorospermosis, ... 187
Pulex irritans, ... 164
penetrans, ... 164
Purpura, ... 165
hemorrhagica, ... 166
rheumatica, ... 165
simplex, ... 165
Pustula maligna, ... 128
Pustules, ... 20
Pyrogallic acid, ... 108, 125

Q.

QUINCKE'S disease, ... 41
Quinin, eruptions from, . . 121

R.

PAGE
Ray fungus, ... 153
Raynaud's disease, ... 122
Red gum, ... 273
Rete Malpighii, ... 11
Reticular layer of corium, . 12
Rhagades, ... 21
Rheumatism of the skin, . 279
Rhinophyma, ... 95
Rhinoscleroma, ... 225
Rhus toxicodendron, ... 118
venenata, ... 118
Ringworm, ... 130
of the beard, ... 139
of the body, ... 130
of the nail, ... 134
of the scalp. 135
Rodent ulcer, ... 261
Rosacea, ... 224
Roseola, ... 241
Rupia, ... 248

S.

Salicylic acid, eruption from, ... 122
Salt rheum, ... 41
Sand-flea, ... 164
Sarcoma, ... 266
Sarcoptes scabiei. 155
Scabies, ... 153
Scales, ... 20
Scarification, ... 236
Scars, ... 21
Sclerema adultorum, ... 203
neonatorum, ... 202
of the new-born, . . . 202
Scleroderma, ... 203
neonatorum. 202
Scrofuloderma, ... 237
Sebaceou cyst, ... 185
glands, ... 15
Seborrhea, ... 275
congestiva. 226
corporis, ... 58
oleosa, ... 276
sicca, ... 276
Senile atrophy, ... 199
Shingles, ... 77
Smegma præputii. 276
Snuffles, ... 253
Soft corn, ... 172
Sphaceloderma, ... 122
Spider nevus, ... 224
Spontaneous gangrene, . . 122
Squamæ, ... 20
Stains, ... 21
St. Anthony's fire, ... 115
Steatoma, ... 185
Stratum corneum, ... 9
granulosum, ... 11
lucidum, ... 9
mucosum, ... 11
subcutaneum, ... 13
Striæ et maculæ atrophicæ, 201
Strophulus, ... 273
albidus, ... 185
Subcutaneous tissue, ... 13
Sudamen, ... 272
Sudatoria, ... 268
Sudor urinosus, ... 272
Sulphur, ... 91, 96, 101
Superfluous hair. 188
Sweat glands, ... 15
Sycosis, ... 98
non-parasitica, ... 98
parasitica, ... 139
vulgaris, ... 98
Symmetric gangrene, ... 122
Syphilis cutanea, ... 240
hereditary, ... 251
Syphiloderm, ... 240
acneiform, ... 247
bullous, ... 252
ecthymaform, ... 248
erythematous, ... 241
gummatous, ... 249
impetigoform, ... 247
large acuminated pustular, ... 247
flat pustular, . . . 248
papular . . . 243
lenticular papular, . . . 243
macular, ... 241
miliary papular, ... 242
pustular, ... 246
palmar, ... 245
papular, ... 242
papulo-squamous, . . . 244
plantar, ... 245
pustular, ... 247

PAGE

Syphiloderm, pustulo-crustaceous, ... 247
serpiginous tubercular, . 248
small acuminated pustular, ... 245
flat pustular, . . 247
papular, ... 242
squamous, ... 244
tubercular, ... 248
varicelliform, ... 245
varioliform, ... 247
vesicular, ... 245
Syphiloderma, ... 240
Syphiloma, ... 249

T.

TACTILE corpuscle, ... 14
Tar acne, ... 87
Telangiectasis, ... 224
Tetter, ... 41
Tincture of mineral tar, . . 55
Tinea circinata, ... 130
favosa, ... 145
epidermidis, . . . 146
unguium, ... 146
kerion, ... 137
sycosis, ... 139
tonsurans, ... 135
tricophytina, ... 130
barbæ, ... 139
capitis, ... 135
corporis, ... 130
cruris, ... 131
unguium, ... 134
versicolor, ... 142
Touch corpuscle, ... 14
Trichorrhexis nodosa, . . . 215
Tubercles, ... 20
Tubercular leprosy, ... 256
Tuberculosis cutis orificialis, 238
of the skin, ... 229, 238
verrucosa cutis, ... 239
Tumors, ... 20
Tylosis, ... 171

U.

ULCERS, ... 21
Ulerythema sycosiforme, . 102
Uridrosis, ... 272
Urticaria, ... 36
bullosa, ... 38
factitia, ... 38
gigans, ... 38
hemorrhagica, ... 38
papulosa, ... 38
pigmentosa, ... 40
tuberosa, ... 38

V.

VARICELLA gangrenosa, . . . 122
Vegetating papule, ... 245
Venereal warts, ... 179
Vernix caseosa, ... 276
Verruca, ... 178
acuminata, ... 179
digitata, ... 178
filiformis, ... 178
necrogenica, ... 239
plana, ... 178
senilis, ... 178
vulgaris, ... 178
Vesicles, ... 20
Vitiligo, ... 197
Vitiligoidea, ... 220
Vleminckx's solution, ... 97

W.

WARTS, ... 178
Wen, ... 185
Wheals, ... 20
Whitening of the hair, . . 206
Wood-tick, ... 163

X.

XANTHELASMA, ... 220
Xanthelasmoidea, ... 40

PAGE
Xanthoma, ... 220
diabeticorum, . . . 222
multiplex, ... 222
planum, ... 221
tuberosum, ... 221
Xeroderma, ... 175
pigmentosum, . . . 201

Y.

PAGE
YAWS, ... 260

Z.

ZONA, ... 77
Zoster, ... 77

Zinci Oxidi
Glycerii Puri
Vaseline
Sandie oa

MEDICAL BOOKS

Note Subject Index, Page 6

There have been sold more than
145,000 copies of Gould's Dictionaries
See Pages 12 and 13

P. BLAKISTON'S SON & COMPANY
PUBLISHERS OF MEDICAL AND SCIENTIFIC BOOKS
1012 WALNUT STREET, PHILADELPHIA

Montgomery's Gynecology

New Edition—Just Ready

A modern comprehensive Text-Book. By EDWARD E. MONTGOMERY, M.D., Professor of Gynecology in Jefferson Medical College, Philadelphia; Gynecologist to the Jefferson and St. Joseph's Hospitals, etc. Second Edition, Revised and Enlarged. 570 Illustrations, many of which are from original sources. Octavo. Cloth, $5.00; Leather, $6.00

*** This is a systematic modern treatise on Diseases of Women. The author's aim has been to produce a book that will be thorough and practical in every particular. The illustrations, nearly all of which are from original sources, have for the most part been drawn by special artists who, for a number of months, devoted their sole attention to this work. The present edition has been thoroughly revised.

"The book is one that can be recommended to the **student**, to the **general practitioner**—who must sometimes be a gynecologist to a certain extent whether he will or not—and to the **specialist**, as an **ideal and in every way complete work on the gynecology of to-day—a practical work for practical workers.**"—*The Journal of the American Medical Association.*

Byford's Gynecology

Third Revised Edition

A MANUAL FOR STUDENTS AND PHYSICIANS

By HENRY T. BYFORD, M.D., Professor of Gynecology and Clinical Gynecology in the College of Physicians and Surgeons of Chicago; Professor of Clinical Gynecology, Women's Medical School of Northwestern University, and in Post-Graduate Medical School, etc. Third Edition, Enlarged. 363 Illustrations, many of which are from original drawings and several of which are Colored. 12mo.

Cloth, $3.00

"**As a book to help the student** to quickly review what ought to be gotten up, so as to be prepared for the early examination, it is of great service. Such a book would also make a most excellent text-book for the college class room."—*Virginia Medical Semi-Monthly*, Richmond.

By JAMES TYSON, M. D.,

Professor of Medicine, University of Pennsylvania, Physician to the Philadelphia Hospital, etc.

The Practice of Medicine. Third Edition.

A Text-Book for Physicians and Students, with Special Reference to Diagnosis and Treatment. With Colored Plates and many other Illustrations. Third Edition, Revised and Enlarged. 124 Illustrations. 8vo.

Cloth, $5.50; Leather, $6.50; Half Russia, $7.50

*** This edition has been entirely reset from new type. The author has revised it carefully and thoroughly, and added much new material and new illustrations.

"We are firmly convinced that at the present time Dr. Tyson's book on Practice can be most heartily commended to both the practitioner and student as a safe, reliable, and thoroughly up-to-date guide in the practice of medicine."—*The Therapeutic Gazette.*

"The clinical descriptions are clear and full, and the methods of treatment described are those generally recognized as being the most modern and satisfactory."—*The London Lancet.*

Guide to the Examination of Urine. Tenth Edition.

For the Use of Physicians and Students. With Colored Plate and Numerous Illustrations Engraved on Wood. Tenth Edition, Revised, Enlarged, and in many parts entirely rewritten. Cloth, $1.50

*** *A French translation of this book has been published in Paris.*

"The book is probably more widely and generally known and appreciated than any of its similars in subject and scope."—*New York Medical Journal.*

"The book is a reliable one, and should find a place in the library of every practitioner and student of medicine."—*Boston Medical and Surgical Journal.*

Handbook of Physical Diagnosis. Fourth Edition.

Revised and Enlarged. With two Colored Plates and 55 other Illustrations. 298 pages. 12mo. Cloth, $1.50

"Like everything else emanating from this distinguished author this little book is replete with practical information from beginning to end."—*The Chicago Medical Recorder.*

"The author approaches his subject from a practical point of view and the little work will prove a good friend to the student."—*The American Journal of the Medical Sciences.*

NEW THIRD EDITION—NOW READY

MORRIS' ANATOMY

Rewritten—Revised—Improved

WITH MANY NEW ILLUSTRATIONS

Out of 102 of the leading medical schools 60 recommend "Morris." It contains many features of special advantage to students. It is modern, up-to-date in every respect. It has been carefully revised, the articles on Osteology and Nervous System having been rewritten. **Each copy contains the colored illustrations and a Thumb Index.**

Octavo. With 846 Illustrations, of which 267 are printed in colors.

CLOTH, $6.00; LEATHER, $7.00

"The ever-growing popularity of the book with teachers and students is an index of its value, and it may safely be recommended to all interested."—From *The Medical Record*, New York.

"Of all the text-books of moderate size on human anatomy in the English language, Morris is undoubtedly the most up-to-date and accurate."—From *The Philadelphia Medical Journal*.

McMurrich—Embryology

THE DEVELOPMENT OF THE HUMAN BODY

With 270 Illustrations

A Text-Book for Medical Students. By J. PLAYFAIR McMURRICH, Professor of Anatomy, Medical Department, University of Michigan. 527 pages. Cloth, $3.00

NINTH EDITION

POTTER'S MATERIA MEDICA, PHARMACY, AND THERAPEUTICS

An Exhaustive Handbook

Including the Action of Medicines, Special Therapeutics of Disease, Official and Practical Pharmacy, and Minute Directions for Prescription Writing, etc. Including over 650 Prescriptions and Formulæ. By SAMUEL O. L. POTTER, M.A., M.D., M.R.C.P. (Lond.), formerly Professor of the Principles and Practice of Medicine, Cooper Medical College, San Francisco; Major and Brigade Surgeon, U. S. Vol. Ninth Edition, Revised and Enlarged. 8vo.

With Thumb Index in each copy.

Cloth, $5.00; Leather, $6.00

*** This is the most complete and trustworthy book for the use of students and physicians. Students who purchase it will find it to contain a vast deal of information not in the usual text-books arranged in the most practical manner for facilitating study and reference. It cannot be surpassed as a physician's working book.

WHITE AND WILCOX. Materia Medica, Pharmacy, Pharmacology, and Therapeutics. Fifth Edition.

A Handbook for Students. By W. HALE WHITE, M.D., F.R.C.P., etc., Physician to, and Lecturer on Materia Medica and Therapeutics at, Guy's Hospital, etc. Fifth American Edition, Revised by REYNOLD W. WILCOX, M A, M.D., LL.D., Professor of Clinical Medicine and Therapeutics at the New York Post-Graduate Medical School and Hospital; Visiting Physician, St. Mark's Hospital; Assistant Visiting Physician, Bellevue Hospital. 12mo.

Cloth, $3.00; Leather, $3.50

SUBJECT INDEX.

Gould's Medical Dictionaries, - Pages 12, 13
Morris' Anatomy, New Edition, - - Page 4
Compends for Students, - - - - Page 27

SUBJECT.	PAGE
Alimentary Canal (see Surgery)	24
Anatomy	7
Anesthetics	18, 19
Autopsies (see Pathology)	20
Bacteriology	8
Bandaging (see Surgery)	24
Blood, Examination of	8
Brain	8
Chemistry. Physics	9
Children, Diseases of	11
Climatology	19
Clinical Charts	25
Compends	27
Consumption (see Lungs)	16
Cyclopedia of Medicine	13
Dentistry	11
Diabetes (see Urin. Organs)	25
Diagnosis	11
Diagrams (see Anatomy)	8
Dictionaries, Cyclopedias	12
Diet and Food	13
Disinfection	16
Dissectors	7
Ear	14
Electricity	14
Embryology	7
Emergencies	24
Eye	14
Fevers	15
Food	13
Formularies	21
Gynecology	15
Hay Fever	25
Heart	15
Histology	15
Hydrotherapy	19
Hygiene	16
Hypnotism	8
Insanity	8
Intestines	23
Latin, Medical (see Pharmacy)	21
Life Insurance	19
Lungs	16
Massage	17
Materia Medica	17
Mechanotherapy	17
Medical Jurisprudence	18
Mental Therapeutics	8
Microscopy	18
Milk	8, 10
Miscellaneous	18
Nervous Diseases	19
Nose	25
Nursing	20
Obstetrics	20
Ophthalmology	14
Organotherapy	18
Osteology (see Anatomy)	7
Pathology	20
Pharmacy	21
Physical Diagnosis	11
Physical Training	17
Physiology	22
Pneumotherapy	19
Poisons (see Toxicology)	18
Practice of Medicine	22
Prescription Books (Pharmacy)	21
Refraction (see Eye)	14
Rest	19
Sanitary Science	16
Serum-Therapy	17
Skin	23
Spectacles (see Eye)	14
Spine (see Nervous Diseases)	19
Stomach	23
Students' Compends	27
Surgery and Surgical Diseases	24
Technological Books	9
Temperature Charts	25
Therapeutics	17
Throat	25
Toxicology	18
Tumors (see Surgery)	24
U. S. Pharmacopœia	22
Urinary Organs	25
Urine	25
Venereal Diseases	26
Veterinary Medicine	26
Visiting Lists, Physicians'. (*Send for Special Circular.*)	
Water Analysis	16
Women, Diseases of	15

Self-Examination for Medical Students. 3500 Questions on Medical Subjects, with References to Standard Works in which the correct replies will be found. Together with Questions from State Examining Boards. 3d Ed. Paper Cover, 10 cts.

SPECIAL NOTE.—The prices given in this catalogue are net; no discount can be allowed retail purchasers under any consideration. This rule has been established in order that everyone will be treated alike, a general reduction in former prices having been made to meet previous retail discounts. Upon receipt of the advertised price any book will be forwarded by mail or express, all charges prepaid.

ANATOMY. EMBRYOLOGY.

MORRIS. Text-Book of Anatomy. Third Revised and Enlarged Edition. 846 Illustrations, 267 of which are printed in colors. *Thumb Index in Each Copy.* Cloth, $6.00; Leather, $7.00
"The ever-growing popularity of the book with teachers and students is an index of its value."—*Medical Record, New York.*

BROOMELL. Anatomy and Histology of the Human Mouth and Teeth. 2d Edition, Enlarged. 337 Illus. Cloth, $4.50

DAVISSON. Mammalian Anatomy. With Special Reference to the Cat. 110 Illustrations. *In Press.*

DEAVER. Surgical Anatomy. A Treatise on Anatomy in its Application to Medicine and Surgery. With 499 very handsome full-page Illustrations Engraved from Original Drawings made by special Artists from dissections prepared for the purpose. Three vols. By *Subscription only.*
Half Morocco or Sheep, $24.00; Half Russia, $27.00

GORDINIER. Anatomy of the Central Nervous System. With 271 Illustrations, many of which are original. Cloth, $6.00

HEATH. Practical Anatomy. 9th Edition. 321 Illus. $4.25

HOLDEN. Anatomy. A Manual of Dissections. Revised by A. HEWSON, M.D., Demonstrator of Anatomy, Jefferson Medical College, Philadelphia. 320 handsome Illustrations. 7th Ed. In two compact 12mo volumes. 850 pages. Large New Type.
Vol. I. Scalp—Face—Orbit—Neck—Throat—Thorax—Upper Extremity. $1.50
Vol. II. Abdomen—Perineum—Lower Extremity—Brain—Eye—Ear—Mammary Gland—Scrotum—Testes. $1.50

HOLDEN. Human Osteology. Comprising a Description of the Bones, with Colored Delineations of the Attachments of the Muscles. The General and Microscopical Structure of Bone and its Development. With Lithographic Plates and numerous Illustrations. 8th Edition. $5.25

HOLDEN. Landmarks, Medical and Surgical. 4th Ed. .75

HUGHES AND KEITH. Dissections. With 527 Colored Plates and other Illustrations. In three parts.
I, Upper and Lower Extremity. $3.00
II, Abdomen—Thorax. $3.00
III, Head—Neck—Central Nervous System. $3.00

LAZARUS-BARLOW. Pathological Anatomy. 21 Plates and 171 other Illustrations. *Just Ready.* $6.50

McMURRICH. Embryology. The Development of the Human Body. 276 Illustrations. $3.00

MARSHALL. Physiological Diagrams. Eleven Life-Size Colored Diagrams (each seven feet by three feet seven inches). Designed for Demonstration before the Class.

In Sheets, Unmounted, $40.00; Backed with Muslin and Mounted on Rollers, $60.00; Ditto, Spring Rollers, in handsome Walnut Wall Map Case, $100.00; Single Plates—Sheets, $5.00; Mounted, $7.50. Explanatory Key, .50. *Purchaser must pay freight charges.*

MINOT. Laboratory Text-Book of Embryology. 218 Illustrations. *Just Ready.* $4.50

POTTER. Compend of Anatomy, Including Visceral Anatomy. 7th Edition, Revised and Enlarged. 16 Plates and 138 other Illustrations. *Just Ready.* .80; Interleaved, $1.00

WILSON. Anatomy. 11th Edition. 429 Illus., 26 Plates. $5.00

YUTZY. Guide to the Dissection of the Human Body. Based on Morris' Anatomy. Paper Cover, .25

BACTERIOLOGY.

CONN. Agricultural Bacteriology. Including the Study of Bacteria as relating to Agriculture, Soil, Dairy and Food Products, Sewage, Domestic Animals, etc. Illustrated. $2.50

CONN. Bacteria in Milk and Its Products. Designed for Students of Dairying, Boards of Health, Bacteriologists, etc. Illustrated. $1.25

EMERY. Bacteriological Diagnosis. 2 Colored Plates and 32 other Illustrations. $1.50

HEWLETT. Manual of Bacteriology. 75 Illustrations. Second Edition, Revised and Enlarged. $4.00

SMITH. Laboratory Exercises in Bacteriology. A Handbook for Students. Illustrated. $1.50

WILLIAMS. Bacteriology. A Manual for Students. 88 Illustrations. 3d Edition, Revised. *Just Ready.* $1.50

BLOOD, Examination of.

DA COSTA. Clinical Hematology. A Practical Guide to the Examination of the Blood, with Reference to Diagnosis. Six Colored Plates and 48 other Illus. Cloth, $5.00; Sheep, $6.00

BRAIN AND INSANITY (see also Nervous Diseases.)

BLACKBURN. A Manual of Autopsies. Designed for the Use of Hospitals for the Insane and other Public Institutions. Ten full-page Plates and other Illustrations. $1.25

CHASE. General Paresis. Illustrated. $1.75

DERCUM. Mental Therapeutics, Rest, Suggestion. *See Cohen, Physiologic Therapeutics, page* 17.

GORDINIER. The Gross and Minute Anatomy of the Central Nervous System. With full-page and other Illus. $6.00

IRELAND. The Mental Affections of Children. 2d Ed. $4.00

LEWIS (BEVAN). Mental Diseases. A Text-Book having Special Reference to the Pathological Aspects of Insanity. 26 Lithographic Plates and other Illustrations. 2d Ed. $7.00

MANN. Manual of Psychological Medicine. $3.00

PERSHING. Diagnosis of Nervous and Mental Disease. Illustrated. $1.25

REGIS. Mental Medicine. Authorized Translation by H. M. BANNISTER, M.D. $2.00

STEARNS. Mental Diseases. With a Digest of Laws Relating to Care of Insane. Illustrated. Cloth, $2.75; Sheep, $3.25

TUKE. Dictionary of Psychological Medicine. Giving the Definition, Etymology, and Symptoms of the Terms used in Medical Psychology, with the Symptoms, Pathology, and Treatment of the Recognized Forms of Mental Disorders. Two volumes. $10.00

WOOD, H. C. Brain and Overwork. .40

CHEMISTRY AND TECHNOLOGY.

Special Catalogue of Chemical Books sent free upon application.

ALLEN. Commercial Organic Analysis. A Treatise on the Modes of Assaying the Various Organic Chemicals and Products Employed in the Arts, Manufactures, Medicine, etc., with Concise Methods for the Detection of Impurities, Adulterations, etc. 8vo.

Vol. I. Alcohols, Neutral Alcoholic Derivatives, etc., Ethers, Vegetable Acids, Starch, Sugars, etc. 3d Edition. $4.50

Vol. II, Part I. Fixed Oils and Fats, Glycerol, Explosives, etc. 3d Edition. $3.50

Vol. II, Part II. Hydrocarbons, Mineral Oils, Lubricants, Benzenes, Naphthalenes and Derivatives, Creosote, Phenols, etc. 3d Edition. $3.50

Vol. II, Part III. Terpenes, Essential Oils, Resins, Camphors, etc. 3d Edition. *Preparing.*

Vol. III, Part I. Tannins, Dyes, and Coloring Matters. 3d Edition, Enlarged and Rewritten. Illustrated. $4.50

Vol. III, Part II. The Amines, Hydrazines and Derivatives, Pyridine Bases. The Antipyretics, etc. Vegetable Alkaloids, Tea, Coffee, Cocoa, etc. 8vo. 2d Edition. $4.50

Vol. III, Part III. Vegetable Alkaloids, Non-Basic Vegetable Bitter Principles. Animal Bases, Animal Acids, Cyanogen Compounds, etc. 2d Edition, 8vo. $4.50

Vol. IV. The Proteids and Albuminous Principles. 2d Edition. $4.50

BAILEY AND CADY. Qualitative Chemical Analysis. $1.25

BARTLEY. Medical and Pharmaceutical Chemistry. A Text-Book for Medical, Dental, and Pharmaceutical Students. With Illustrations, Glossary, and Complete Index. 5th Ed. $3.00

BARTLEY. Clinical Chemistry. The Examination of Feces, Saliva, Gastric Juice, Milk, and Urine. $1.00

BLOXAM. Chemistry, Inorganic and Organic. With Experiments. 9th Ed., Revised. 281 Engravings. *Preparing.*

BUNGE. Physiologic and Pathologic Chemistry. From the Fourth German Enlarged Edition. $3.00

CALDWELL. Elements of Qualitative and Quantitative Chemical Analysis. 3d Edition, Revised. $1.00

CAMERON. **Soap and Candles.** 54 Illustrations. $2.00

CLOWES AND COLEMAN. **Quantitative Analysis.** 5th Edition. 122 Illustrations. $3.50

COBLENTZ. **Volumetric Analysis.** Illustrated. $1.25

CONGDON. **Laboratory Instructions in Chemistry.** With Numerous Tables and 56 Illustrations. $1.00

GARDNER. **The Brewer, Distiller, and Wine Manufacturer.** Illustrated. $1.50

GRAY. **Physics.** Volume I. Dynamics and Properties of Matter. 350 Illustrations. $4.50

GROVES AND THORP. **Chemical Technology.** The Application of Chemistry to the Arts and Manufactures.
Vol. I. Fuel and its Applications. 607 Illustrations and 4 Plates. Cloth, $5.00; ½ Mor., $6.50
Vol. II. Lighting. Illustrated. Cloth, $4.00; ½ Mor., $5.50
Vol. III. Gas Lighting. Cloth, $3.50; ½ Mor., $4.50
Vol. IV. Electric Lighting. Photometry. Cloth, $3.50; ½ Mor., $4.50

HEUSLER. **The Chemistry of the Terpenes.** $4.00

HOLLAND. **The Urine, the Gastric Contents, the Common Poisons, and the Milk.** Memoranda, Chemical and Microscopical, for Laboratory Use. 6th Ed. Illustrated. $1.00

LEFFMANN. **Compend of Medical Chemistry, Inorganic and Organic.** 4th Edition, Revised. .80; Interleaved, $1.00

LEFFMANN. **Analysis of Milk and Milk Products.** 2d Edition, Enlarged. Illustrated. $1.25

LEFFMANN. **Water Analysis.** For Sanitary and Technic Purposes. Illustrated. 4th Edition. $1.25

LEFFMANN. **Structural Formulæ.** Including 180 Structural and Stereo-Chemical Formulæ. 12mo. Interleaved. $1.00

LEFFMANN AND BEAM. **Select Methods in Food Analysis.** Illustrated. $2.50

MUTER. **Practical and Analytical Chemistry.** 3d American from the Ninth English Edition. Revised to meet the requirements of American Students. 56 Illustrations. $1.25

OETTEL. **Exercises in Electro-Chemistry.** Illustrated. .75

OETTEL. **Electro-Chemical Experiments.** Illustrated. .75

RICHTER. **Inorganic Chemistry.** 5th American from 10th German Edition. Authorized translation by EDGAR F. SMITH, M.A., PH.D. 89 Illustrations and a Colored Plate. $1.75

RICHTER. **Organic Chemistry.** 3d American Edition, translated from the 8th German by EDGAR F. SMITH. Illus. 2 vols.
Vol. I. Aliphatic Series. 625 pages. $3.00
Vol. II. Carbocyclic Series. 671 pages. $3.00

ROCKWOOD. **Chemical Analysis for Students of Medicine, Dentistry, and Pharmacy.** Illustrated. $1.50

SMITH. **Electro-Chemical Analysis.** 3d Ed. 39 Illus. $1.50

SMITH AND KELLER. **Experiments.** Arranged for Students in General Chemistry. 4th Edition. Illustrated. .60

SUTTON. **Volumetric Analysis.** A Systematic Handbook for the Quantitative Estimation of Chemical Substances by Measure, Applied to Liquids, Solids, and Gases. 8th Edition, Revised. 112 Illustrations. $5.00

SYMONDS. **Manual of Chemistry.** 2d Edition. $2.00

TRAUBE. **Physico-Chemical Methods.** 97 Illustrations. $1.50

THRESH. Water and Water Supplies. 3d Edition. $2.00

ULZER AND FRAENKEL. Chemical Technical Analysis. Translated by Fleck. Illustrated. $1.25

WOODY. Essentials of Chemistry and Urinalysis. 4th Edition. Illustrated. $1.50

**** Special Catalogue of Books on Chemistry free upon application.*

CHILDREN.

HATFIELD. Compend of Diseases of Children. With a Colored Plate. 3d Ed. *Just Ready.* .80; Interleaved, $1.00

IRELAND. The Mental Affections of Children. Idiocy, Imbecility, Insanity, etc. 2d Edition. $4.00

POWER. Surgical Diseases of Children and their Treatment by Modern Methods. Illustrated. $2.50

STARR. The Digestive Organs in Childhood. The Diseases of the Digestive Organs in Infancy and Childhood. 3d Edition, Rewritten and Enlarged. Illustrated. $3.00

STARR. Hygiene of the Nursery. Including the General Regimen and Feeding of Infants and Children, and the Domestic Management of the Ordinary Emergencies of Early Life, Massage, etc. 6th Edition. 25 Illustrations. $1.00

SMITH. Wasting Diseases of Children. 6th Edition. $2.00

TAYLOR AND WELLS. The Diseases of Children. 2d Edition, Revised and Enlarged. Illustrated. 8vo. $4.50

"It is well worthy the careful study of both student and practitioner, and can not fail to prove of great value to both. We do not hesitate to recommend it."—*Boston Medical and Surgical Journal.*

DIAGNOSIS.

BROWN. Medical Diagnosis. A Manual of Clinical Methods. 4th Edition. 112 Illustrations. Cloth, $2.25

DA COSTA. Clinical Hematology. A Practical Guide to Examination of Blood, with Reference to Diagnosis. 6 Colored Plates, 48 other Illustrations. Cloth, $5.00; Sheep, $6.00

DOUGLAS. Surgical Diseases of Abdomen, with Reference to Diagnosis. 20 Full-Page Plates. *Just Ready.* Cloth, $7.00; Sheep, $8.00

EMERY. Bacteriological Diagnosis. 2 Colored Plates and 32 other Illustrations. $1.50

MEMMINGER. Diagnosis by the Urine. 2d Ed. 24 Illus. $1.00

PERSHING. Diagnosis of Nervous and Mental Diseases. Illustrated. $1.25

STEELL. Physical Signs of Pulmonary Disease. $1.25

TYSON. Handbook of Physical Diagnosis. For Students and Physicians. By the Professor of Clinical Medicine in the University of Pennsylvania. Illus. 4th Ed., Improved and Enlarged. With 2 Colored and 55 other Illustrations. $1.50

DENTISTRY.

Special Catalogue of Dental Books sent free upon application.

BARRETT. Dental Surgery for General Practitioners and Students of Medicine and Dentistry. Extraction of Teeth, etc. 3d Edition. Illustrated. $1.00

BROOMELL. **Anatomy and Histology of the Human Mouth and Teeth.** Second Edition, Revised and Enlarged. 337 handsome Illustrations. Cloth, $4.50; Leather, $5.50

FILLEBROWN. **Operative Dentistry.** Illustrated. $2.25

GORGAS. **Dental Medicine. A Manual of Materia Medica and Therapeutics.** 7th Edition. Cloth, $4.00; Sheep, $5.00

GORGAS. **Questions and Answers for the Dental Student.** Embracing all the subjects in the Curriculum of the Dental Student. Octavo. $6.00

HARRIS. **Principles and Practice of Dentistry.** Including Anatomy, Physiology, Pathology, Therapeutics, Dental Surgery, and Mechanism. 13th Edition. Revised by F. J. S. GORGAS, M.D., D.D.S. 1250 Illus. Cloth, $6.00; Leather, $7.00

HARRIS. **Dictionary of Dentistry.** Including Definitions of Such Words and Phrases of the Collateral Sciences as Pertain to the Art and Practice of Dentistry. 6th Edition, Revised and Enlarged by FERDINAND J. S. GORGAS, M.D., D.D.S. Cloth, $5.00; Leather, $6.00

RICHARDSON. **Mechanical Dentistry.** 7th Edition. Thoroughly Revised and Enlarged by DR. GEO. W. WARREN. 691 Illustrations. Cloth, $5.00; Leather, $6.00

SMITH. **Dental Metallurgy.** 2d Edition. Illustrated. $2.00

TAFT. **Index of Dental Periodical Literature.** $2.00

TOMES. **Dental Anatomy.** 263 Illustrations. 5th Ed. $4.00

TOMES. **Dental Surgery.** 4th Edition. 289 Illus. $4.00

WARREN. **Compend of Dental Pathology and Dental Medicine.** With a Chapter on Emergencies. 3d Edition. Illustrated. .80; Interleaved, $1.00

WARREN. **Dental Prosthesis and Metallurgy.** 129 Illus. $1.25

WHITE. **The Mouth and Teeth.** Illustrated. .40

DICTIONARIES. CYCLOPEDIAS.

GOULD. **The Illustrated Dictionary of Medicine, Biology, and Allied Sciences.** Being an Exhaustive Lexicon of Medicine and those Sciences Collateral to it: Biology (Zoology and Botany), Chemistry, Dentistry, Pharmacology, Microscopy, etc., with many useful Tables and numerous fine Illustrations. 1633 pages. Fifth Edition.
Sheep or Half Morocco, $10.00; with Thumb Index, $11.00
Half Russia, Thumb Index, $12.00

GOULD. **The Medical Student's Dictionary.** 11th Edition. Illustrated. Including those Words and Phrases generally used in Medicine, with their Proper Pronunciation and Definition, Based on Recent Medical Literature. With Table of Eponymic Terms and Tests and Tables of the Bacilli, Micrococci, Mineral Springs, etc., of the Arteries, Muscles, Nerves, Ganglia, Plexuses, etc. Eleventh Edition. Enlarged and illustrated with a large number of Engravings. 840 pages.
Half Morocco, $2.50; with Thumb Index, $3.00
Flexible Leather, Burnished Edges, Thumb Index, 3.50

GOULD. The Pocket Pronouncing Medical Lexicon. 4th Edition. (30,000 Medical Words Pronounced and Defined.) Containing all the Words, their Definition and Pronunciation, that the Medical, Dental, or Pharmaceutical Student Generally Comes in Contact with; also Elaborate Tables of Eponymic Terms, Arteries, Muscles, Nerves, Bacilli, etc., etc., a Dose List in both English and Metric Systems, etc., Arranged in a Most Convenient Form for Reference and Memorizing. **Fourth Edition, Revised and Enlarged. 838 pages.**
Full Limp Leather, Gilt Edges, $1.00; Thumb Index, $1.25
145,000 Copies of Gould's Dictionaries have been sold.

GOULD AND PYLE. Cyclopedia of Practical Medicine and Surgery. Seventy-two Special Contributors. Illustrated. One Volume. A Concise Reference Handbook of Medicine, Surgery, Obstetrics, Materia Medica, Therapeutics, and the Various Specialties, with Particular Reference to Diagnosis and Treatment. Compiled under the Editorial Supervision of GEORGE M. GOULD, M.D., Author of "An Illustrated Dictionary of Medicine," etc.; and WALTER L. PYLE, M.D., Assistant Surgeon Wills Eye Hospital; formerly Editor "International Medical Magazine," etc., and Seventy-two Special Contributors. With many Illustrations. Large Square 8vo, to correspond with Gould's "Illustrated Dictionary."
Full Sheep or Half Mor., $10.00; with Thumb Index, $11.00
Half Russia, Thumb Index, $12.00 net.

GOULD AND PYLE. Pocket Cyclopedia of Medicine and Surgery. Based upon above book and uniform in size with "Gould's Pocket Dictionary."
Full Limp Leather, Gilt Edges, $1.00
With Thumb Index, $1.25

HARRIS. Dictionary of Dentistry. Including Definitions of Such Words and Phrases of the Collateral Sciences as Pertain to the Art and Practice of Dentistry. 6th Edition, Revised and Enlarged by FERDINAND J. S. GORGAS, M.D., D.D.S.
Cloth, $5.00; Leather, $6.00

LONGLEY. Pocket Medical Dictionary. Cloth, .75

TREVES AND LANG. German-English Medical Dictionary.
Half Calf, $3.25

DIET AND FOOD.

ALLEN. Proteids and Albuminous Principles. An analytical Study of Food Products. 2d Edition. $4.50

BURNETT. Foods and Dietaries. A Manual of Clinical Dietetics, with Diet Lists for Various Diseases, etc. 2d Ed. $1.50

DAVIS. Dietotherapy. Food in Health and Disease. With Tables of Dietaries, Relative Value of Foods, etc. *See Cohen, Physiologic Therapeutics, page* 17.

GREENISH. Microscopical Examination of Foods and Drugs. Illustrated. *Just Ready.* $3.50

HAIG. Diet and Food. Considered in Relation to Strength and Power of Endurance. 4th Edition. $1.00

LEFFMANN. Select Methods in Food Analysis. Illus. $2.50

EAR (see also Throat and Nose).

BURNETT. Hearing and How to Keep It. Illustrated. .40

HOVELL. Diseases of the Ear and Naso-Pharynx. Including Anatomy and Physiology of the Organ, together with the Treatment of the Affections of the Nose and Pharynx which Conduce to Aural Disease. 128 Illustrations. 2d Ed. $5.50

PRITCHARD. Diseases of the Ear. 4th Edition, Enlarged. Many Illustrations and Formulæ. *In Press.*

ELECTRICITY.

BIGELOW. Plain Talks on Medical Electricity and Batteries. With a Therapeutic Index and a Glossary. 43 Illustrations. 2d Edition. $1.00

HEDLEY. Therapeutic Electricity and Practical Muscle Testing. 99 Illustrations. $2.50

JACOBY. Electrotherapy. 2 volumes. Illustrated. *See Cohen, Physiologic Therapeutics, page* 17.

JONES. Medical Electricity. 3d Edition. 117 Illus. $3.00

EYE.

A Special Circular of Books on the Eye sent free upon application.

DARIER. Ocular Therapeutics. *Just Ready.* $3.00

DONDERS. The Nature and Consequences of Anomalies of Refraction. With Portrait and Illus. Half Morocco, $1.25

FICK. Diseases of the Eye and Ophthalmoscopy. Translated by A. B. HALE, M.D. 157 Illus. Cloth, $4.50; Sheep, $5.50

GOULD AND PYLE. Compend of Diseases of the Eye and Refraction. Including Treatment and Operations, and a Section on Local Therapeutics. With Formulæ, Useful Tables, a Glossary, and 111 Illus., several of which are in colors. 2d Edition, Revised. Cloth, .80; Interleaved, $1.00

GREEFF. The Microscopic Examination of the Eye. Illustrated. $1.25

HARLAN. Eyesight, and How to Care for It. Illus. .40

HARTRIDGE. On the Ophthalmoscope. 4th Edition. With 4 Colored Plates and 68 Wood-cuts. $1.50

HARTRIDGE. Refraction. 104 Illustrations and Test Types. 12th Edition, Enlarged. $1.50

HANSELL AND SWEET. Treatise on Diseases of the Eye. With many Illus. drawn by special artists, etc. *In Press.*

HANSELL AND REBER. Muscular Anomalies of the Eye. Illustrated. $1.50

HANSELL AND BELL. Clinical Ophthalmology. Colored Plate of Normal Fundus and 120 Illustrations. $1.50

HENDERSON. Notes on the Eye. 3d Ed. *Just Ready.* $1.50

JENNINGS. Manual of Ophthalmoscopy. 95 Illustrations and 1 Colored Plate. $1.50

MORTON. Refraction of the Eye. Its Diagnosis and the Correction of its Errors. 6th Edition. $1.00

OHLEMANN. Ocular Therapeutics. Authorized Translation, and Edited by DR. CHARLES A. OLIVER. $1.75

PARSONS. Elementary Ophthalmic Optics. With Diagrammatic Illustrations. $2.00

PHILLIPS. Spectacles and Eyeglasses. Their Prescription and Adjustment. 3d Edition. 52 Illustrations. $1.00

SWANZY. Diseases of the Eye and Their Treatment. 8th Edition, Revised and Enlarged. 167 Illustrations, 1 Plain Plate, and a Zephyr Test Card. *Just Ready.* $2.50

From The Medical News.

"Swanzy has succeeded in producing the most intellectually conceived and thoroughly executed résumé of the science within the limits he has assigned himself. As a 'student's handbook,' small in size and of moderate price, it can hardly be equaled."

THORINGTON. Retinoscopy. 4th Edition, Carefully Revised. Illustrated. $1.00

THORINGTON. Refraction and How to Refract. 200 Illustrations, 13 of which are colored. 2d Edition. $1.50

WALKER. Student's Aid in Ophthalmology. Colored Plate and 40 other Illustrations and a Glossary. $1.50

WORTH. Squint: Its Causes, Pathology, Treatment. $2.00

WRIGHT. Ophthalmology. 2d Edition, Revised and Enlarged. 117 Illustrations and a Glossary. $3.00

FEVERS.

GOODALL AND WASHBOURN. Fevers and Their Treatment. Illustrated. $3.00

GYNECOLOGY.

BISHOP. Uterine Fibromyomata. Their Pathology, Diagnosis, and Treatment. Illustrated. Cloth, $3.50

BYFORD (H. T.). Manual of Gynecology. 3d Edition, Revised and Enlarged. 363 Illustrations. $3.00; Sheep, $3.50

DÜHRSSEN. A Manual of Gynecological Practice. 105 Illustrations. $1.50

FULLERTON. Surgical Nursing. 3d Edition, Revised and Enlarged. 69 Illustrations. $1.00

LEWERS. Diseases of Women. 146 Illus. 5th Ed. $2.50

LEWERS. Cancer of the Uterus. *Just Ready.* $3.00

MONTGOMERY. Practical Gynecology. A Complete Systematic Text-Book. 2d Edition, Revised and Enlarged. With 570 Illus. *Just Ready.* Cloth, $5.00; Leather, $6.00

ROBERTS. Gynecological Pathology. With 127 Full-page Plates containing 151 Figures. $6.00

WELLS. Compend of Gynecology. Illustrated. 3d Edition, Revised and Enlarged. *Just Ready.* .80; Interleaved, $1.00

HEART.

THORNE. The Schott Methods of the Treatment of Chronic Heart Disease. Fourth Edition. Illustrated. $2.00

HISTOLOGY.

CUSHING. Compend of Histology. By H. H. CUSHING, M.D., Demonstrator of Histology, Jefferson Medical College, Philadelphia. Illus. *Nearly Ready.* .80; Interleaved, $1.00

LAZARUS-BARLOW. Pathological Anatomy and Histology. Illustrated. *Just Ready.* $6.50

STIRLING. Outlines of Practical Histology. 368 Illustrations. 2d Edition, Revised and Enlarged. With new Illus. $2.00

STÖHR. Histology and Microscopical Anatomy. Edited by A. SCHAPER, M.D., University of Breslau, formerly Demonstrator of Histology, Harvard Medical School. Fifth American from 10th German Edition, Revised and Enlarged. 353 Illustrations. $3.00

HYGIENE.

Special Catalogue of Books on Hygiene sent free upon application.

CANFIELD. Hygiene of the Sick-Room. A Book for Nurses and Others. Being a Brief Consideration of Asepsis, Antisepsis, Disinfection, Bacteriology, Immunity, Heating, Ventilation, etc. $1.25

CONN. Agricultural Bacteriology. Illustrated. $2.50

CONN. Bacteriology of Milk and Milk Products. Illus. $1.25

COPLIN. Practical Hygiene. A Complete American Text-Book. 138 Illustrations. New Edition. *Preparing.*

HARTSHORNE. Our Homes. Illustrated. .40

KENWOOD. Public Health Laboratory Work. 116 Illustrations and 3 Plates. $2.00

LEFFMANN. Select Methods in Food Analysis. 53 Illustrations and 4 Plates. $2.50

LEFFMANN. Examination of Water for Sanitary and Technical Purposes. 4th Edition. Illustrated. $1.25

LEFFMANN. Analysis of Milk and Milk Products. Illustrated. Second Edition. $1.25

LINCOLN. School and Industrial Hygiene. .40

McFARLAND. Prophylaxis and Personal Hygiene. Care of the Sick. *See Cohen, Physiologic Therapeutics, page* 17.

NOTTER. The Theory and Practice of Hygiene. 15 Plates and 138 other Illustrations. 8vo. 2d Edition. $7.00

PARKES AND KENWOOD. Hygiene and Public Health. 2d Edition, Enlarged. Illustrated. $3.00

ROSENAU. Disinfection and Disinfectants. Illus. $2.00

STARR. The Hygiene of the Nursery. Including the General Regimen and Feeding of Infants and Children, and the Domestic Management of the Ordinary Emergencies of Early Life, Massage, etc. 6th Edition. 25 Illustrations. $1.00

STEVENSON AND MURPHY. A Treatise on Hygiene. By Various Authors. In three octavo volumes. Illustrated. Vol. I, $6.00; Vol. II, $6.00; Vol. III, $5.00

THRESH. Water and Water Supplies. 3d Edition. $2.00

WILSON. Handbook of Hygiene and Sanitary Science. With Illustrations. 8th Edition. $3.00

WEYL. Sanitary Relations of the Coal-Tar Colors. Authorized Translation by HENRY LEFFMANN, M.D., PH.D. $1.25

LUNGS AND PLEURÆ.

KNOPF. Pulmonary Tuberculosis. Its Modern Prophylaxis and Treatment in Special Institutions and at Home. Illus. $3.00

STEELL. Physical Signs of Pulmonary Disease. Illus. $1.25

MASSAGE. PHYSICAL EXERCISE.

OSTROM. Massage and the Original Swedish Movements. Their Application to Various Diseases of the Body. A Manual for Students, Nurses, and Physicians. Fifth Edition, Enlarged. 115 Illustrations, many of which are original. $1.00

MITCHELL AND GULICK. Mechanotherapy. Exercise, Orthopedics, Massage, Ocular Corrections, etc. Illustrated. *See Cohen, Physiologic Therapeutics, below.*

TREVES. Physical Education. Its Value, Methods, etc. .75

MATERIA MEDICA AND THERAPEUTICS.

BRACKEN. Outlines of Materia Medica and Pharmacology. $2.75

COBLENTZ. The Newer Remedies. Including their Synonyms, Sources, Methods of Preparation, Tests, Solubilities, Doses, etc. 3d Edition, Enlarged and Revised. $1.00

COHEN. Physiologic Therapeutics. Methods other than Drug-Giving useful in the Prevention of Disease and in the Treatment of the Sick. Mechanotherapy, Mental Therapeutics, Suggestion, Electrotherapy, Climatology, Hydrotherapy, Pneumatotherapy, Prophylaxis, Dietetics, Organotherapy, Phototherapy, Mineral Waters, Baths, etc. 11 volumes, 8vo. Illustrated. (*Subscription.*) Cloth, $27.50; ½ Mor., $38.50
Special Descriptive Circular will be sent upon application.

GORGAS. Dental Medicine. A Manual of Materia Medica and Therapeutics. 7th Edition, Revised. $4.00

GROFF. Materia Medica for Nurses, with Questions for Self-Examination. 2d Edition, Revised and Improved. $1.25

HELLER. Essentials of Materia Medica, Pharmacy, and Prescription Writing. $1.50

HEWLETT. Serum-Therapy. *In Press.*

MAYS. Theine in the Treatment of Neuralgia. ½ bound. .50

POTTER. Handbook of Materia Medica, Pharmacy, and Therapeutics, including the Action of Medicines, Special Therapeutics, Pharmacology, etc., including over 600 Prescriptions and Formulæ. 9th Edition, Revised and Enlarged. With Thumb Index in each copy. *Just Ready.* Cloth, $5.00; Sheep, $6.00
"In conclusion we may add that Dr. Potter's Therapeutics covers a wider field than many books which bear this title. He discusses a good many drugs which are rarely employed, and therefore the book is as useful to one who wishes to look for unusual information as it is to him who wishes a handbook for ready reference in the treatment of disease as he meets it from day to day."—*Therapeutic Gazette.*

POTTER. Compend of Materia Medica, Therapeutics, and Prescription Writing, with Special Reference to the Physiological Action of Drugs. 6th Edition. .80; Interleaved, $1.00

MURRAY. Rough Notes on Remedies. 4th Edition. $1.25

SAYRE. Organic Materia Medica and Pharmacognosy. An Introduction to the Study of the Vegetable Kingdom and the Vegetable and Animal Drugs. Comprising the Botanical and Physical Characteristics, Source, Constituents, and Pharmacopeial Preparations, Insects Injurious to Drugs, and Pharmacal Botany. With sections on Histology and Microtechnique, by W. C. STEVENS. 374 Illustrations, many of which are original. 2d Edition. Cloth, $4.50

TAVERA. Medicinal Plants of the Philippines. $2.00

WHITE AND WILCOX. Materia Medica, Pharmacy, Pharmacology, and Therapeutics. 5th American Edition, Revised by REYNOLD W. WILCOX, M.A., M.D., LL.D., Professor of Clinical Medicine and Therapeutics at the New York Post-Graduate Medical School. Cloth, $3.00; Leather, $3.50

"The care with which Dr. Wilcox has performed his work is conspicuous on every page, and it is evident that no recent drug possessing any merit has escaped his eye. We believe, on the whole, this is the best book on Materia Medica and Therapeutics to place in the hands of students, and the practitioner will find it a most satisfactory work for daily use."—*The Cleveland Medical Gazette.*

MEDICAL JURISPRUDENCE AND TOXICOLOGY.

REESE. Medical Jurisprudence and Toxicology. A Text-Book for Medical and Legal Practitioners and Students. 6th Edition. Revised by HENRY LEFFMANN. M.D. Cloth, $3.00; Leather, $3.50

"To the student of medical jurisprudence and toxicology it is invaluable, as it is concise, clear, and thorough in every respect." —*The American Journal of the Medical Sciences.*

MANN. Forensic Medicine and Toxicology. Illus. $6.50

TANNER. Memoranda of Poisons. Their Antidotes and Tests. 9th Edition, by DR. HENRY LEFFMANN. *Just Ready.* .75

MICROSCOPY.

CARPENTER. The Microscope and Its Revelations. 8th Edition, Revised and Enlarged. 817 Illustrations and 23 Plates. Cloth, $8.00; Half Morocco, $9.00

GREENISH. Microscopical Examination of Foods and Drugs. Illustrated. *Just Ready.* $3.50

LEE. The Microtomist's Vade Mecum. A Handbook of Methods of Microscopical Anatomy. 887 Articles. 5th Edition, Enlarged. $4.00

OERTEL. Medical Microscopy. A Guide to Diagnosis, Elementary Laboratory Methods and Microscopic Technic. 131 Illustrations. *Just Ready.* $2.00

REEVES. Medical Microscopy, including Chapters on Bacteriology, Neoplasms, Urinary Examination, etc. Numerous Illustrations, some of which are printed in colors. $2.50

WETHERED. Medical Microscopy. A Guide to the Use of the Microscope in Practical Medicine. 100 Illustrations. $2.00

MISCELLANEOUS.

BERRY. Diseases of Thyroid Gland. Illustrated. $4.00

BUXTON. Anesthetics. Illustrated. 3d Edition. $1.50

COHEN. Organotherapy. *See Cohen, Physiologic Therapeutics, page* 17.

FRENKEL. Tabetic Ataxia. Illustrated. $3.00

GOULD. Borderland Studies. Miscellaneous Addresses and Essays. 12mo. $2.00

GOULD. Biographic Clinics. The Origin of the Ill-Health of DeQuincy, Carlyle, Darwin, Huxley, and Browning. *Just Ready.* $1.00

GREENE. Medical Examination for Life Insurance. Illus. With colored and other Engravings. 2d Edition. *In Press.*

HAIG. Causation of Disease by Uric Acid. The Pathology of High Arterial Tension, Headache, Epilepsy, Gout, Rheumatism, Diabetes, Bright's Disease, etc. 6th Edition. $3.50

HENRY. A Practical Treatise on Anemia. Half Cloth, .50

NEW SYDENHAM SOCIETY'S PUBLICATIONS. Circulars upon application. Per Annum, $8.00

OSGOOD. The Winter and Its Dangers. .40

PACKARD. Sea Air and Sea Bathing. .40

RICHARDSON. Long Life and How to Reach It. .40

SCHEUBE. Diseases of Warm Countries. Illustrated. *Just Ready.* $8.00

TISSIER. Pneumotherapy, Aerotherapy, Inhalation Methods. *See Cohen, Physiologic Therapeutics, page* 17.

TURNBULL. Artificial Anesthesia. 4th Ed. Illus. $2.50

WARDEN. The Paris Medical School. Paper, .75

WEBER AND HINSDALE. Climatology and Health Resorts. Including Mineral Springs. 2 vols. Illustrated with Colored Maps. *See Cohen, Physiologic Therapeutics, page* 17.

WILSON. The Summer and Its Diseases. .40

WINTERNITZ. Hydrotherapy, Thermotherapy, Phototherapy, Mineral Waters, Baths, etc. Illustrated. *See Cohen, Physiologic Therapeutics, page* 17.

NERVOUS DISEASES.

DERCUM. Rest, Suggestion, Mental Therapeutics. *See Cohen, Physiologic Therapeutics, page* 17.

GORDINIER. The Gross and Minute Anatomy of the Central Nervous System. With 271 original colored and other Illustrations. Cloth, $6.00; Sheep, $7.00

GOWERS. Syphilis and the Nervous System. $1.00

GOWERS. Manual of Diseases of the Nervous System. A Complete Text-Book. Revised, Enlarged, and in many parts Rewritten. With many new Illustrations. Two volumes.
Vol. I. Diseases of the Nerves and Spinal Cord. 3d Edition, Enlarged. Cloth, $4.00; Sheep, $5.00
Vol. II. Diseases of the Brain and Cranial Nerves; General and Functional Disease. 2d Ed. Cloth, $4.00; Sheep, $5.00

GOWERS. Epilepsy and Other Chronic Convulsive Diseases. 2d Edition. $3.00

HORSLEY. The Brain and Spinal Cord, the Structure and Functions of. Numerous Illustrations. $2.50

ORMEROD. Diseases of the Nervous System. 66 Wood Engravings. $1.00

PERSHING. Diagnosis of Nervous and Mental Diseases. Illustrated. $1.25

PRESTON. Hysteria and Certain Allied Conditions. Their Nature and Treatment. Illustrated. $2.00

WOOD. Brain Work and Overwork. .40

SCOVILLE. The Art of Compounding. Second Edition, Revised and Enlarged. Cloth, $2.50

STEWART. Compend of Pharmacy. Based upon "Remington's Text-Book of Pharmacy." 5th Edition, Revised in Accordance with the U. S. Pharmacopœia, 1890. Complete Tables of Metric and English Weights and Measures. .80; Interleaved, $1.00

TAVERA. Medicinal Plants of the Philippines. $2.00

UNITED STATES PHARMACOPŒIA. 7th Decennial Revision. Cloth, $2.50 (postpaid, $2.77); Sheep, $3.00 (postpaid, $3.27); Interleaved, $4.00 (postpaid, $4.50); Printed on one side of page only, unbound, $3.50 (postpaid, $3.90).

Select Tables from the U. S. P. Being Nine of the Most Important and Useful Tables, Printed on Separate Sheets. .25

POTTER. Handbook of Materia Medica, Pharmacy, and Therapeutics. 600 Prescriptions. 9th Edition. Cloth, $5.00; Sheep, $6.00

PHYSIOLOGY.

BIRCH. Practical Physiology. An Elementary Class Book. 62 Illustrations. $1.75

BRUBAKER. Text-Book of Physiology. Illus. *Nearly Ready.*

BRUBAKER. Compend of Physiology. 11th Edition, Revised and Enlarged. Illustrated. .80; Interleaved, $1.00

JONES. Outlines of Physiology. 96 Illustrations. $1.50

KIRKES. Handbook of Physiology. 17th Authorized Edition. Revised, Rearranged, and Enlarged. By PROF. W. D. HALLIBURTON, of Kings College, London. 681 Illustrations, some of which are in colors. Cloth, $3.00; Leather, $3.75

LANDOIS. A Text-Book of Human Physiology. Including Histology and Microscopical Anatomy, with Special Reference to the Requirements of Practical Medicine. 5th American, translated and edited from the last German Edition by A. P. BRUBAKER, M.D., and A. A. ESHNER, M.D. *In Press.*

STARLING. Elements of Human Physiology. 100 Illus. $1.00

STIRLING. Outlines of Practical Physiology. Including Chemical and Experimental Physiology, with Special Reference to Practical Medicine. 3d Edition. 289 Illustrations. $2.00

TYSON. Cell Doctrine. Its History and Present State. $1.50

PRACTICE.

BEALE. On Slight Ailments: their Nature and Treatment. 2d Edition, Enlarged and Illustrated. $1.25

COHEN. Physiologic Therapeutics. The Treatment of Disease by Methods other than Drug-giving. *See page* 17.

FAGGE. Practice of Medicine. 4th Edition, by P. H. PYE-SMITH, M.D. 2 volumes. Vol. I, $6.00; Vol. II, $6.00

FOWLER. Dictionary of Practical Medicine. By various writers. An Encyclopædia of Medicine. Cloth, $3.00; Half Morocco, $4.00

GOULD AND PYLE. Cyclopedia of Practical Medicine and Surgery. A Concise Reference Handbook, with particular Reference to Diagnosis and Treatment. Edited by DRS. GOULD and PYLE, Assisted by 72 Special Contributors. Illustrated, one volume. Large Square Octavo, Uniform with "Gould's Illustrated Dictionary."
Sheep or Half Mor., $10.00; with Thumb Index, $11.00
Half Russia, Thumb Index, $12.00
☞ *Complete descriptive circular free upon application.*

GOULD AND PYLE'S Pocket Cyclopedia of Medicine and Surgery. Based upon the above and Uniform with "Gould's Pocket Dictionary." Full Limp Leather, Gilt Edges, Round Corners, $1.00; with Thumb Index, $1.25.

HUGHES. Compend of the Practice of Medicine. 6th Edition, Revised and Enlarged.
Part I. Continued, Eruptive, and Periodical Fevers, Disease of the Stomach, Intestines, Peritoneum, Biliary Passages, Liver, Kidneys, etc., and General Diseases, etc.
Part II. Diseases of the Respiratory System, Circulatory System, and Nervous System; Diseases of the Blood, etc.
Price of each part, .80; Interleaved, $1.00
Physician's Edition. In one volume, including the above two parts, a Section on Skin Diseases, and an Index. 6th Revised Edition. 625 pp. Full Morocco, Gilt Edge, $2.25

TAYLOR. Practice of Medicine. 6th Edition. $4.00

TYSON. The Practice of Medicine. By JAMES TYSON, M.D. Professor of Medicine in the University of Pennsylvania. Complete Systematic Text-book, with Special Reference to Diagnosis and Treatment. 3d Edition, Enlarged and Revised. Colored Plates and 124 other Illustrations.
Cloth, $5.50; Leather, $6.50

STOMACH. INTESTINES.

FENWICK. Cancer of the Stomach. *Just Ready.* $3.00

HEMMETER. Diseases of the Stomach. Their Special Pathology, Diagnosis, and Treatment. With Sections on Anatomy, Analysis of Stomach Contents, Dietetics, Surgery of the Stomach, etc. 3d Edition, Revised. With 15 Plates and 41 other Illustrations, a number of which are in colors.
Cloth, $6.00; Sheep, $7.00

HEMMETER. Diseases of the Intestines. Their Special Pathology, Diagnosis, and Treatment. With Sections on Anatomy and Physiology, Microscopic and Chemic Examination of Intestinal Contents, Secretions, Feces and Urine, Intestinal Bacteria and Parasites, Surgery of the Intestines, Dietetics, Diseases of the Rectum, etc. With Full-page Colored Plates and many other Original Illustrations. 2 volumes. Octavo.
Price of each volume, Cloth, $5.00; Sheep, $6.00

SKIN.

BULKLEY. The Skin in Health and Disease. Illustrated. .40

CROCKER. Diseases of the Skin. Their Description, Pathology, Diagnosis, and Treatment, with Special Reference to the Skin Eruptions of Children. 3d Edition, Thoroughly Revised. With New Illus. *Just Ready.* Cloth, $5.00; Sheep, $6.00

MacLEOD. The Pathology of the Skin. Colored and other Illustrations. *Just Ready.* $5.00

SCHAMBERG. **Diseases of the Skin.** 3d Edition, Revised and Enlarged. 106 Illustrations. Being No. 16 ? Quiz-Compend? Series. *Just Ready.* Cloth, .80; Interleaved, $1.00

VAN HARLINGEN. **On Skin Diseases.** A Practical Manual of Diagnosis and Treatment, with Special Reference to Differential Diagnosis. 3d Edition, Revised and Enlarged. With Formulæ and 60 Illustrations, some of which are printed in colors. $2.75

SURGERY AND SURGICAL DISEASES
(see also Urinary Organs).

BERRY. **Diseases of the Thyroid Gland.** Illustrated. $4.00

BUTLIN. **Operative Surgery of Malignant Disease.** 2d Edition. Illustrated. Octavo. $4.50

CASPER AND RICHTER. **Functional Kidney Diagnosis.** $1.50

DAVIS. **Bandaging.** Its Principles and Practice. 163 Original Illustrations. $1.50

DEAVER. **Surgical Anatomy.** A Treatise on Human Anatomy in its Application to Medicine and Surgery. With about 500 very handsome full-page Illustrations Engraved from Original Drawings made by special Artists from Dissections prepared for the purpose. Three volumes. Royal Square Octavo. By *Subscription only. Now Ready.*
Half Morocco or Sheep, $24.00; Half Russia, $27.00

DEAVER. **Appendicitis: its Symptoms, Diagnosis, Pathology, Treatment, and Complications.** Elaborately Illustrated with Colored Plates and other Illus. 3d Edition. *Preparing.*

DOUGLAS. **Surgical Diseases of the Abdomen.** Illustrated by 20 Full-page Plates. *Just Ready.*
Cloth, $7.00; Sheep, $8.00

DULLES. **What to do First in Accidents and Poisoning.** 5th Edition. New Illustrations. $1.00

FULLERTON. **Surgical Nursing.** 3d Ed. 69 Illus. $1.00

HAMILTON. **Lectures on Tumors.** 3d Edition. $1.25

HEATH. **Minor Surgery and Bandaging.** 12th Edition, Revised and Enlarged. 195 Illus., Formulæ, Diet List, etc. $1.50

HEATH. **Clinical Lectures on Surgical Subjects.** Second Series. $2.00

HORWITZ. **Compend of Surgery and Bandaging.** Including Minor Surgery, Amputations, Fractures, Dislocations, Surgical Diseases, etc., with Differential Diagnosis and Treatment. 5th Edition, very much Enlarged and Rearranged. 167 Illus., 98 Formulæ. Cloth, .80; Interleaved, $1.00

JACOBSON. **Operations of Surgery.** 4th Ed., Enlarged. 550 Illus. Two volumes. Cloth, $10.00; Leather, $12.00

KRAY. **Medical Treatment of Gall-Stones.** $1.25

KEHR. **Gall-stone Disease.** Translated by WILLIAM WOTKYNS SHYMOUR, M.D. $2.50

MAKINS. **Surgical Experiences in South Africa.** 1899–1900. Illustrated. $4.00

MAYLARD. **Surgery of the Alimentary Canal.** 97 Illustrations. 2d Edition, Revised. $3.00

MOULLIN. Text-Book of Surgery. With Special Reference to Treatment. 3d American Edition. Revised and edited by JOHN B. HAMILTON, M.D., LL.D., Professor of the Principles of Surgery and Clinical Surgery, Rush Medical College, Chicago. 623 Illustrations, many of which are printed in colors.
Cloth, $6.00; Leather, $7.00

SMITH. Abdominal Surgery. Being a Systematic Description of all the Principal Operations. 224 Illustrations. 6th Edition. 2 volumes. Cloth, $10.00

VOSWINKEL. Surgical Nursing. Second Edition, Revised and Enlarged. 111 Illustrations. $1.00

WALSHAM. Manual of Practical Surgery. 7th Ed., Revised and Enlarged. 483 Engravings. 950 pages. $3.50

TEMPERATURE CHARTS, ETC.

GRIFFITH. Graphic Clinical Chart for Recording Temperature, Respiration, Pulse, Day of Disease, Date, Age, Sex, Occupation, Name, etc. Printed in three colors. Sample copies free. Put up in loose packages of fifty, 50 cts. Price to Hospitals, 500 copies, $4.00; 1000 copies, $7.50.

KEEN'S Clinical Charts. Seven Outline Drawings of the Body, on which may be marked the Course of Disease, Fractures, Operations, etc. Each Drawing may be had separately, twenty-five to pad, 25 cents.

THROAT AND NOSE (see also Ear).

COHEN. The Throat and Voice. Illustrated. .40

HALL. Diseases of the Nose and Throat. 2d Edition, Enlarged. Two Colored Plates and 80 Illustrations. $2.75

HOLLOPETER. Hay Fever. Its Successful Treatment. $1.00

KNIGHT. Diseases of the Throat. A Manual for Students. Illustrated. *Nearly Ready.*

KYLE (J. J.). Diseases of the Ear, Nose, and Throat. A Compend for Students. Illustrated. .80; Interleaved, $1.00

McBRIDE. Diseases of the Throat, Nose, and Ear. With Colored Illustrations from Original Drawings. 3d Ed. $7.00

POTTER. Speech and its Defects. Considered Physiologically, Pathologically, and Remedially. $1.00

URINE AND URINARY ORGANS.

ACTON. The Functions and Disorders of the Reproductive Organs in Childhood, Youth, Adult Age, and Advanced Life, Considered in their Physiological, Social, and Moral Relations. 8th Edition. $1.75

CASPER AND RICHTER. Functional Kidney Diagnosis. $1.50

HOLLAND. The Urine, the Gastric Contents, the Common Poisons, and the Milk. Memoranda, Chemical and Microscopical, for Laboratory Use. Illustrated and Interleaved. 6th Edition. $1.00

KLEEN. Diabetes and Glycosuria. $2.50

MEMMINGER. **Diagnosis by the Urine.** 2d Edition. 24 Illustrations. $1.00

MORRIS. **Renal Surgery,** with Special Reference to Stone in the Kidney and Ureter and to the Surgical Treatment of Calculous Anuria. Illustrated. $2.00

MOULLIN. **Enlargement of the Prostate.** Its Treatment and Radical Cure. 2d Edition. Illustrated. $1.75

MOULLIN. **Inflammation of the Bladder and Urinary Fever.** Octavo. $1.50

SCOTT. **The Urine.** Its Clinical and Microscopical Examination. 41 Lithographic Plates and other Illustrations. Quarto. Cloth, $5.00

TYSON. **Guide to Examination of the Urine.** For the Use of Physicians and Students. With Colored Plate and Numerous Illustrations engraved on wood. 10th Edition, Revised, Enlarged, and partly Rewritten. With New Illustrations. *Just Ready.* $1.50

VAN NUYS. **Chemical Analysis of Urine.** 39 Illus. $1.00

VENEREAL DISEASES.

GOWERS. **Syphilis and the Nervous System.** $1.00

STURGIS AND CABOT. **Student's Manual of Venereal Diseases.** 7th Revised and Enlarged Edition. 12mo. $1.25

VETERINARY.

BALLOU. **Equine Anatomy and Physiology.** 29 Graphic Illustrations. .80; Interleaved, $1.00

JACOBSON. **The Operations of Surgery.** By W. H. A. JACOBSON, F.R.C.S., Surgeon to Guy's Hospital; Consulting Surgeon Royal Hospital for Children and Women; and F. J. STEWARD, F.R.C.S., Assistant Surgeon Guy's Hospital. Fourth Edition—Revised, Enlarged, and Improved. 550 Illustrations. Two Volumes, Octavo, 1524 pages.

Cloth, $10.00; Sheep, $12.00

"The important anatomical points are clearly set forth, the conditions indicating or contraindicating operative interference are given, the details of the operations themselves are brought forward prominently, and frequently the after-treatment is considered. Herein is one of the strong points of the book."—*New York Medical Journal.*

"We know of no series of books issued by any house that so fully meets our approval as these ? Quiz-Compends?. They are well arranged, full and concise, and are really the best line of text-books that could be found for either student or practitioner." —*Southern Clinic.*

BLAKISTON'S ?QUIZ-COMPENDS?

The Best Series of Manuals for the Use of Students.

Price of each, Cloth, .80. Interleaved, for taking Notes, $1.00

These Compends are based on the most popular text-books and the lectures of prominent professors, and are kept constantly revised, so that they may thoroughly represent the present state of the subjects upon which they treat. The authors have had large experience as Quiz-Masters and attaches of colleges, and are well acquainted with the wants of students. They are arranged in the most approved form, thorough and concise, containing nearly 1000 illustrations and lithograph plates, inserted wherever they could be used to advantage. Can be used by students of *any* college. They contain information nowhere else collected in such a condensed, practical shape.

No. 1. POTTER. HUMAN ANATOMY. Seventh Edition. 138 Illustrations and 16 Plates of Nerves and Arteries.

No. 2. HUGHES. PRACTICE OF MEDICINE. Part I. Sixth Edition, Enlarged and Improved.

No. 3. HUGHES. PRACTICE OF MEDICINE. Part II. Sixth Edition, Revised and Improved.

No. 4. BRUBAKER. PHYSIOLOGY. Eleventh Edition. Illus.

No. 5. LANDIS. OBSTETRICS. Seventh Edition. 52 Illus.

No. 6. POTTER. MATERIA MEDICA, THERAPEUTICS, AND PRESCRIPTION WRITING. Sixth Revised Edition.

No. 7. WELLS. GYNECOLOGY. Third Edition. 140 Illus.

No. 8. GOULD AND PYLE. DISEASES OF THE EYE. Second Edition. Refraction, Treatment, Surgery, etc. 109 Illus.

No. 9. HORWITZ. SURGERY. Including Minor Surgery, Bandaging, Surgical Diseases, Differential Diagnosis and Treatment. Fifth Edition. With 98 Formulæ and 71 Illustrations.

No. 10. LEFFMANN. MEDICAL CHEMISTRY. Fourth Edition. Including Urinalysis, Animal Chemistry, Chemistry of Milk, Blood, Tissues, the Secretions, etc.

No. 11. STEWART. PHARMACY. Fifth Edition. Based upon Prof. Remington's Text-Book of Pharmacy.

No. 12. BALLOU. EQUINE ANATOMY AND PHYSIOLOGY. 29 graphic Illustrations.

No. 13. WARREN. DENTAL PATHOLOGY AND DENTAL MEDICINE. Third Edition, Illustrated.

No. 14. HATFIELD. DISEASES OF CHILDREN. 3d Edition.

No. 15. THAYER. GENERAL PATHOLOGY. 78 Illus.

No. 16. SCHAMBERG. DISEASES OF THE SKIN. Third Edition, Revised and Enlarged. 106 Illustrations.

No. 17. CUSHING. HISTOLOGY. Illustrated. *In Press.*

No. 18. THAYER. SPECIAL PATHOLOGY. 34 Illustrations.

No. 19. KYLE. DISEASES OF THE EAR, NOSE, AND THROAT. Illustrated.

DA COSTA

Clinical Hematology

A Practical Guide to the Examination of the Blood by Clinical Methods. With Reference to the Diagnosis of Disease. With Colored Illustrations. Cloth, $5.00

*** A new, thorough, systematic, and comprehensive work, its purpose being, first, to show how to examine the blood, and second, how to diagnose from such examination diseases of the blood itself and general diseases. The author's aim has been to cover not alone the field of original research, but to supply a book for the student, the hospital physician and the general practitioner. It will be found wanting in none of these respects.

OERTEL

Medical Microscopy

JUST READY

A GUIDE TO DIAGNOSIS, ELEMENTARY LABORATORY METHODS, AND MICROSCOPIC TECHNIC

By T. E. Oertel, M.D.,

Professor of Pathology and Clinical Microscopy, Medical Department, University of Georgia.

WITH 131 ILLUSTRATIONS. 12mo. Cloth, $2.00

The Pocket Cyclopedia of Medicine and Surgery

Full Limp Leather, Round Corners, Gilt Edges, $1.00
With Thumb Index, $1.25

Uniform with "Gould's Pocket Dictionary"

A concise practical volume of nearly 600 pages, containing a vast amount of information on all medical subjects, including Diagnosis and Treatment of Disease, with Formulas and Prescriptions, Emergencies, Poisons, Drugs and Their Uses, Nursing, Surgical Procedures, Dose List in both English and Metric Systems, etc.

By Drs. Gould and Pyle

Based upon their large "Cyclopedia of Medicine and Surgery."

*** This is a new book which will prove of the greatest value to students. It is to the broad field of general medical information what "Gould's Pocket Dictionary" is to the more special one of definition and pronunciation of words. The articles are concise but thorough, and arranged in shape for quick reference. In no other book can be found so much exact detailed knowledge so conveniently classified, so evenly distributed, so methodically grouped. It is *Multum in Parvo.* **Sample Pages Free.**

A NEW EDITION

CROCKER ON THE SKIN

The Diseases of the Skin. Their Description, Pathology, Diagnosis, and Treatment, with Special Reference to the Skin Eruptions of Children. By H. RADCLIFFE CROCKER, M.D., Physician to the Department of Skin Diseases, University College Hospital, London. With new Illustrations.

Third Edition, Rewritten and Enlarged

OCTAVO. JUST READY; CLOTH, $5.00

*** This new edition will easily hold the high position given the previous printings. The author is a member of American, English, French, German, and Italian Dermatological Societies, and a recognized authority the world over.

STURGIS—MANUAL OF VENEREAL DISEASES

By F. R. STURGIS, M.D., Sometime Clinical Professor of Venereal Diseases in the Medical Department of the University of the City of New York. Seventh Edition, Revised and in Part Rewritten by the Author and FOLLEN CABOT, M.D., Instructor in Genito-Urinary and Venereal Diseases in the Cornell University Medical College. 12mo. 216 pages. Cloth, $1.25

*** This manual was originally written for students' use, and is as concise and as practical as possible. It presents a careful, condensed description of the commoner forms of venereal diseases which occur in the practice of the general physician, together with the most approved remedies.

A Companion Volume to Gould's Pocket Dictionary

A POCKET CYCLOPEDIA
OF
MEDICINE and SURGERY

EDITED BY

GEORGE M. GOULD, A.M., M.D.

Author of "Gould's Medical Dictionaries;" Editor of "American Medicine"

AND

WALTER L. PYLE, A.M., M.D.

Assistant Surgeon Wills Eye Hospital, Philadelphia; formerly Editor "International Medical Magazine," etc.

BEING BASED UPON GOULD AND PYLE'S LARGE "CYCLOPEDIA OF PRACTICAL MEDICINE AND SURGERY"

Uniform with Gould's Pocket Dictionary. 64mo. Flexible Leather, Gilt Edges, Round Corners, net $1.00; with Thumb Index, $1.25

THIS book bears to Gould and Pyle's large "Cyclopedia of Medicine and Surgery" a relation similar to that which the Pocket Dictionary bears to Gould's complete "Illustrated Dictionary." As the Dictionary gives the derivation, pronunciation, and definition of medical **words**, the Cyclopedia is designed to furnish general information concerning medical **subjects**. Every subject, concerning which the student may desire a brief and thorough description, supplementing the mention which may be given in lectures or a general text-book, is taken up and treated thoroughly and concisely. To those desiring concise authoritative information on medical or surgical themes or who wish to look up any new term or matter of recent discovery and use, the book will prove invaluable. It includes articles on Emergencies, Hygiene, Poisons, Nursing, etc.; describes Drugs and their Uses; gives Treatment of Diseases; explains Surgical Operations; contains many Prescriptions and Formulæ, Tables of Differential Diagnosis, Dose Table in both English and Metric Systems, etc.

P. BLAKISTON'S SON & CO., Publishers and Booksellers
1012 WALNUT STREET, PHILADELPHIA

LANE MEDICAL LIBRARY

This book should be returned on or before the date last stamped below.

FOR MEDICAL STUDENTS.

OERTEL.
Element
OERTEL
Clinical
131 Illu

EDGAR.
EDGAR,
Departn
rician to
largely f
Just Re

STURGIS.
Edition
Venerea
City of
CABOT,
Cornell

COPLIN.
Illustra
and Me
Professo
Third I
which a

MONTGO
OGY.
fessor of
cologist t
many of

WALSHA
and Pra
Lecturer
Illustrati

HOLDEN'
311 Illu
Anatomy
VOL. I.

VOL. II.

WHITE AND WILCOX. MATERIA MEDICA, PHARMACY, PHARMACOLOGY, AND THERAPEUTICS. Fifth Edition. By WILLIAM HALE WHITE, M.D., F.R.C.P., etc., Physician to, and Lecturer on Materia Medica, Guy's Hospital, London, etc. Fifth American Edition. **Revised in accordance with the U. S. P.** by REYNOLD W. WILCOX, M.A., M.D., Professor of Clinical Medicine at the New York Post-Graduate Medical School and Hospital. Cloth, *net*, $3.00

BLAKISTON'S SON & CO., Publishers and Booksellers,
***1012* WALNUT STREET, PHILADELPHIA.**

FOR MEDICAL STUDENTS.

BUNGE. PHYSIOLOGIC AND PATHOLOGIC CHEMISTRY. By DR. C. BUNGE, Professor at Basel. Authorized Translation from the Fourth German Edition. Edited by E. A. [illegible]RLING, M.D., F.R.S., Professor of Physiology in Universit[illegible]on. Octavo. Cloth, $3.00

KIRKES' PHY[illegible] (*The Authorized* [illegible] Enlarged. By W. [illegible]y, King's College, [illegible]rinted in Colors. Cl[illegible] $3.00

[illegible]UDING THE [illegible]TOUR, Professor [illegible]ation. Edited, [illegible] Anatomy, Uni- [illegible]rvard Medical [illegible] Edition. En- [illegible]th, *net*, $3.00

T[illegible] [illegible] HERBERT U. [illegible] Medical De- [illegible] Enlarged. [illegible] *net*, $1.75

TY[illegible] [illegible] E. Tep[illegible]

REE[illegible] [illegible]

SWA[illegible] [illegible]

BYFORD[illegible] [illegible]

BARTLEY[illegible] [illegible]

T74 Schamberg, J.F.
S29 A compend of diseases
1903 of the skin.
101124

NAME	DATE DUE